



Azadirachta indica A. Juss induced changes in spermatogenic pattern in albino rats

R. H. Aladakatti, R. Nazeer Ahamed*

Post-Graduate Department of Studies and Research in Zoology, Karnatak University, Dharwad-580003, India.

Abstract

Objective: The leaves of *Azadirachta indica* A. Juss was tested to find the antispermatogenicity in seminiferous epithelium of rats. **Materials and methods:** Male albino rats were administered orally (by gavage), 100 mg/ body weight *Azadirachta indica* leaf powder with or without testosterone (IM). Suitable controls were maintained. **Results:** Damaged seminiferous tubules and abundance of vacuoles of varying size were observed in *Azadirachta indica* treated rats. The germ cells showed overall decrease in cytoplasmic ground substance. Leydig cells exhibited characteristics of degeneration with condensed nuclei. Total count of spermatocytes, spermatids and Leydig cells were reduced. The cell and nuclear diameter of spermatogonia, spermatocytes, spermatids and Leydig cells were also reduced. **Conclusion:** From the results obtained, it can be observed that *Azadirachta indica* effects on the testis are possibly due to gonadotrophic hormone deficiency, caused directly or indirectly. The probable mode of antiandrogenic and antispermatogenic actions of the medicinal plant is discussed.

Key words: *Azadirachta indica*, Testosterone, Germ cells, Leydig cells and Albino rats

1. Introduction

Male reproductive physiology is fairly simple, involving two basic mechanisms, namely, spermatogenesis and androgenesis. Interference, particularly in the spermatogenic process would be theoretically simpler than with the female reproductive system. Hence, there is pertinent need to emphasize male fertility regulation, in the control of birth [1]. Among the major approaches towards male fertility control, the phytochemical approach has yielded partial success, but it is believed that the future of male

contraceptive technology lies in the phytochemical approach. India is gifted with an abundance of natural remedies in the form of herbs, shrubs and mineral elements. Tribal people are known to use decoctions prepared from plant materials both orally and locally in an attempt to prevent conception.

Azadirachta indica A. Juss (Syn: *Melia azadirachta*), belonging to the family Meliaceae, commonly known as neem, is an important medicinal plant, cultivated throughout India and

* Corresponding author

E-mail: drnazeerahmed2003@yahoo.co.in

Burma [2,3]. This plant is extensively used as astringent, antiperiodic, antispasmodic, antiprotozoal; for cure of leprosy and bronchitis; for healing ulcers in urinary passages; for chronic fever and so on [2-6].

Additionally, leaves of *A. indica* (a) possess emmenagogue, antiimplantational, spermicidal, antifertility, and antispermatic activities [7-11]; (b) cause decrease in the weight of accessory glands, such as seminal vesicle and ventral prostate; (c) cause decrease in serum levels of testosterone in rats. Several of these effects appear reversible [12-14]. The morphological changes in the head of rat spermatozoa, sperm parameters and ultrastructural changes in testes, induced by *A. indica* leaves have been reported [15-17].

Recently, it has been shown that this leaf powder adversely affects on sperm parameters, fructose levels in vas deferens fluid; structural changes in prostate gland and vas deferens and cauda epididymal epithelial cell types in rats [18-20]. In the light of these observations an attempt has been made to delineate the histological changes within the seminiferous epithelium and it seemed to be of interest to explore as to how this plant affects the spermatogenesis process.

2. Materials and methods

2.1 Plant Material

The leaves of *Azadirachta indica* were collected locally and dried in shade. The dried leaves were coarsely powdered and the powder was quantitatively suspended in distilled water for oral administration (by gavage) to albino rats.

2.2 Animals

Three months old adult male albino rats (Wistar strain) weighing 170-200 g were obtained from the rat colony maintained in the department. They were housed under well ventilated light-dark schedule with free access to food and water.

2.3 Experimental procedure

The animals were divided into four groups, each consisting of 10 animals.

Group I: The animals were given 1 ml of distilled water/rat/day for a period of 48 days and served as controls.

Group II: The animals were given 500 mg/kg body weight of leaf powder/day for a period of 48 days.

Group III: The animals were given a dose of 0.25 mg/ kg body weight of testosterone (im)/ day for a period of 48 days.

Groups IV: The animals were given 500 mg of leaf powder (by gavage) and 0.25 mg of testosterone (im)/ kg body weight/day for a period of 48 days.

Five animals from each group were used for fertility test.

Twenty-four hours after the last dose, the control and treated animals were given mild ether anaesthesia.

2.4 Histology and histometry

After vascular perfusion, testes were removed and fixed in gluteraldehyde and prepared for transmission electron microscopic studies, post-fixed in 1% osmium tetroxide, embedded in araldite and semi-thin sections (100-200 µm) were obtained in a Leica LKB bromma Ultramicrotome. Such sections were immersed in 4% iron alum for half an hour to remove araldite (because, with araldite the sections do not take stain with haematoxylin). For histometrical studies, a calibrated ocular micrometer (Erma, Japan) was used. From each testis, 20 sections randomly were used in each group, to record the data.

2.5 Fertility test

To assess the fertility rate with reference to the number of implantations, the female rats of

Table 1.

Effect of treatment of *A. indica* leaf powder, testosterone and leaf powder + testosterone on total count of seminiferous tubules, germ cells, Leydig cells and Sertoli cells of the testis of albino rats (Values are expressed in SEM of 5 animals).

Group	Number of seminiferous tubules in microscopic field (10X)	Spermato-gonia	Spermato-cytes	Spermatids	Leydig cells	Sertoli cells
I Control	16.70 ± 0.16	113.9 ± 2.38	627.65 ± 2.92	979.45 ± 3.20	39.90 ± 0.42	23.4 ± 0.46
II <i>A. indica</i> leaf powder	23.90 ± 0.35***	89.55 ± 1.76	112.95 ± 2.21***	89.85 ± 3.57***	21.8 ± 0.28***	19.95 ± 0.55***
III Testosterone	16.50 ± 0.15	123.85 ± 1.26	655.00 ± 2.21	1160.5 ± 3.18***	41.25 ± 0.51	22.7 ± 0.45
IV <i>A. indica</i> leaf powder + Testosterone	16.80 ± 0.16	111.35 ± 1.42	618.25 ± 3.20	964.25 ± 3.82	36.70 ± 0.46***	21.65 ± 0.62

***p≤0.001

proven fertility, exhibiting regular estrous cycles and those in early proestrous and estrous stage were separately housed with the males of groups I, II, III and IV and left overnight. The appearance of spermatozoa in the vaginal smear, next morning confirmed the mating and was considered as day 1 of pregnancy. After 8 days, the female animals were laparotomized and the numbers of implantations were recorded. The number of pups and their weights on day 1 and after one week were recorded.

2.6 Statistical analysis

The data are recorded as mean ± SEM. Statistical comparison of data was done using one way Anova test followed by Dunnett test and probability level of p≤0.001 was considered as significant.

3. Results

The testis of control rats exhibited different stages in seminiferous elements comprising of germ cells, Sertoli cells and interstitial cells which are normal in their appearance. Stage VII of the

spermatogenic cycle of the normal rat testis exhibits spermatogonia, and preleptotene and pachytene spermatocytes. Round spermatids showed characteristically polarized nuclei, elongated spermatids and Sertoli cells (Fig. 1).

The acrosome of stage VII or VIII spermatids face the general direction of the lumen (⇒) and some face the basal lamina, VII stage spermatids showing normal structure and elongated spermatids (step 19 or presumably spermatozoa are seen with Sertoli cells residual bodies were also apparent (Fig. 5). Leydig cells (LC) within the testis exhibited normal morphology, distribution within intertubular tissue and the empty appearance of the tissue represents the interstitial fluid-filled lymphatic sinusoid (Fig. 10).

The animals fed with *Azadirachta indica* leaf powder showed different stages of damaged seminiferous tubules that exhibited abundant vacuoles, including intraepithelial vacuoles, of varying size. Appearance of many vacuoles start from one cell layer away from the basal lamina

Table 2.

Effect of treatment of *A. indica* leaf powder, testosterone and leaf powder + testosterone on diameter of seminiferous tubules, germ cells of the testis of albino rats (Values are expressed in SEM of 5 animals).

Group	10 X	100 X		
	Seminiferous tubules	Spermatogonia	Spermatocytes	Spermatids
I Control	256.90 ± 2.11	11.35 ± 0.12	9.75 ± 0.11	9.10 ± 0.11
II <i>A. indica</i> leaf powder	179.20 ± 1.93***	6.20 ± 0.09***	5.65 ± 0.08 ***	5.25 ± 0.09***
III Testosterone	259.15 ± 2.14	11.60 ± 0.10***	9.90 ± 0.11***	9.50 ± 0.10***
IV <i>A. indica</i> leaf powder + Testosterone	248.50 ± 3.19	10.90 ± 0.11***	9.45 ± 0.10***	9.00 ± 0.10***

p<0.001 ***

Table 3.

Effect of treatment of *A. indica* leaf powder, testosterone and leaf powder + testosterone on nuclear diameter (µm) of the germ cells of the testis of albino rats (Values are expressed in SEM of 5 animals).

Group	100 X			
	Spermatogonia	Spermatocytes	Spermatids	Leydig cells
I Control	10.45 ± 0.10	8.40 ± 0.10	7.65 ± 0.10	8.25 ± 0.09
II <i>A. indica</i> leaf powder	5.35 ± 0.08***	4.20 ± 0.08 ***	3.80 ± 0.08***	4.15 ± 0.07***
III Testosterone	10.70 ± 0.10***	8.70 ± 0.12***	8.10 ± 0.09***	8.60 ± 0.11***
IV <i>A. indica</i> leaf powder + Testosterone	10.25 ± 0.09***	8.25 ± 0.10***	7.60 ± 0.10	8.05 ± 0.08***

p<0.001 ***

of the tubules and exhibit exfoliation. There was lack of round and elongated spermatids and pachytene spermatocytes underwent degeneration (Hallow arrow heads, Fig. 2 and 6), at the base of the layer, the Sertoli cell nuclei (Sn) appear normal (Fig. 2).

The germ cells showed overall decrease in the cytoplasmic ground substance, degenerating spermatocytes showed the characteristic of vacuolization (V) and a few of them had disrupted nuclei (Figs. 2, 6 and 7). Leydig cells exhibited clearly, characteristics of degeneration as a result of phagocytosis by macrophages and their nuclei were condensed or had irregular shape, which is evidence of complete degeneration of the Leydig cell (Fig. 11). The

number of seminiferous tubules was increased significantly (p<0.001) per microscopic field (Table 1) and the diameter of the tubule was reduced significantly (p<0.001, Table 2).

Total count of spermatocytes, spermatids and Leydig cells were significantly reduced. Where as spermatogonia were slightly decreased (p<0.01, Table 1). The diameter of the spermatogonia, spermatocytes and spermatids were significantly reduced (p<0.001, Table 2). The nuclear diameter of the spermatogonia, spermatocytes, spermatids and Leydig cells was reduced significantly (p<0.001, Table 3).

The animals treated with testosterone showed hyperactive germ cells and Leydig cells. Each

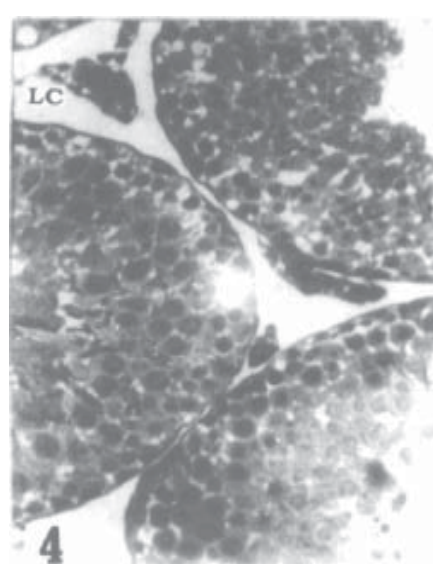
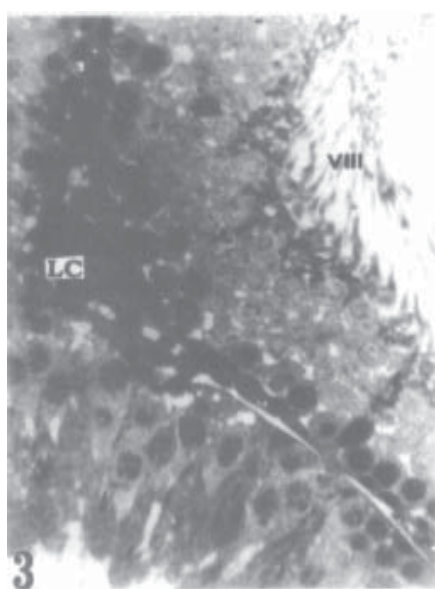
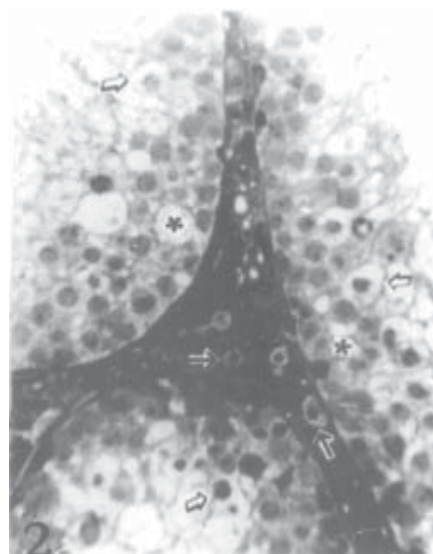
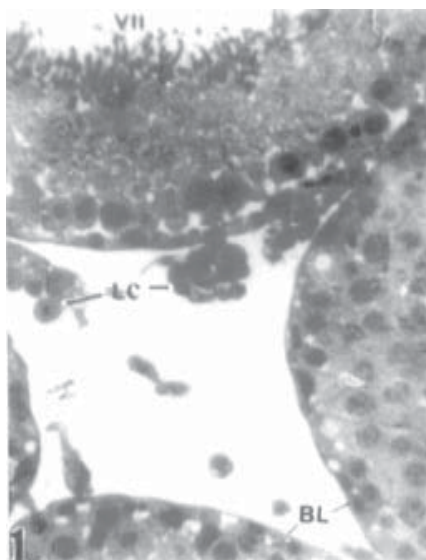


Fig. 1: Section of the seminiferous tubules of control rat exhibiting stages with normal features consisting of germ cells, Sertoli cells and interstitial elements. Note: Stage VII seminiferous tubule showing germ cells, Sertoli cells (S) and Leydig cells (LC) with normal morphology. The intertubular space contains the interstitial fluid-filled lymphatic sinusoids (arrow heads) X 400.

Fig. 2: A damaged seminiferous tubule from *Azadirachta indica* leaf powder treated rat showing intra-epithelial vacuoles of varying size, exfoliation and the germ cells are depleted. Note: Degenerating spermatocytes exhibited the characteristic of vacuolization with disrupted nuclei (hallow arrow heads) The vacuoles are positioned or start one cell layer away from the

basal lamina (BL) towards the lumen of the tubules (*) The Leydig cells exhibit the characteristic of degeneration (arrows) X 400.

Fig. 3: Section of the seminiferous tubules of testosterone treated rat. Note: VII or VIII stage of the seminiferous tubule shows active spermatogenesis and Leydig cells (LC) are seen compactly arranged in the tubule X 400.

Fig. 4: Section of the seminiferous tubules of *Azadirachta indica* leaf powder and testosterone treated rat. Spermatogenesis appears normal. Tubules contained many more round spermatids, the majority of which are correctly aligned and few elongated sperms are seen. Leydig cells (LC) show normal rounded nuclei X 400.

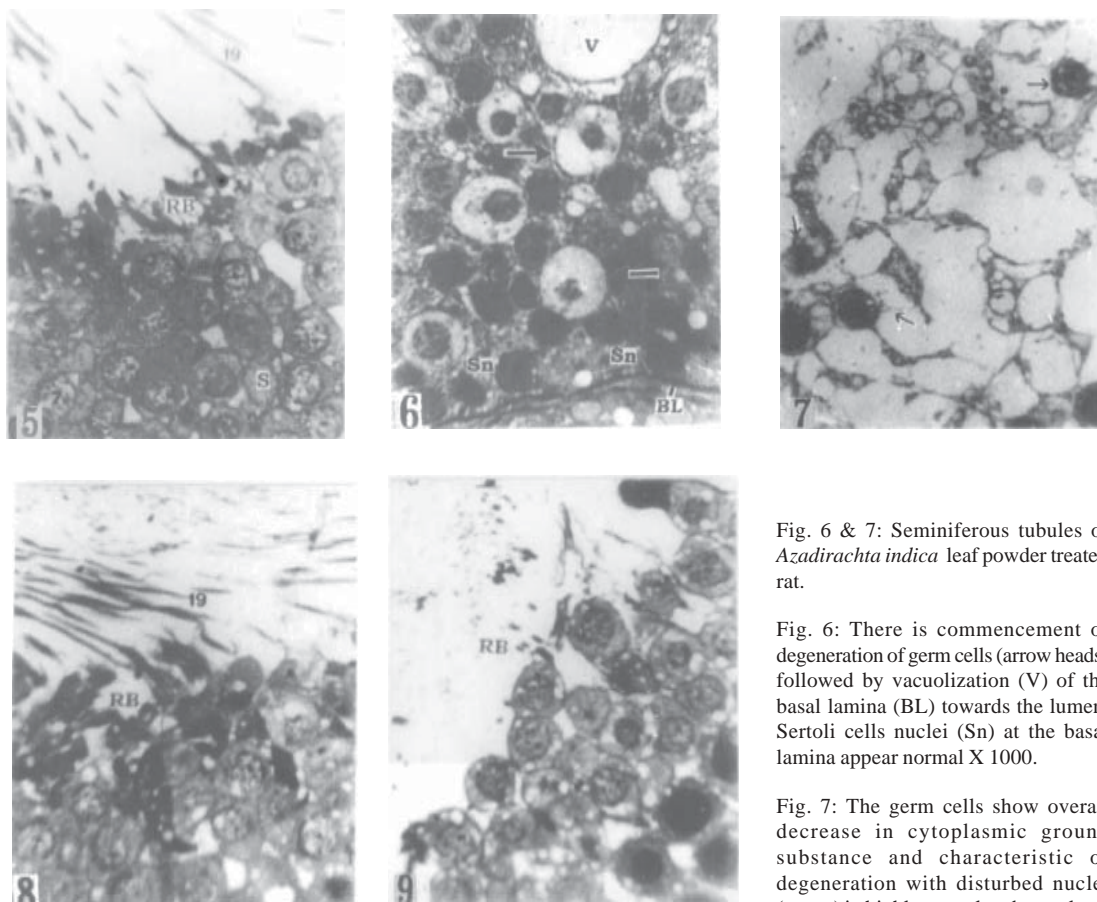


Fig. 5-9: Sections of the part of seminiferous tubules at higher magnification.

Fig. 5: Seminiferous tubules of control rat stage VII or VIII of the seminiferous tubule, the acrosome of spermatids face the general direction of the lumen and towards the basal lamina. Step 7 spermatids exhibit normal appearance and elongated spermatids (step 19) or presumably spermatozoa and residual bodies (RB), are also apparent. X 800.

Fig. 8: Seminiferous tubules of the testosterone treated rat. Stage VII of the tubule exhibiting hyperactivity of spermatogenesis X 800.

Fig. 9: Seminiferous tubules of *Azadirachta indica* leaf powder and testosterone treated rat. All the components and features are similar to those of control rat seminiferous tubules X 1000.

Fig. 6 & 7: Seminiferous tubules of *Azadirachta indica* leaf powder treated rat.

Fig. 6: There is commencement of degeneration of germ cells (arrow heads) followed by vacuolization (V) of the basal lamina (BL) towards the lumen. Sertoli cells nuclei (Sn) at the basal lamina appear normal X 1000.

Fig. 7: The germ cells show overall decrease in cytoplasmic ground substance and characteristic of degeneration with disturbed nuclei (arrow) in highly vacuolated cytoplasm X 800.

seminiferous tubule revealed a typical adult organization of the spermatogenic cells and Sertoli cells, with tubular wall and basement membrane. VII or VIII stages of seminiferous tubules showed active spermatogenesis and the basement membrane contained well developed spermatogonia, Sertoli cell nucleus, preleptotene and pachytene spermatocytes, round spermatids, elongated spermatids and

spermatozoa, soon to be released into the tubular lumen (Figs. 3, 8 & 12).

The number of seminiferous tubules per microscopic field and the diameter of the seminiferous tubules did not show variation. The total count of the spermatogonia, spermatocytes, Sertoli cells and Leydig cells did not much show variation from the control rats.

Table 4.

Effect of treatment of *A. indica* leaf powder, testosterone and leaf powder + testosterone on the implantations, number of pups and their body weight of female rats, mated with treated male rats (Values are expressed in SEM of 5 animals).

Group	Number of implantations	Number of Pups	Body weight (gm)	
			1 day	1 Week
I control	8.20 \pm 0.36	8.00 \pm 0.32	5.73 \pm 0.07	9.66 \pm 0.04
II <i>A. indica</i> leaf powder	—	—	—	—
III Testosterone	8.00 \pm 0.32	7.80 \pm 0.26	5.74 \pm 0.03	9.66 \pm 0.04
IV <i>A. indica</i> leaf powder + Testosterone	8.20 \pm 0.33	7.80 \pm 0.30	5.72 \pm 0.03	9.67 \pm 0.04

However, spermatids were increased significantly ($p < 0.001$, Table 1). The diameter of spermatogonia, spermatocytes and spermatids were increased significantly ($p < 0.001$, Table 2). Nuclear diameter, spermatogonia, spermatocytes, spermatids and Leydig cells were increased significantly ($p < 0.001$, Table 3).

Spermatogenesis appears qualitatively normal in the animals treated with the combination of leaf powder and testosterone. Tubules contained many round spermatids with polarized nuclei, the majority of which were correctly aligned. Few elongated spermatids and residual bodies were also apparent. Sertoli cells are normal (Fig. 4 & 9) and Leydig cells appear normal with rounded nuclei (Fig. 13).

Histological examination of the testis revealed that total count of Leydig cell, diameter germ cells were increased significantly ($p < 0.001$, Tables.1 & 2). Also nuclear diameter of spermatogonia, spermatocytes and Leydig cells were shown significant ($p < 0.001$, Table 3). And rests of the parameters were similar to the control animals.

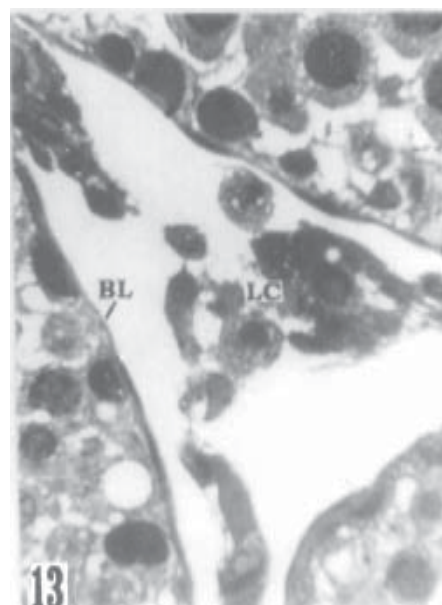
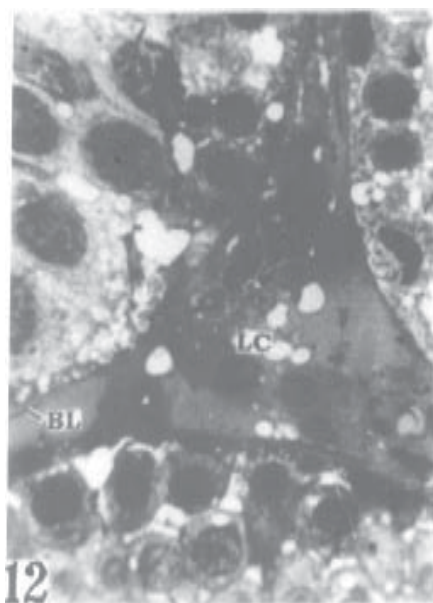
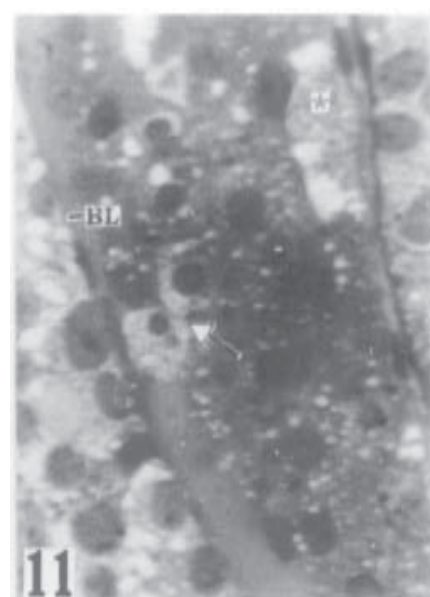
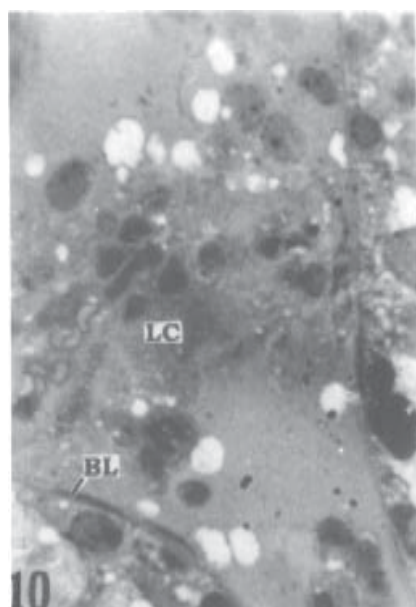
The female rats mated with control male rats, showed the following observations. The number of implantations were 8.20 ± 0.36 on day 8 of pregnancy. Number of pups obtained was 8.00

± 0.32 and the body weight of one-day old pup was 5.73 ± 0.07 gm and those of one week old was 9.66 ± 0.04 gm. No implantations were observed in the female rats, mated with leaf powder treated male rats.

In the female rats mated with testosterone treated male rats, the number of implantations were 8.00 ± 0.32 , the number of pups was 7.80 ± 0.26 and the body weight of one day old pups was 5.74 ± 0.03 gm and one week old pups was 9.66 ± 0.04 gm, respectively. Female rats mated with leaf powder and testosterone treated male rats showed the number of implantations was 8.20 ± 0.33 , the number of pups was 7.80 ± 0.30 and the body weight of the pups on day one and one week of age were 5.72 ± 0.03 gm and 9.67 ± 0.04 gm, respectively (Table 4).

4. Discussion

Androgen is essential for most of the stages of spermatogenesis, meiosis in particular. Sperm production cannot proceed optimally to completion, without a continuous androgen supply. Interference of testosterone production leads to atrophy of the organ and impairment of spermatogenesis [21]. It has been reported that reducing testicular weight and maturational arrest of the primary spermatocyte manifest androgen deficiency [22].



Figs. 10 -12: Interstitium of rat testis (X 800).

Fig.10: Leydig cells (LC) exhibiting normal morphology and distribution within intertubular tissue and Leydig cells with empty appearance of the tissue represents the interstitial fluid filled lymphatic sinusoids (arrow heads).

Fig.11: Interstitium of *Azadirachta indica* leaf powder treated rat. The degenerating Leydig cell with condensed nuclei (arrow head) and complete degeneration of Leydig cells (*) is evident.

Fig.12: Interstitium of testosterone treated rat, exhibiting normal appearance with interstitial fluid lymphatic sinusoid, as in controls.

Fig.13: Interstitium of *Azadirachta indica* leaf powder and testosterone treated rat. Leydig cells (LC) shows normal features as in controls.

In the present study the antispermatogenic activity of *Azadirachta indica* is reflected in the arrest of spermatogenesis. The morphometric analysis confirms the adverse effect on the spermatocytes, spermatids and Leydig cells. Similar observations related to the unique nature of changes in the seminiferous tubule treated with different parts of plant extracts have been assayed so far, in the perspective of male antifertility.

To quote a few, *Ocimum sanctum* [23], *Aristolochia indica* [24], *Allium sativum* [25], *Malviscus conzatti* [26, 27], *Andrographis paniculata* [28], *Vinca rosea* [29], vincristine, an alkaloid of *Vinca rosea* [30, 31], *Carica papaya* [32], *Euphorbia nerrifolia* [33], *Momordica charantia* [34] and *Cocculus pendulus* [35] have been studied in this category.

Stage VII or VIII of the spermatogenic cycle is known to be particularly sensitive to hormone deprivation/withdrawal [36-39]. Consistent with this view, is the observation of some degenerating pachytene spermatocytes and round spermatids in the present study.

The development of vacuoles occurred chiefly in stage VII or VIII tubules at or above the position of the Sertoli cell nuclei and in association with the appearance of cavities, around the primary spermatocytes and towards the lumen. They are similar to the vacuoles described in the degeneration of germ cells in hypophysectomized and hormone treated rats [36]; in short-term hypophysectomized rats [40] and in testosterone withdrawal of rat [38]. Also in plant seed extract [41] and indinopyridine CDB-4022 [42] treated rats.

It is not known if vacuole formation occurs as a direct consequence of germ cell necrosis or is a

non specific response of the Sertoli cells to androgen deprivation [38]. The concurrent appearance of numerous smaller vacuoles represent a morphological indicator of Sertoli cell damage. Support for this idea has been provided by recent studies [38, 40].

The process of spermatogenesis is androgen dependent [43]. In the present study, significantly reduced number of Leydig cells, nuclear diameter and degeneration of these cells reflect depletion of androgen levels. Decreased number of germinal cells i.e., spermatocytes, spermatids and their nuclear diameters support the observations/ hypothesis/ view, since these stages are completely androgen dependent [44].

Similar observations have been made in recent studies of *Colebrookia oppositifolia*, leaf extract [45], *Sarcostemma acidum*, stem extract [46], ethanolic extract of *Amalakyadi churna* [47], seed extracts of *Crotalaria juncea* [48] and methanolic pod extract of *Albizia lebbeck* [49] in male rat and mice.

Thus in the present study, the histoarchitecture and morphometric analysis revealed the adverse effect of *Azadirachta indica* leaves on the rat testis including tubular atrophy, along with the abnormal histological appearance of the seminiferous epithelium and the Leydig cells.

This may be due to curtailing of androgen supply within the testis or it may be a direct effect of this plant extract on the tissue and it appears that *Azadirachta indica* effects on the testis are probably due to direct or indirect gonadotrophic hormone deficiency. Further studies are required to identify the exact sites and reasons for vacuole formation in spermatogenesis.

References

1. Rajalakshmi M. (1993) *Current R & D Highlights*, 1-5.
2. Nadkarni AK. (1954) *Nadkarni's Indian Material Medica*. Vols. I & II, 3rd edn. Popular Book Depot, Bombay.
3. Iyengar MA. (1976) *Bibliography of Indian medicinal plants* (1950-1975). College of pharmacy, Kasturba Medical College, Manipal.
4. Chopra RW, Nayar SD, Chopra IC. (1986) *Indian Medicinal Plants*, CSIR: New Delhi.
5. Bentley RB, Trimen H. (1983) *Medicinal Plants*, Vol. III. International Book Distributors: Dehradun.
6. Bhakuni DS, Goel AK, Sudha J, Mehrotra BN, Srimal RC. (1990) *Indian J. Exp. Biol.* 28; 619-637.
7. Sinha KC, Riar SS, Tiwary RS, Dhawan AK, Bardhan J, Thomas P, Kain AK, Jain RK. (1984 b) *Indian J. Med. Res.* 79; 131-136.
8. Sinha KC, Riar SS, Bardhan J, Thomas P, Kain AK, Jain RK. (1984a) *J. Med. Res.* 80; 708-710.
9. Chowdhary CN, Singh JN, Verma SK, Singh BP. (1990) *Indian J. Exp. Biol.* 28; 714-716.
10. Shaikh PD. (1990) M. Phil. Dissertation, Karnatak University, Dharwad, India.
11. Shaikh PD, Manivannan B, Pathan KM, Kasturi M, Nazeer Ahamed R. (1993) *Curr Sci.* 64; 688-689.
12. Kasturi M. (1993) Ph.D. Thesis. Karnatak University, Dharwad, India.
13. Kasturi M, Nazeer Ahamed R, Pathan KM, Shaikh PD, Manivannan B. (1996) *Indian J. Physiol. Pharmacol.* 41; 234-240.
14. Anjali RJ, Nazeer Ahamed R, Pathan KM, Manivannan B. (1996) *Ind. J. Exp. Biol.* 34; 1091-1094.
15. Aladakatti RH, Nazeer Ahamed R. (1999) *Indian J. Exp. Biol.* 37; 1251-1254.
16. Aladakatti RH, Nazeer Ahamed R, Mukhtar Ahmed, Ghodesawar MG. (2001) *J Basic & Clin. Physiol. Pharmacol.* 12, 69-77.
17. Kasturi M, Nazeer Ahamed R, Pathan KM, Manivannan B, Aladakatti RH. (2002) *J Basic & Clin. Physiol. Pharmacol.* 13, 311-328.
18. Ghodesawar MG, Nazeer Ahamed R, Mukhtar Ahmed AW, Aladakatti RH. (2003) *J Basic & Clin. Physiol. Pharmacol.* 14, 387-395.
19. Ghodesawar MG, Nazeer Ahamed R, Aladakatti RH. (2004) *J. Nat. Rem.* 4(2), 160-167.
20. Ghodesawar MG, Nazeer Ahamed R, Mukhtar Ahmed AW, Aladakatti RH. (2004) *Ind. J. Exp. Biol.* 42, 1091-1095.
21. Mann T, Lutwak - Mann C. (1981) *Springer*. Berlin: 139-144.
22. Samuel LT, Uchikawa T, Huseby RA. (1967) *Found. Colloq. Endocrinol.* 16; 211.
23. Kasinathan S, Ramakrishna S, Basu SL. (1972) *Indian J. Exp. Biol.* 10; 23-25.
24. Pakrashi A, Pakrashi RL. (1977) *Indian J. Exp. Biol.* 15; 250-259.
25. Dixit VP, Joshi S. (1982) *Indian J. Exp. Biol.* 20; 534-536.
26. Dixit VP. (1977) *Indian J. Exp. Biol.* 15; 506-509.
27. Chakraborty S, Pakrashi A. (1991) *Contraception* 43; 273 - 285.
28. Akbarsha MA, Manivannan B, Shahul Hamid K, Vijayan B. (1990) *Indian J. Exp. Biol.* 28; 421-426.
29. Murugavel T, Akbarsha MA. (1991) *Indian J. Exp. Biol.* 29; 810-812.

30. Stanley A, Akbarsha MA. (1992) *Curr. Sci.* 62; 535-537.
31. Stanley A, Averal HI, Akbarsha MA. (1993) *Indian J. Exp. Biol.* 31; 380-382.
32. Lohiya NK, Goyal RB. (1992) *Int. J. Pharmacog.* 30; 308 - 320.
33. Mali PC, Chaturvedi M. (1994) Inhibition of spermatogenesis with the 50% EtOH extract of *Euphorbia nerifolia* Linn. root in male rats. Nat. Symp. Reprod. Health Care and the Fifth Ann. Meet of the Indian. Soc. for the Study of Reprod. and Fertil. Jaipur. Abs. 67.
34. Naseem MZ, Patil SR, Patil SR, Patil SB. (1999) *J. Ethnopharmacol.* 61; 9-16.
35. Verma V, Lall SB. (1999) *Ind. J. Environ. Toxicol.* 9; 20-23.
36. Russell LD, Clermont Y. (1977) *Anat. Rec.* 187; 347-366.
37. Russell LD, Malone JP, Karpas S. (1981) *Tissue. Cell.* 13; 369-380.
38. Kerr JB, Millar M, Maddocks S, Sharpe RM. (1993) *Anat. Rec.* 235; 547-559.
39. O'Donnell L, McLachlan RI, Wreford NG, de Kretser DM, Robertson DM. (1996) *Biol. Reprod.* 55; 895-901.
40. Ghosh S, Sinha Hikim AP, Russell LD. (1991) *Tissue. cell.* 23; 613-630.
41. Udoh P, Kehinde A. (1999) *Phytother. Res.* 13; 226-228.
42. Hild SA, Reel RJ, Lerner JM, Blye RP. (2001) *Biol. Reprod.* 65; 1771-1779.
43. Chowdhury AK, Steinberger E. (1975) *Biol. Reprod.* 12; 609-617.
44. Dym M, Madhwa Raj HG, Lin YC, Chemes HE, Kotite NJ, Nayteh SN, French FS. (1979) *J. Reprod. Fertil. Suppl.* 26; 175-181.
45. Gupta RS, Yadav RK, Dixit VP, Dobhal MP. (2001) *Fitoterapia* 72; 236-245.
46. Venma PK, Sharma A, Mathur A, Sharma P, Gupta RS, Joshi SC, Dixit VP. (2002) *Asian J. Androl.* 6; 67-70.
47. Seetharam YN, Sujeet H, Jyothishwaran G, Barad A, Sharanabasappa G, Umareddy B, Vijaykumar MB, Patil SB. (2003) *Asian J. Androl.* 5; 247-250.
48. B. Vijaykumar, I. S, Sharanabasappa, A, Patil, SB. (2004) *Asian J. Androl* 6, 67-70.
49. Gupta RS, Kachhawa JB, Chaudhary R. (2004) *Asian J. Androl.* 6(2); 155-159.