

Management of Pilonidal Sinus

Yamini Sorate^{1*} and Usha Vaswani²

¹Assistant Professor, Department of Surgery, Dr. Vasantrao Pawar Medical College Hospital and Research Centre, Nashik – 422003, Maharashtra, India; dr_yamini_k@rediffmail.com

²PG Resident, Department of Surgery, Dr. Vasantrao Pawar Medical College Hospital and Research Centre, Nashik – 422003, Maharashtra, India; vaswani_usha@yahoo.com

Abstract

Background: Pilonidal sinus is a chronic benign disease that mostly affects young adults. It is an acquired condition and commonly arises in the sacro-coccygeal region in the hair follicles of the deep natal cleft due to certain etiologic factors like hirsutism, deep natal cleft, obesity, local trauma, local irritation and smoking. **Materials and Methods:** A prospective study was conducted on 40 patients of pilonidal sinus at Dr. Vasantrao Pawar Medical College, Nashik to study the clinical profile and post operative outcome of pilonidal sinus patients from January 2015 to December 2018. **Results:** In this study 40 patients of single pilonidal sinus over the sacro-coccygeal region were studied. The Mean age was 29 years and out of 40 patients 12 were females. The mean hospital stay in patients treated with excision was 29 days, for Z plasty was 24 days and for Limberg flap was 15 days. When followed up for 26 months 2 out of 10 patients treated with Z plasty, 1 out of 5 patients treated with open technique followed up for recurrence, and no recurrence were noted in patients with Limberg flap. **Conclusion:** In our study we conclude Limberg flap was associated with lesser post operative complications, shorter hospital stay, increased patient satisfaction and lower recurrence rate.

Keywords: Limberg Flap, Pilonidal Sinus, Z Plasty

1. Introduction

Pilonidal sinus is a chronic benign disease that mostly affects young adults. It is an acquired condition and commonly arises in the sacro-coccygeal region in the hair follicles of the deep natal cleft due to certain etiologic factors like hirsutism, deep natal cleft, obesity, local trauma, local irritation, poor hygienic conditions and smoking¹. The incidence of pilonidal sinus is estimated to be approximately 26/100000². Treatment ranges from wide local excision of the sinus with or without closure of the wound. There still exists a debate on the optimal surgical method for this condition that would minimize the recurrence rate. The commonly used flaps for primary closure after local wide excision are Limberg flap, Z plasty, Bascom repair and Karydakakis flap. Pilonidal sinus is associated with a high recurrence rate in spite of the several treatment procedures.

2. Methods and Materials

A prospective study was conducted on 40 patients of pilonidal sinus at Dr. Vasantrao Pawar Medical College, Nashik to study the clinical profile and post operative outcome of pilonidal sinus patients from January 2015 to December 2018.

All patients who presented to outpatient department as pilonidal sinus were taken into the study. None of the patients had a history of previous surgeries done for pilonidal sinus elsewhere. All the surgeries were performed at our centre electively. Patients were given spinal anaesthesia and were placed in a prone position with traction applied on buttocks for adequate exposure of the diseased site. Methylene blue was injected in the sinus tract to identify all the branching tracts intra-operatively. The 3 different surgeries offered to the patients were

*Author for correspondence

Limberg flap, Z plasty and excision of sinus with lay open technique with healing by secondary intention.

3. Results

In this study 40 patients of single pilonidal sinus over the sacro-coccygeal region participated of which 25 were treated using the standard.

Limberg flap procedures, 10 were treated using Z plasty and 5 patients were treated using wide local excision with wound healing by secondary intention. The patients in our study did not differ in terms of site of disease or presence of single or multiple sinuses. The Mean age was 29 years and out of 40 patients 12 were females. Out of 10, 3 patients treated with Z plasty showed post operative infections without flap necrosis, no postoperative infection was noted in patients treated with Limberg flap. The mean hospital stay in patients treated with excision was 29 days, for Z plasty was 24 days and for Limberg flap was 15 days.

When followed up for twenty six months 2 out of 10 patients treated with Z plasty and 1 out of 5 patients treated with open technique followed up for recurrence and no recurrence were noted in patients with Limberg flap.

4. Surgical Procedure

4.1 Limberg Flap

Patients were given prone position as described above. Incision was marked with a skin marker and methylene blue injected in the sinus tract. A rhomboid area of skin and subcutaneous fat is excised. The long axis of the rhomboid is in the midline and its shape determined by angles of 60 degrees at A and C and 120 degrees at B and D. As shown in Figure 1. line AC is drawn and length measured. C should be adjacent to perianal skin and A is placed so that all diseased tissue can be included in the excision. Line BD transects the midpoint of AC at right angles and is 60% of its length, the flap is planned so that DE is a direct continuation of line BD and is of equal length to the incision BA to which it will be sutured after rotation. EF is parallel to and equal length to DC. After rotation it will be sutured to AD. The tract including all the lateral extensions was excised up till the fascia overlying the sacrum. Suctions drain was placed in subcutaneous tissue and flap sutured.

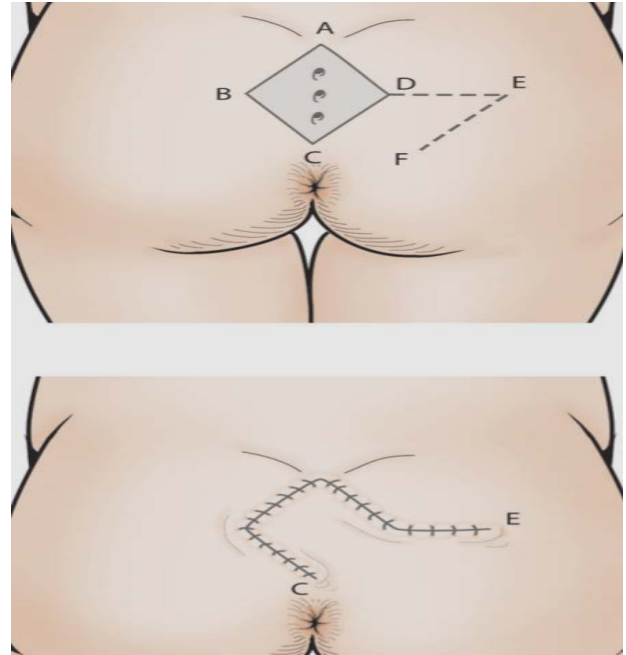


Figure 1. Limberg Flap Marking.

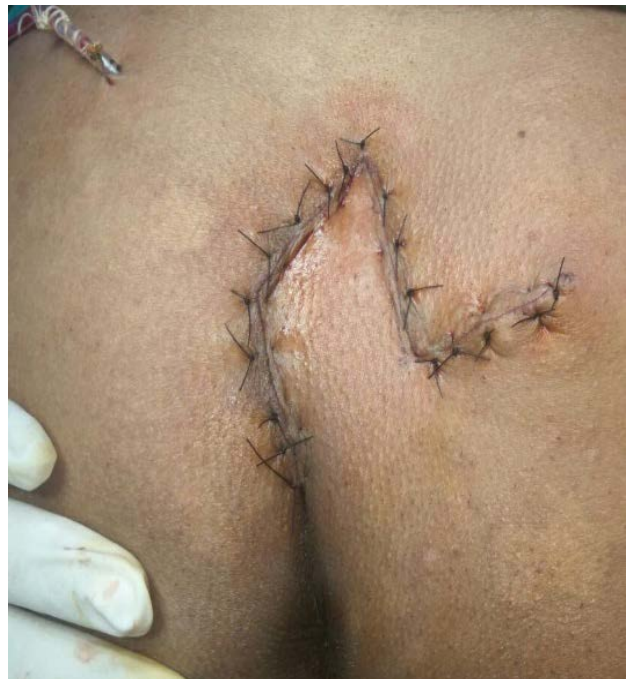

Figure 2. Post op picture of Limberg Flap.

4.2 Z Plasty

Patients were given prone position as described above. Incision was marked with a skin marker and methylene blue injected in the sinus tract and the procedure is done as shown in the Figure 3³.

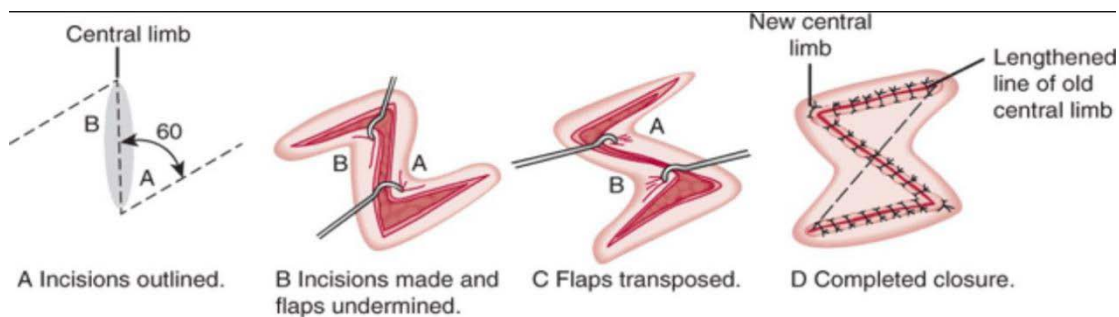


Figure 3. Z Plasty.

4.3 Wide Local Excision of Sinus Laid Open with Healing by Secondary Intension

This technique was used in the patients with extensive superficial spread at subcutaneous tissue. Patients were given prone position as described above. Incision was marked with a skin marker and methylene blue injected in the sinus tract. The tract including all the branches was excised up till the fascia overlying the sacrum and the wound was left open to heal by secondary intension by regular dressings.

5. Discussion

Pilonidal sinus is usually found in the midline over the sacro-coccygeal region. It is an acquired chronic benign condition that mostly affects young adults. It may be associated with certain etiologic factors like hirsutism, deep natal cleft, obesity, local trauma, local irritation and smoking. The most common cause is the accumulation of hairs and subcutaneous hair deposition in the inter gluteal region that later on causes infection and abscess and discharge in sacro-coccygeal region. Recurrence is of main concern in the treatment of pilonidal sinus.

There exists a debate on the optimal surgical method for this condition that would minimize the recurrence rate. Medical treatment involves injection of alcohol or phenol in the sinus cavity⁴. Surgical treatment methods include Limberg flap, Z plasty, Karydakias flap, Bascom procedure and excision of sinus with lay open technique with healing by secondary intension. Lateralisation of natal cleft has become popular for treatment of pilonidal sinus as to prevent recurrence on the midline by removing the cavity over the natal cleft. Limberg flap surgery flattens the natal cleft, provides primary coverage of wound and decreases the recurrence rates. Daphan et al in his study done on 147 patients showed a recurrence rate of 4.8%⁵.

Ertan *et al.*, in their study concluded a recurrence rate of 2% after performing Limbergs flap for pilonidal sinus as compared to a recurrence rate of 12% in a primary closure group⁶. Praveen *et al.*, in their study reported a recurrence rate of 5% after Z plasty technique⁷.

6. Conclusion

The total recovery time and hospital stay was more in open technique than in Limberg flap or Z plasty techniques. However, the recurrence rate was low in Limberg flap and open technique as compared to Z plasty group. In our study we conclude Limberg flap was associated with less post operative complications, shorter hospital stay and improved recovery time, increased patient satisfaction and lower recurrence rate. It has been observed that patients did not required frequent epilation or shaving of lower back. However, a larger randomized study is required for definitive conclusions and recommendation. We plan to continue our study and include more patients and a longer follow up.

7. References

1. Søndena K, Andersen E, Nesvik I, Søreide JA. Patient characteristics and symptoms in chronic pilonidal sinus disease, *International Journal of Colorectal Disease*. 1995; 10(1):39–42. <https://doi.org/10.1007/BF00337585>.
2. Steele SR, Perry WB, Mills S, et al. Practice parameters for the management of pilonidal disease. *Diseases of the Colon and Rectum*. 2013; 56:1021–27. <https://doi.org/10.1097/DCR.0b013e31829d2616>. PMID: 23929010.
3. Cary B. Aarons, Stephen M. Sentovich, Gerad M. Doherty: *Current Diagnosis and Treatment: Surgery*, 14th Ed. Chapter 31: Anorectum <https://accesssurgery.mhmedical.com/content.aspx?sectionid=71523118&bookid=1202>.

4. Girgin M, Kanat BH, Ayten R, Cetinkaya Z, Kanat Z, Bozdogan A, et al. Minimally invasive treatment of pilonidal disease: Crystallized phenol and laser depilation, *International Journal of Surgery*. 2012; 97(4):288–92. <https://doi.org/10.9738/CC130.1>. PMID: 23294066, PMCID: PMC3727265.
5. Daphan C, Tekelioglu S, Sondenaa K, Andersen E, Nesvik I, Soreide JA. Patient characteristics, Sayilgan C. Limberg flap repair for pilonidal sinus disease, *Diseases of the Colon and Rectum*. 2004; 47(2):233–7. <https://doi.org/10.1007/s10350-003-0037-2>. PMID: 15043295.
6. Ertan T, Koc M, Gocmen E, Aslar AK, Keskek M, Kilic M. Does technique alter quality of life after pilonidal sinus surgery? *American Journal of Surgery*. 2005; 190(3):388–92. <https://doi.org/10.1016/j.amjsurg.2004.08.068>. PMID: 16105524.
7. Praveen S, Shah SS, Hyder Z. Excision with Z plasty in pilonidal sinus, *Journal of Surgery Pakistan Int*. 2011; 16:94–7.