

Study of Intraoperative Complications in Small Incision Cataract Surgery, its Management and Visual Outcome

Mrunal Suresh Patil¹, Dhiraj Namdeo Balwir^{2*} and Sonal Dua³

¹Dean & Professor, Department of Ophthalmology, Dr. Vasanttrao Pawar Medical College Hospital & RC, Adgaon, Nashik - 422003, Maharashtra, India

²Associate Professor, Department of Ophthalmology, Dr. Vasanttrao Pawar Medical College Hospital & RC, Adgaon, Nashik - 422003, Maharashtra, India; dheeraj_balwir@yahoo.com

³Postgraduate resident, Department of Ophthalmology, Dr. Vasanttrao Pawar Medical College Hospital & RC, Adgaon, Nashik - 422003, Maharashtra, India

Abstract

Aims: To study the intraoperative complications in small incision cataract surgery and its management and to study the visual outcome following the management of intraoperative complications. **Material and Methods:** A total of 250 cases studied from who underwent SICS. Intraoperative complications were studied and managed. Visual outcome following these complications were studied by noting the best corrected visual acuity after day 1, 1st week, 3rd week, 6th week following surgery. **Results:** The total intraoperative complications were seen in 22 (8.8%) patients. Posterior capsule rent was seen in 6 eyes (2.4%). Iris prolapse in 5 eyes (2%). Descemet detachment was seen in 3 eyes (1.2%). Premature entry was seen in 3 eyes (1.2%). Capsulorrhexis extension was seen in 2 eyes (0.8%). Zonular dialysis was seen in 2 eyes (0.8%). Superior iridodialysis was seen in only one eye (0.4%). Out of 250 cases, 246 came for follow up till 6th week. 214 (85.6%) patients had post operative BCVA 6/6 at the end of 6th week, 25(10%) patients had 6/9, 5 patients (2%) had 6/12-6/18 and remaining 2 patients (0.8%) had 6/24-6/36 BCVA. **Conclusion:** The study results shows that in high quality cataract surgery (91.2% without intraoperative complications) 99% BCVA 6/18 or better can be attained. In our study incidence of intraoperative complications was 8.8% in which posterior capsular rent and iris prolapse were the common intraoperative complications.

Keywords: Small Incision Cataract Surgery, Visual Outcome

1. Introduction

Cataract is the main and biggest cause of curable blindness in India and worldwide. It has been estimated that 3.8 million people develop blinding cataract every year in India as against 2.7 million cataract surgeries done every year¹. Cataract is a significant and increasing global problem with vast economic and social incriminations². In India, it is the principal cause of blindness accounting for 62.6%³. The prevalence of blinding cataract will only increase as people live longer, so cataract will continue to be, by far, the most important treatable cause of blindness.

It is estimated that the present number of 20 million of cataract blind will double by the year 2020⁴. Every year, an extra 1-2 million people go blind. Every five seconds one person in our world goes blind, and a child goes blind every minute. In 75% of these cases the blindness is treatable or preventable⁵. Out of 45 million blinds worldwide, 12 million reside in India⁴.

The main reasons for low uptake of cataract surgery in developing countries are poor surgical outcome and high cost⁶. Various strategies have been suggested by the global initiative "Vision 2020: the right to sight" to reduce cataract blindness⁷.

*Author for correspondence

In India, there are 12.5 million blind and it is estimated that 50% to 80% are due to cataract^{7,8}. An estimated 4 million people become blind because of cataract every year¹ which is added to a backlog of 10 million operable cataracts in India, whereas only 5 million cataract surgeries are performed annually in the country⁹.

It was observed that the number of cataract blind per million people aged 50 years and above would decrease from 53000 per million to 30088 per million by 2020 when prevalent cases of cataract blind are considered. If only the prevalence of cataract blind and the CSR (Cataract Surgical Rate) above the age of 50 years is considered, India would be placed in a comfortable position for eliminating cataract blindness by 2020¹⁰.

Cataract extraction is the most frequently performed operation in patients over 65 years of age. Due to continued improvement in surgical technique the incidence of complications of cataract surgery with intraocular lens implantation have decreased in recent years. Postoperative complications though inevitable, if adequate preventive measures are implicated such as timely diagnosis and appropriate management of complications, ocular morbidity can decrease. In this scenario MSICS with IOL is a hope because this technique is most cost effective to patients as well as doctors, less time consuming, so high volume surgeries are possible¹¹. The procedure is simple, safe and effective. With minimal post operative care and excellent visual outcome, quality vision to rural, underprivileged population is possible. Our current knowledge of the disease indicates that there is no effective medical treatment in inducing the disappearance of cataract once opacities have developed¹².

2. Material and Methods

250 eyes of 250 patients who met the below criteria were included in the study.

a) Inclusion Criteria:

- Patient admitted in ophthalmology ward undergoing Cataract Surgery [SICS]
- Patients who are diagnosed with Senile Cataract

b) Exclusion Criteria:

- Pediatric cataracts
- Traumatic cataracts
- Complicated cataracts

2.1 Pre-Operative Examinations and Investigations

- All patients fulfilling the inclusion criteria were subjected to thorough ocular examination which includes detailed history and clinical examination.
- 1) Complete ocular examination was done which included.
 - Visual Acuity; unaided and Best corrected
 - Complete and detailed Slit lamp examination
 - Fundus examination
 - Intra-ocular pressure measurement by applanation tonometry
 - Sac syringing
 - Keratometry
 - A- Scan biometry and IOL power calculation
 - 2) Investigations were done which included:
 - Complete hemogram
 - Blood sugar level
 - Urine examination
 - ECG
 - 3) All patients were subjected to detailed general and physical examination and preoperative fitness was taken from physician for every patient who underwent cataract surgery.

2.2 Pre-op Preparations

- Written informed consent was taken before surgery.
- Patients were given Tab. Ciprofloxacin 500 mg. B.D. one day prior to surgery. On the previous day of surgery patients were advised to instill antibiotic drops, Eye drop Ciprofloxacin 0.3%. Both upper and lower lid lashes were trimmed on the morning of surgery.
- Dilatation of the pupil was done with Tropicamide and Phenylephrine drops every 10 minutes for 2 hours before surgery.

2.3 Surgical Technique

All the surgeries were performed by single surgeon and observation noted.

2.4 Anaesthesia

- Peribulbar block will be given using 2% Lidocaine + 0.5% bupivacaine

2.5 Surgical Procedure

- The eye to be operated were painted with 5% povidone iodine solution under all aseptic precautions and draped.
- All cases were performed under adequate anesthesia and akinesia by local anesthesia
- Wire speculum was applied for exposure of eyeball
- Fixation of the eye with superior rectus bridle sutures
- A fornix based flap was mobilized and the underlying tenons dissected
- Light cautery applied to the bleeders
- 6-6.5mm sclera tunnel incision was made 2.5mm behind the anterior limbus in manual SICS
- Sclero-corneal tunnel made with crescent blade 0.5 mm- 1 mm into the clear cornea
- A side port paracentesis to facilitate intraocular manipulations at 10 o' clock position in manual SICS
- A 6-6.5mm can opener or continuous curvilinear capsulorrhexis with a bent 26G needle after filling the anterior chamber
- The anterior chamber entered with 2.8 mm keratome
- Internal lip will be extended with 5.2 mm keratome
- Hydro procedures to delineate the nucleus from capsule and cortex
- Viscoelastic is injected, nucleus dialed and is brought in the anterior chamber
- Delivery of nucleus using Sinsky hook/dialer and vectis
- Aspiration of residual matter using simcoe cannula
- A 6 mm PMMA PC-IOL was implanted in the bag using Mc Pherson IOL holding forceps and dialed in position.
- Conjunctiva dragged to cover the wound with cautery
- Post-operatively eye were patched after giving subconjunctival injection of gentamicin and dexamethasone
- All the study participants were observed for the occurrence of any intraoperative complications while undergoing Small Incision Cataract Surgery with their subsequent management

2.6 Post Operative Treatment

2.6.1 Systemically

All the patients were given.

- Tab. Ciprofloxacin 500 mg BD X 3 days.
- Tab. Ranitidine 150 mg BD X 3 days.

2.6.2 Locally

- Moxifloxacin 0.03% eye drops QID x 6 weeks.
- Prednisolone acetate 1 % Eye drops 6 times was prescribed in tapering order.
- Homatropine 0.5 % eye drops BD x 2 weeks.
- All the cases were followed up for 6 weeks postoperative visits. During each visit the following examinations were done.
- Slit lamp examination.
- Study participants were assessed for visual outcome on Day 1, 1st week, 3rd week & 6th week and at every follow up the visual outcome was assessed with the help of Snellen's Chart.
- Visual outcome was analysed according to WHO guidelines:
 - Good - <6/18
 - Borderline - 6/18 -6/60
 - Poor - <6/60

2.7 Statistical Analysis

- All the collected data was entered in Microsoft Excel sheet. It was then transferred to SPSS ver.17 software or statistical analysis
- Qualitative data like sex, type of cataract, etc were presented as frequency and percentages and compared by chi square test.
- P-value of <0.05 was considered as significant.

3. Results

- A total of 250 patients in 38 to 85 years age groups with 130 females and 120 males which fulfilled the inclusion and exclusion criteria, were thoroughly evaluated before surgery and cataracts were graded.
- Out of 250 eyes operated, 71 eyes (28.4%) had PSC with NS grade 2, 65 eyes (26.0%) had Mature senile cataract, 41 eyes (16.4%) PSC with NS grade 3, 19 eyes (7.6%) had Hyper mature cataract and 14 eyes (5.6%) had Cortical with NS grade 2, 11 eyes (4.4%) had Nuclear cataract, 9 eyes (3.6%) had Cortical+ PSC with NS grade 2, 7 eyes (2.8%) had Cortical cataract, 6 eyes (2.4%) had Cortical with NS grade 3, 6 eyes (2.4%) had Posterior polar cataract and only 1 eye (0.4%) had Cortical+ PSC with NS grade 3.

- Majority of eyes had BCVA less than 6/60 i.e. 207 (82.8%). In 43 eyes (17.2%) BCVA was 6/60.
- The total intraoperative complications were seen in 22 (8.8%) patients. Posterior capsule rent was seen in 6 eyes (2.4%). Iris prolapse in 5 eyes (2%). Descemet detachment was seen in 3 eyes (1.2%). Premature entry was seen in 3 eyes (1.2%). Capsulorrhexis extension was seen in 2 eyes (0.8%). Zonular dialysis was seen in 2 eyes (0.8%). Superior iridodialysis was seen in only one eye (0.4%) (Figure 1).
- Mature senile cataract, Hypermature cataract and Posterior Subcapsular Cataract with NS grade 3 were associated with higher rate of intraoperative complications (Figure 2).
- Out of 250 patients 4 lost follow up till 6th week post-operatively.
- Post operative UCVA at day 1 was 6/9 in 122 patients(48.8%),6/12-6/18 in 112 patients (44.8%),6/24-6/36 in 15 patients (3.6%) & 1/60 in one patient (0.4%).

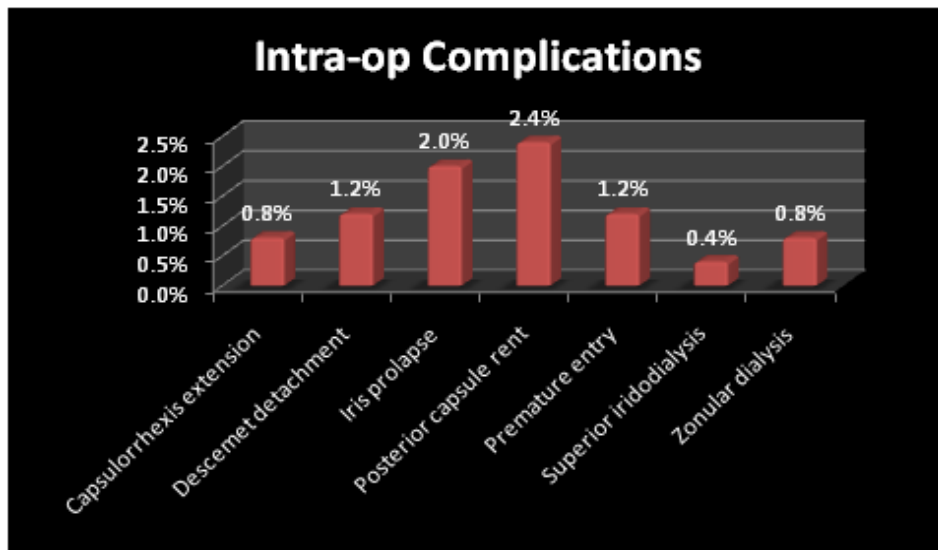


Figure 1. Incidence of intraoperative complications.

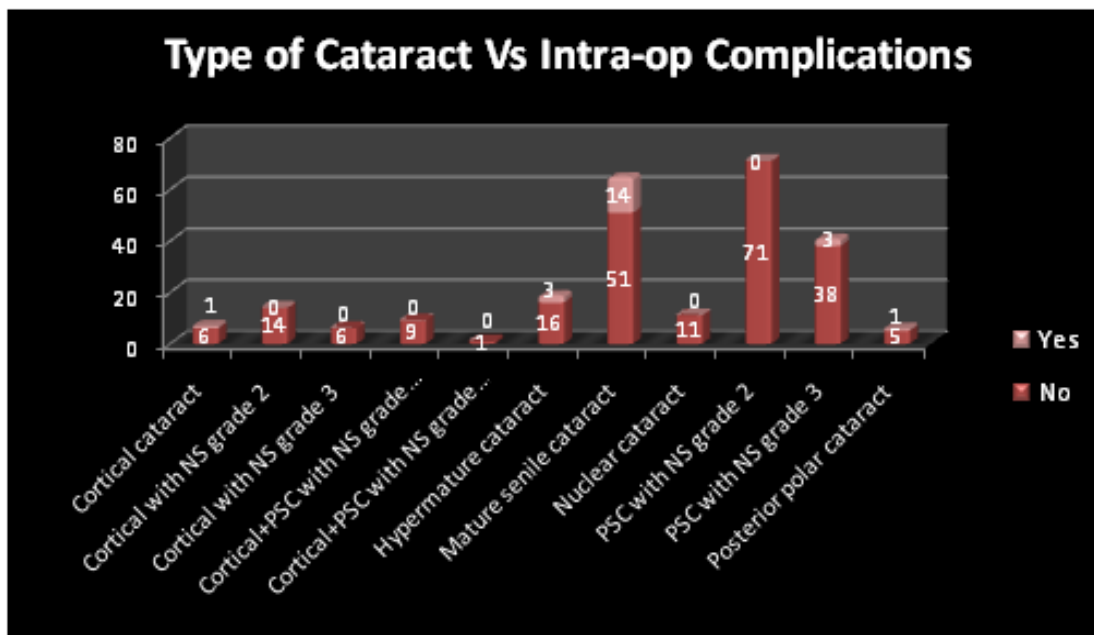


Figure 2. Association of intraoperative complication with type of cataract.

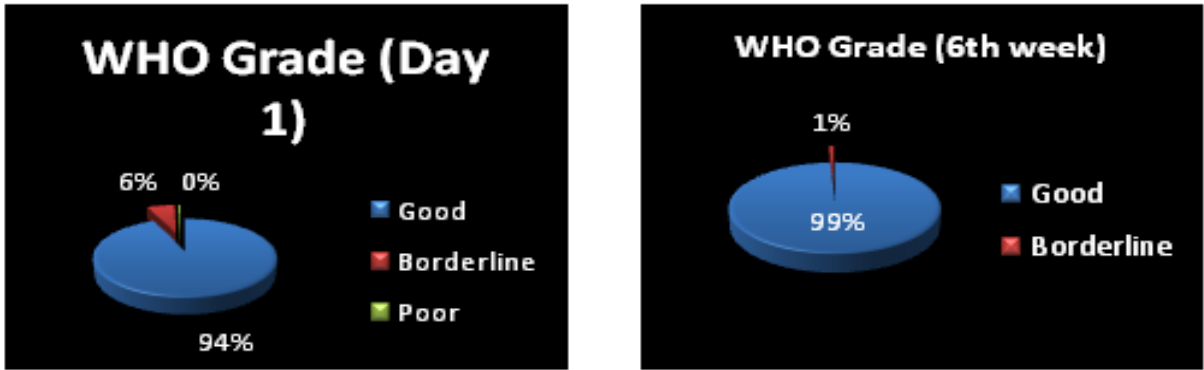

Figure 3. WHO grading for Visual outcome (UCVA Day 1 and BCVA at 6th week).

- Out of 250 cases, 246 came for follow up till 6th week. 214 (85.6%) patients had post operative BCVA 6/6 at the end of 6th week, 25(10%) patients had 6/9, 5 patients (2%) had 6/12-6/18 and remaining 2 patients (0.8%) had 6/24-6/36 BCVA.
- Visual outcome (WHO Grading) observed in 246 cases showed Good visual outcome in 99.18% cases (BCVA >6/18) and borderline visual outcome in 0.81% cases (BCVA 6/24-6/60) (Figure 3).

4. Discussion

The present was conducted on 250 eyes of 250 patients. The patients fulfilling the inclusion and exclusion criteria were evaluated for cataract surgery and cataract was graded. The age at presentation ranged from 38-85 years. Maximum number of patients 134 (53.6%) were in 61 to 70 year age group.

In our study, cataract was Mature in 65 cases (26%), Hyperature in 19 (7.6%), Posterior subcapsular cataract with nuclear sclerosis in 112 (44.8%), Cortical cataract in 7 cases (2.8%), Cortical with nuclear sclerosis in 20 (8%), Cortical +PSC with nuclear sclerosis in 10 cases (4%), Nuclear cataract in 11 (4.4%),Posterior polar cataract in 6 (2.4%).

87(34.8%) patients had preoperative visual acuity of perception of light and hand movements, 119(47.6) had between 1/60 and 3/60 and 44(17.6%) had a visual acuity of 6/60. Patients constituted mainly rural population. Patients ignorance and economic status does not allow them to meet ophthalmologist at the earliest. Hence, majority of the patients in our study were legally blind (visual acuity less than 3/60) preoperatively.

Manual small incision cataract surgery with PCIOL implantation was the procedure performed in majority of

the cases i.e 247 cases (98.8%).MSICS with sulcus fixated IOL was performed in 2 cases (0.8%) & one patient was left aphakic (0.4%).

5. Intraoperative Complications

Of the 250 patients 22 (8.8%) had intraoperative complications. Posterior capsular tear occurred in 6 patients (2.4%) being the most common intraoperative complication in present study followed by iris prolapse in 5 patients (2%), premature entry in 3 patients (1.2%), descemet detachment in 3 patients (1.2%), capsular extension (0.8%), zonular dialysis (0.8%) & others, which included superior iridodialysis, a rare complication occurred in one case (0.4%).

Post operatively after 6 weeks BCVA of $\geq 6/12$ was observed in 245 patients (98%). The UCVA of $\geq 6/12$ at day 1 was observed in 216 patients (86.4%), while that in 18 patients (7.2%) UCVA was 6/18 & that in 15 patients (6%) UCVA was 6/24-6/36 & in one case it was <6/60 (0.4%).

Khanna RC, Kaza S, Palamaner Subash Shantha G, et al.¹³ in 2007 evaluated 522 who underwent manual SICS and reported posterior capsular rent (PCR) followed by zonular dialysis as the most common intraoperative complication occurring in their study. PCR was seen in 36 eyes (6.9%) and zonular dialysis in 20 eyes (3.8%). Descemet detachment was seen in 7 cases (1.3%). Postoperative BCVA was $\geq 6/12$ in 84.3% patients.

Gogate et al.¹⁴ in 2003, evaluated 358 patients who underwent Manual SICS. Intraoperative complications were seen in 29 patients (8.1%). Moderate to severe complications e.g. posterior capsular rent & vitreous loss were seen in 18 cases (5.02%).

Venkatesh et al.¹¹ in 2003 analyzed the outcome of high volume cataract surgeries in a developing country

on 593 patients and reported intraoperative complications in 11(1.9%) cases.

5.1 Posterior Capsular Rent

Posterior capsular rent was seen in 6 cases (2.4%) in our study. Posterior capsule rupture most commonly occurred during irrigation aspiration & due to extension of capsulorrhexis. As soon as the complication was noted, bridle sutures released, aspiration reduced & anterior chamber was filled with viscoelastic material. All 5 cases had vitreous loss, so open sky vitrectomy was performed & PCIOL was implanted in ciliary sulcus in 2 cases. One case was rendered aphakic. Out of 5 cases of posterior capsular rent four occurred in mature senile cataract, one in posterior polar cataract & one in nuclear sclerosis grade 3 with posterior subcapsular cataract. Intraoperative complication occurring most commonly due to thin, fragile capsule & difficulty in performing capsulorrhexis.

Gogate P M¹⁴ in his study evaluated posterior capsular rent as the most common intraoperative complication. It was seen in 18 out of 358 patients (5.02%) & the incidence of PC rent was higher in hypermature and hard cataract & those with small size pupil¹².

Aneesh Neekhra et al.¹⁵, analysed 1820 patients who underwent cataract surgery. Out of 1820, manual SICS was performed in 600. They found that the incidence of posterior capsular tear in patients who underwent SICS was 4% i.e in 24 patients.

Hennig and co-authors¹⁶ reported posterior capsular rent in 0.2% cases whereas Khan reported 3.33%¹⁷.

5.2 Iris prolapse

Iris prolapse was seen in 5 cases (2%) in our study. Iris prolapse occurred mostly during the delivery of nucleus. Out of 5 cases most commonly it occurred in mature senile cataract i.e.in 4 cases & remaining one was seen in hypermature cataract.

Balmer et al.¹⁸ reported iris prolapse in 0.5% cases.

Kongsap et al.¹⁹ in his study reported that iris prolapse as the most common intraoperative complication occurred in 7.37% cases.

Yasir Iqbal et al.²⁰ reported iris prolapse as the third commonest intraoperative complication encountered in 9 patients (3%).

5.3 Premature Entry

Tunnel related complications occurred in 3 cases (1.2%). In all 3 cases there was premature entry. Improper construction of the scleral tunnel can lead to either button holing, if the tunnel is too shallow, and premature entry, if the tunnel is too deep. The premature entry into the anterior chamber makes the tunnel less self sealing therefore in such cases cross suturing was performed using 10-0 nylon suture to close the wound at the end of surgery.

Yasir Iqbal et al.²⁰, evaluated 300 patients who underwent manual SICS and reported premature entry and iris prolapse were the third commonest intraoperative complication encountered in 9 patients (3%).

Hennig A, Kumar J, Singh AK, Ansari A, Singh S, Gurang R, Foster A²¹ in 2001 evaluated 2167 patients who underwent cataract extractions. Surgical complications was seen in 1.2%.

Schroeder²² reported tunnel complications in 1.5% of cases. Schroeder suggested management of a premature entry by starting a more shallow dissection at the other end of the tunnel and suturing of the wound at the end of surgery.

5.4 Descemet's Detachment/tear

Descemet's detachment occurred in 3 patients (1.2%) in our study. It occurred probably due to faulty instrumentation. BCVA in all 3 cases was 6/9.

Khanna RC, Kaza S, Palamaner Subash Shantha G, et al.¹³ evaluated 522 patients undergoing manual SICS & reported descemet detachment in 7 patients (1.3%).

Schroeder²² reported Descemet's detachment in 0.7% of cases.

5.5 Zonular Dialysis

Out of 250 cases who underwent MSICS, in 2 cases (0.8%) there was zonular dialysis, out of which one case had weak zonules & in another case this complication occurred due to small capsulotomy.

Khanna RC, Kaza S, Palamaner Subash Shantha G, et al.¹³ reported zonular dialysis in 20 patients (3.8%) out of total 522 patients who underwent MSICS. This was the most common complication reported in their study along with posterior capsular rent.

5.6 Capsular Extension

Capsule related complications occurred in 2 cases (0.8%) in our study out of total 250 cases.

P. Kongsap¹⁹ reported capsule related complications in 2.11% cases.

5.7 Superior Iridodialysis

This rare complication occurred in 1 case (0.4%) out of total 250 cases.

Gogate et al.¹⁴, reported iridodialysis in 2 cases (0.56%) out of total 358 manual SICS cases. Our study is in accordance with the above study.

Zaman, Mir, et al.²³, reported iridodialysis as the second most common complication in his study. Out of total 1500 cataract surgeries performed, iridodialysis occurred in 20 cases (1.6%).

Apart from above complications there are other complications which were not encountered in our study such as Superior rectus muscle laceration, Button holing of anterior wall of tunnel, Intraoperative miosis, Vitreous loss, Nucleus drop into the vitreous cavity, Posterior loss of lens fragment into the vitreous cavity and Expulsive choroidal hemorrhage

6. Visual Outcome

In our study 246 (98.4%) cases were followed up for six weeks after the cataract surgery. Yorston D reported follow up of 67%, Gogate PM in his study reported follow up of 95.28% cases.

Post operatively after 6 weeks BCVA of $\geq 6/12$ was observed in 243 patients (98.7%). The UCVA of $\geq 6/12$ at day 1 was observed in 216 patients (86.4%), while that in 18 patients (7.2%) UCVA was 6/18 & that in 15 patients (6%) UCVA was 6/24-6/36 & in one case it was $<6/60$ (0.4%)

Venkatesh et al.¹¹ in 2005 in their study achieved BCVA of 6/18 or better in 94.4%.

Gogate et al.¹⁴ in 2003 after 6 weeks of follow up reported BCVA 6/18 or better in 86.7% and 89.8% cases respectively.

Kapoor et al.²⁴ in 1999 reported 79.9% eyes obtained 6/18 or better vision.

Ravindra et al.²⁵ in 1996 reported a BCVA of 6/18 or better in 80.7%.

Sudhakar et al.²⁶ in 1989 reported a visual acuity of 6/12 or better in 80.7%.

Similarly, Hennig et al.¹⁶ in their study reported a BCVA of 6/18 or better in 96.2% and 88.3% respectively.

7. Conclusion

SICS gives uncorrected postoperative visual acuity of 6/18 or better in a greater proportion of patients.

The study results shows that in high quality cataract surgery (91.2% without intraoperative complications) 99% BCVA 6/18 or better can be attained. Posterior capsular rent and iris prolapse were the common intraoperative complications of MSICS in our study. Our technique has all the inherent advantages of the sutureless cataract surgery in terms of universal applicability, greater wound stability, lesser complications and early visual rehabilitation. This surgery is useful in high volume cataract surgery at lower cost which is the need of the hour in the developing world.

8. References

1. Minasian DC, Mehera V. 3.8 Million blinded by cataract each year: Projections of the first epidemiological study of incidence of cataract blindness in India. *Br J Ophthalmol*. 1990; 74:341-3
2. Brian G, Taylor H. Cataract blindness: challenges for the 21st century. *Bulletin of the World Health Organization*. 2001; 79(3):249-56.
3. Park K. *Park's Textbook of Preventive and Social Medicine*, 18th ed., Banarasidas Bhanot, Jabalpur. 2005; 319-23.
4. Thylefors B. A global initiative for the elimination of avoidable blindness. *Community Eye Health*. 1998; 11(25):1-3.
5. Allen D, Vasavada A. Cataract and surgery for cataract. *BMJ: British Medical Journal*. 2006; 333(7559):128-32.
6. Shrestha JK, Pradhan YM, Snelling T. Outcomes of extracapsular surgery in eye camps of eastern Nepal. *Br J Ophthalmol*. 2001; 85: 635-7, and 648-52.
7. Foster A. Cataract and Vision 2020—the right to sight initiative. *Br J Ophthalmol* 2001; 85:635-7.
8. Dada VK, Sindhu N. Management of cataract-A revolutionary change that occurred during last two decades. *J Indian Med Association*. 1999; 97:313-7.
9. Jose R. National Programme for control of blindness. *Indian J Community Health* 1997; 3:5-9.
10. Murthy GVS, Gupta SK, John N, Vashist P. Current status of cataract blindness and Vision 2020: The right to sight initiative in India. *Indian Journal of Ophthalmology*. 2008; 56(6):489-94.

11. Venkatesh R, Muralikrishnan R, Balent LC, Karthik Prakash S, Venkatesh Prajna N. Outcomes of high volume cataract surgeries in a developing country. *Br J Ophthalmol.* 2005; 89:1079–83.
12. Sihota R, Tandon R. *Parsons' Diseases of the Eye*, 21st edition, Elsevier Publications, The Lens. 2011; 18:270.
13. Khanna RC, Kaza S, Palamaner Subash Shantha G, et al. Comparative outcomes of manual small incision cataract surgery and phacoemulsification performed by ophthalmology trainees in a tertiary eye care hospital in India: a retrospective cohort design. *BMJ Open.* 2012; 2:e001035. doi:10.1136/bmjopen-2012-001035.
14. Gogate PM, Deshpande M, Wormald RP, Deshpande R, Kulkarni SR. Extracapsular cataract surgery compared with manual small incision cataract surgery in community eye care setting in western India: a randomised controlled trial. *Br J Ophthalmol.* 2003; 87:667–72.
15. Neekhara A, Trivedi HL, Todkar H. Comparative study of posterior rent in cases of routine extracapsular, small incision non phaco and phacoemulsification. *Small.* 2002; 1000(65):6–5
16. Hennig A, Yorston D, Kumar J, Foster A. Sutureless cataract surgery with nucleus extraction: Outcome of a prospective study in Nepal. *Br J Ophthalmol.* 2003; 87(3):266–70.
17. Khan MT, Jan S, Hussain Z, Karim S, Khalid MK, Mohammad L. Visual outcome and complications of manual sutureless small incision cataract surgery. *Pak J Ophthalmol.* 2010; 26:32–8.
18. Balmer A, Andenmatten R, Hiroz CA. Complications of cataract surgery: Retrospective study of 1304 cases. *Klin-Monstbl-Augeneilkd.* 1991; 198(5):344–6.
19. Kongsap P. Manual sutureless cataract surgery with foldable intraocular lens using the Kongsap technique: the results of 95 cases. *J Med Assoc Thai.* 2007 Aug; 90 (8):1627–32.
20. Iqbal Y, Zia S, Baig Mirza AU. Intraoperative and early postoperative complications of manual sutureless cataract extraction. *J Coll Physicians Surg Pak.* 2014 Apr; 24(4):252–5. doi: 04.2014/JCPSP.252255.
21. Hennig A, Kumar J, Singh AK, Ansari A, Singh S, Gurung R, Foster A. World Sight Day and Cataract Blindness. *Br J Ophthalmol.* 2002; 86:830–1.
22. Schroeder B. Sutureless cataract extraction: complications and management; learning curves. *Comm Eye Health J.* 2003; 16(48):58–60.
23. Zaman M et al. Outcome of sutureless manual extracapsular cataract extraction. *J Ayub Med Coll Abbottabad.* 2009; 21(1):39–42.
24. Kapoor H, Chatterjee A, Daniel R, Foster A. Evaluation of visual outcome of cataract surgery in an Indian eye camp. *Br J Ophthalmol.* 1999; 83:343–6.
25. Ravindra MS, Rekha G. Rural eye camp versus base hospital camp. *Indian Ophthalmol.* 1996; 44:303–4.
26. Sudhakar J, Ravindran RD, Natchiar G. Analysis of complications in 1000 cases of posterior chamber intraocular lens implantation. *Indian J Ophthalmol.* 1989; 37:78–9.