



Prevalence of Femoral Anteversion along with Tibial Torsion in Flat Foot Individuals

Nihar Wadkar^{1*} and Prasannajeet Nikam²

¹Krishna College of Physiotherapy, Krishna Vishwa Vidyapeeth (Deemed to be University), Karad – 415110, Maharashtra, India; n.c.wadkar.7511@gmail.com

²Department of Sports Physiotherapy, Krishna College of Physiotherapy, Krishna Vishwa Vidyapeeth (Deemed to be University), Karad – 415110, Maharashtra, India

Abstract

Objective: To study the prevalence of femoral anteversion and tibial torsion in flat-foot individuals. **Methods:** This project was done among individuals having flat feet. All the genders were included in the study. Flat-foot individuals of the age group 20-30 years were included. Flat-foot individuals with any other orthopaedic problems were excluded from the study. After obtaining ethical permission, the consent form was filled out by all the subjects. A structured assessment was used for assessing the individuals having flat feet, after which segregation was done in that group and the individuals having tibial torsion were included and then the femoral anteversion was checked among the group. **Results:** Among 80 subjects, the finding of this study revealed that there is a prevalence of femoral anteversion along with tibial torsion in flat-foot individuals. The group analysis demonstrated statistically significant impairments in all the outcome measures. After obtaining permission from the ethical committee, the subjects fulfilling inclusion criteria were explained about the study and a structural assessment was conducted, revealing a significant correlation among the Feiss line test, femoral anteversion test and tibial torsion test. **Conclusion:** Flat-foot individuals have femoral anteversion among various individuals. The prevalence of flat-foot individuals having femoral anteversion along with tibial torsion is predominantly higher among the group.

Keywords: Femoral Anteversion, Flat Foot, Tibial Torsion

1. Introduction

The condition in which the arches of the feet are collapsed or not developed is known as flat feet. In this condition, the entire foot touches the ground as all three arches are collapsed. When a person with flat feet stands, no visible arches are found. In this condition, both the legs are affected. At the time of birth, the arches are not developed. After the age of 6, the arches start developing. There are mainly four main types of flat feet, a versatile flat foot, rigid flat foot, adult developed flat foot and vertical talus (flat foot).

Femoral anteversion is a condition characterised by abnormal inward rotation of the femoral bone which connects the hip bone to the pelvis¹. In flat feet, femoral anteversion takes place in both legs or one leg. This condition is more common in females. This condition mainly develops during the development of the child in the womb². The term “femoral retroversion” refers to the condition in which one leg is inwardly rotated and the other, or opposite, leg is outwardly rotated. The biomechanics of the hip joint get affected due to femoral anteversion. The development of femoral anteversion is influenced by the mechanical force that is experienced in everyday movement³. It will affect the alignment of the

*Author for correspondence

lower limb. The tibia is also affected in addition to the femoral anteversion⁴.

An inward twisting of the tibia takes place. The tibia's alignment is affected which causes postural deformity⁵. The tibial torsion has an impact on gait and muscle function. It causes a disturbance in patellofemoral biomechanics⁶. Muscle imbalance puts strain on various joints, such as the hip joint, knee joint and ankle joint. The restriction in ankle joint mobility is caused by calf muscle tightness⁷.

The purpose of this study is to determine the prevalence of femoral anteversion and tibial torsion in flat-footed people. This study helps in the analysis of the biomechanics of lower limbs in flat foot persons⁸.

This research helps in the development of a treatment protocol for postural deformity and corrects the affected lower limb biomechanics in flat-footed individuals. It can improve the quality of life for the flat-footed population. Orthopaedic complications were previously reported for patients with increased femoral anteversion. Rotation deformity of the lower limb in a flat foot is a very serious issue. A more comprehensive analysis of the influence of increased femoral anteversion on joint loading in these patients is required for a better understanding of its pathology and clinical management. Various studies were done to investigate lower-limb kinematics, joint moments and forces during gait in adolescent patients with increased, isolated femoral anteversion compared to typically developing controls. But this study includes femoral anteversion along with tibial torsion in flat foot individuals, and also studies the abnormality in gait pattern of flat foot and marks the severity of abnormality found in flat foot.

2. Methodology

2.1 Procedure

Once permission was granted from the protocol committee, an assessment of the individuals with flat feet was done. The individuals included in the study based on the inclusion criteria, were explained about the procedure and proper consent was taken. A proper assessment was done and the data was collected using a data collection sheet.

2.2 Study Design

This is an analytical study.

2.3 Subject Criteria

A total of 80 subjects of all genders having flat feet were selected for the study. The age of the individuals was between 20-30 years.

3. Outcome Measures

The outcome measures were the Feiss line test, femoral anteversion test and tibial torsion test. The individuals with flat feet were assessed using the Feiss line test. For femoral anteversion, the Craigs test was used and to find out the tibial torsion angle, the thigh foot angle was measured.

3.1 Data Collection Tools

3.1.1 Measurement of Feiss Line

The patient was explained about the Feiss line measurement method which is the most convenient way to measure the flat foot and it doesn't require any complicated instruments or a complex method. The line is measured with the help of a scale and a marker and based on the grades the grading is done under three grades.

Grade 1: In grade 1, the navicular tuberosity falls 1/3rd of the distance of the floor.

Grade 2: In this grade, the point falls 2/3 of the distance away from the floor.

Grade 3: In grade three, the navicular tuberosity touches the floor.

3.1.2 Craig's Test

Craig's test is a passive test that will be used to measure femoral anteversion or forward torsion of the femoral neck. Based on the interpretation, an angle above 15 degrees (anteversion), below 3 degrees (retroversion) and normal are noted.

3.1.3 Foot Angle

To find out the tibial torsion in patients having flat feet and femoral anteversion, the thigh foot angle is measured.

3.1.4 Statistical Analysis

The outcome measures were evaluated at the start of the study. In this study, descriptive statistics such as bar diagrams and percentages were used to statistically assess the acquired data.

4. Results

All statistical analyses, including the calculation of the mean and standard deviation of all the tests, were done using SPSS statistical software. In this study, descriptive statistics such as bar diagrams and percentages were used to statistically assess the acquired data.

4.1 Demographic Variables

A total of 80 patients were included in the study, in which individuals with flat feet were assessed with the help of the Feiss Line Test.

Out of a total of 80 flat foot patients, 60% had Grade 3 flat foot, 30% had Grade 2 flat foot whereas 10% had Grade 1 flat foot.

Data analysis of the sample size was done based on the total number of tibial torsion individuals, femoral anteversion and tibial torsion along with femoral anteversion.

The results interpreted that among the 80 sample size, femoral anteversion was 10%, tibial torsion was 35% and femoral anteversion along with tibial torsion was 55%.

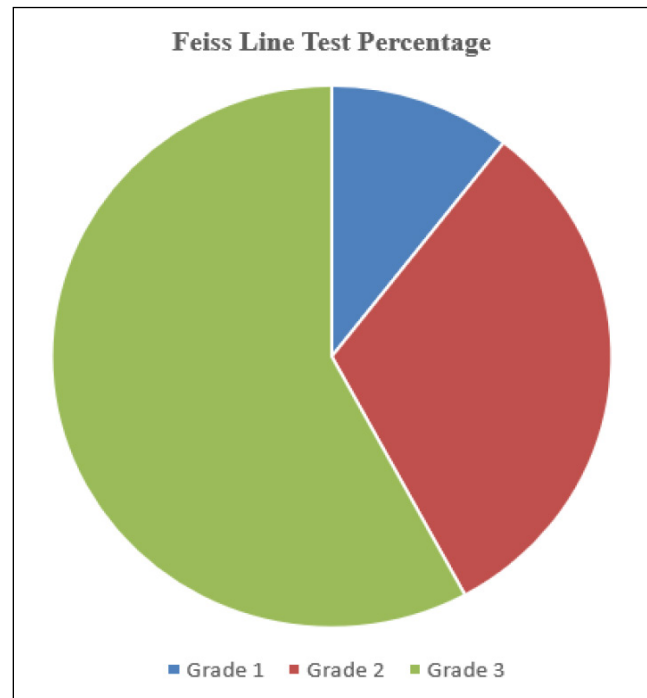


Figure 1. Pie Diagram: Feiss line test.

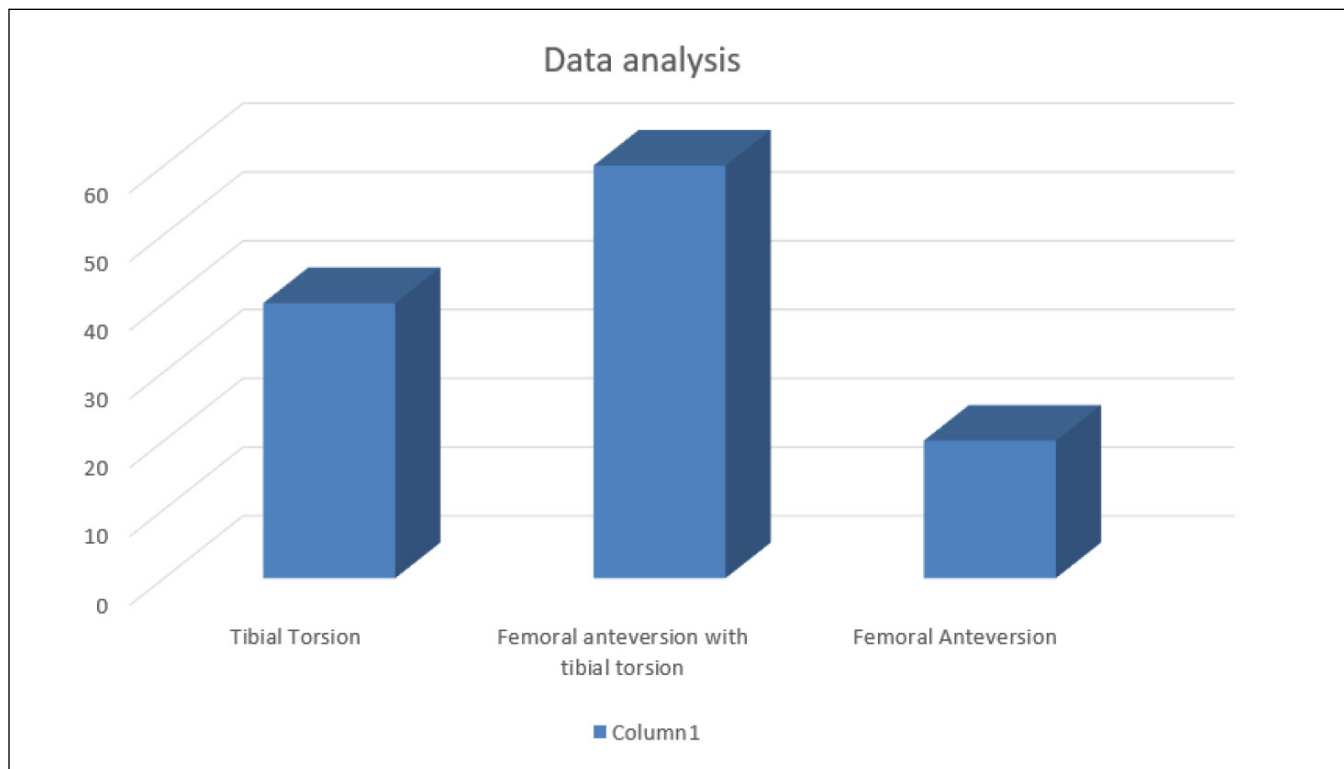


Figure 2. Bar Diagram: Torsion angles.

5. Discussion

The study was done in 9 months among the flat-foot individuals. The study was undertaken to focus on the prevalence of femoral anteversion along with tibial torsion in flat-foot individuals. When a person with flat feet stands, no visible arches are found. In this condition, both legs are affected. The arches are not developed at the time of birth and start developing after the age of 6. In flat feet, femoral anteversion takes place in both legs or one leg. In girls, this condition is more common. This condition mainly develops during the development of the child in the womb. The term “femoral retroversion” refers to the condition in which one leg is inwardly rotated and the other, or opposite, leg is outwardly rotated. The biomechanics of the hip joint get affected due to femoral anteversion. The development of femoral anteversion is influenced by the mechanical force that is experienced in everyday movement. It will affect the alignment of the lower limb. The tibia is also affected in addition to the femoral anteversion. An inward twisting of the tibia takes place. The tibia's alignment is affected causing postural deformity. The tibial torsion has an impact on gait and muscle function. It causes a disturbance in patellofemoral biomechanics.

Various studies were done to investigate lower-limb kinematics, joint moments and forces during gait in adolescent patients with increased, isolated femoral anteversion compared to typically developing controls. But this study includes femoral anteversion along with tibial torsion in flat foot individuals and also finds out abnormality in the gait pattern of flat foot and marks the severity of abnormality found in flat foot.

A study was conducted by Akcali O *et al.*,¹ on the effects of tibial torsion on flexible flatfoot with 20 children with flexible flatfoot and external tibial torsion. A group of 10 children with flexible flatfoot without any rotational problems was formed. The tibial torsion was measured with computed tomography. It was observed that plantar flexion angle of the talus and dorsoplantar talocalcaneal angle was not more significant ($p < 0.005$ and $p < 0.005$ respectively) and the naviculocuneiform sag was more prominent. It was concluded that abnormal external tibial torsion may affect the foot deformity and this can change the benign nature of the flexible flatfoot.

The purpose of this study is to determine the prevalence of femoral anteversion and tibial torsion in flat-footed people. This study helps in the analysis of the

biomechanics of the lower limb in flat feet person and also helps in the development of a treatment protocol for postural deformity and corrects the affected lower limb biomechanics in flat-footed individuals. It can improve the quality of life for the flat-footed population. Orthopaedic complications were previously reported for patients with increased femoral anteversion.

The study was conducted among 80 subjects in the age group of 20-30 years having flat feet. Once permission is granted from the protocol committee, an assessment of the individual's having flatfoot was done, proper consent was taken from all the subjects and the procedure was explained to them about the assessment and the outcomes. The subject's history was also checked to rule out any problems related to orthopaedic conditions. The data collection sheet was then filled with basic demographic data and a few tests. The patient was explained the Feiss line measurement method which is the most convenient way to measure the flat foot as it doesn't require any complicated instruments or a complex method. With the help of a scale and a marker, the line was measured and based on the grades the grading was done.

This was followed by Craig's test which was used to measure femoral anteversion or forward torsion of the femoral neck. Based on the interpretation angle above 15 degrees (anteversion), below 3 degrees (retroversion) and normal were noted. To find out the tibial torsion in patients having flat feet and femoral anteversion, the thigh foot angle was measured.

Rotation deformity of the lower limb in a flat foot is a very serious issue. A more comprehensive analysis of the influence of increased femoral anteversion on joint loading in these patients is required to better understand the pathology and its clinical management.

6. Conclusion

Based on the results and interpretations it is found that the mean population of the flat foot individuals based on the tests for femoral anteversion and tibial torsion had a femoral anteversion along with tibial torsion. The mean deviation between femoral anteversion and tibial torsion showed that femoral anteversion was higher than tibial torsion.

In this study, with the help of outcome measures it is concluded that flat-foot individuals have a femoral anteversion along with tibial torsion.

7. Ethical Approval

The institutional ethics committee of Krishna Institute of Medical Science” Deemed to be University”, Karad has permitted to initiate the project work.

Protocol number- 658/2022-2023

8. Reference

1. Akcali O, Tiner M, Ozaksoy D. Effects of lower extremity rotation on prognosis of flexible flatfoot in children. *Foot Ankle Int.* 2000; 21(9):772-4. PMID: 11023226. <https://doi.org/10.1177/107110070002100910> PMid:11023226.
2. Van Boerum DH, Sangeorzan BJ. Biomechanics and pathophysiology of flat foot. *Foot Ankle Clin.* 2003; 8(3):419-30. PMID: 14560896. [https://doi.org/10.1016/S1083-7515\(03\)00084-6](https://doi.org/10.1016/S1083-7515(03)00084-6) PMid:14560896.
3. Arachchige SNKK, Chander H, Knight A. Flatfeet: Biomechanical implications, assessment and management. *Foot (Edinb).* 2019; 38:81-85. Epub 2019 Feb 11. PMID: 30844660. <https://doi.org/10.1016/j.foot.2019.02.004> PMid:30844660.
4. Scorcelletti M, Reeves ND, Rittweger J, Ireland A. Femoral anteversion: Significance and measurement. *J Anat.* 2020; 237(5):811-26. Epub 2020 Jun 24. PMID: 32579722; PMCID: PMC7542196. <https://doi.org/10.1111/joa.13249> PMid:32579722 PMCID: PMC7542196.
5. Murphy SB, Simon SR, Kijewski PK, Wilkinson RH, Griscom NT. Femoral anteversion. *J Bone Joint Surg Am.* 1987; 69(8):1169-76. PMID: 3667647. <https://doi.org/10.2106/00004623-198769080-00010>
6. Lampert C, Thomann B, Brunner R. Tibiale torsionsfehler [Tibial torsion deformities]. *Orthopade.* 2000; 29(9):802-7. German. <https://doi.org/10.1007/s001320050529> PMid:11092002.
7. Noonan B, Cooper T, Chau M, Albersheim M, Arendt EA, Tompkins M. Rotational deformity- when and how to address femoral anteversion and tibial torsion. *Clin Sports Med.* 2022; 41(1):27-46. PMID: 34782074. <https://doi.org/10.1016/j.csm.2021.07.011> PMid:34782074.
8. Davids JR, Davis RB. Tibial torsion: significance and measurement. *Gait Posture.* 2007; 26(2):169-71. Epub 2007 Jun 1. Erratum in: *Gait Posture.* 2009; 30(4):563. PMID: 17544274. <https://doi.org/10.1016/j.gaitpost.2009.07.120>