

Glucocorticoid-Induced Alterations in the Reproductive Functions of Male *Mus terricolor*, the Indian Pygmy Field Mouse

Sweta Arora², Poonam Singh¹ and Chandana Haldar^{2*}

¹Mahila Mahavidyalaya, Banaras Hindu University, Varanasi – 221005, Uttar Pradesh, India;

²Pineal Research Laboratory, Department of Zoology, Centre of Advanced Study, Banaras Hindu University, Varanasi – 221005, Uttar Pradesh, India; chaldar2001@yahoo.com

Abstract

The Indian pygmy field mouse, *Mus terricolor*, a wild rodent has to face many stressors in the environment such as unpredictable harsh weather, non-static habitats, food shortage, water scarcity, social pressure, risk of predators and parasites, etc. Glucocorticoids are known to suppress reproductive functions during the stressful situations in many rodents. No report till date exists demonstrating the effects of stress on the reproduction in male *M. terricolor*, a tropical, wild, nocturnal, short day breeder. To replicate stress-like situation under experimental condition, dexamethasone (60µg/100g body weight) treatment was given to this tiny rodent during the Reproductively Active Phase (RAP) of its breeding cycle. Administration of dexamethasone led to significant reductions in the weights of gonad and accessory sex organs, which were accompanied by significant reductions in the biochemical constituents viz., epididymal sialic acid and seminal vesicular fructose. The levels of plasma testosterone also decreased significantly while there was a significant increase in the gonadal cholesterol after the treatment. Histological observations revealed inhibitory effects of dexamethasone on the reproductive tissues. It is, therefore, suggested that the stressful condition due to exogenous administration of glucocorticoid suppresses the reproductive functions of *M. terricolor*.

Keywords: Glucocorticoid, *M. terricolor*, Reproduction, Stress, Tropical Rodent

1. Introduction

The environmental stressors lead to behavioral, physiological and homeostatic deterioration in wild animals. Glucocorticoids secreted from the adrenal plays a key role in modulating any type of stressful situation. Increase in glucocorticoid secretion in response to stress in an organism is the first line of defense for coping up with the adverse condition. The increase in glucocorticoid level leads to activation of Hypothalamo-Pituitary-Adrenal (HPA) axis and consequent inhibition of reproductive functions²⁸ and immunity^{14,16}.

It has been reported that during stress conditions glucocorticoid level in circulation increases sharply resulting in diminished libido and fertility along with

testicular involution and significant drop in testosterone secretion through suppressed androgen synthesis and reduction in the numbers of Leydig cells as a result of apoptosis^{1,13,17,23,25,31,36,37}. Increased glucocorticoid levels have been reported to disrupt and suppress endocrine signaling in the male reproductive axis^{5,33}. Tsantarliotou *et al.*,³⁵ and Gur *et al.*,¹⁵ have observed inhibitory effects of dexamethasone on total acrosin activity, sperm concentration, semen volume and sperm motility in rams. Later, the findings of Sapolsky³¹ have suggested that inhibition of testosterone level in the blood is partly due to direct receptor-mediated effect of glucocorticoid in Leydig cells, but during chronic stress conditions gonadotropin secretion by pituitary is reduced which leads to reduced testosterone. Further, Payne and Sha²⁶ and Orr *et al.*,²⁵

*Author for correspondence

have reported that glucocorticoid directly inhibits the transcription of genes encoding testosterone biosynthetic enzymes.

M. terricolor is a wild, seasonally breeding⁴ animal and it faces various types of challenges and stresses. The effects of stress on the reproduction have already been demonstrated on its female counterpart³. Therefore, the present experiment was designed to study the effects of dexamethasone treatment on male *M. terricolor*.

2. Materials and Methods

2.1 Maintenance of Animals

All experiments were conducted in accordance with the institutional practice and within the framework of revised Animal (Specific Procedure) Act of 2007 of Government of India on animal welfare. Experiment was performed during reproductively active phase of the animal. The mice were collected from the fields in the vicinity of Varanasi (Lat. 25°, 18' N; Long. 83°, 1'E), India, following the methods as described earlier^{7-9,32}. In the laboratory the animals were acclimated to the ambient conditions for two weeks. They were kept in commercial polypropylene cages during the experiments and maintained in a well-ventilated room exposed to ambient conditions (27±2°C, with gentle ventilation). Mice were fed with commercial food pellets along with wheat, paddy/rice and water *ad libitum*.

2.2 Experimental Groups

Healthy young adult male mice of body weight 11±1.0 g were randomly selected from the collection and assigned to two groups of six each.

The mice in the first group (n = 6) were treated with normal ethanolic saline (0.9%) and served as control. The mice in the second second group (n = 6) were given intramuscular injection of dexamethasone (Dex) at a dose of 60µg/100g body wt/day^{4,16,14} for 15 days during the afternoon. Dexamethasone was first dissolved in a few drops of ethanol and then diluted with normal saline to the desired concentration.

2.3 Sample Collection

Twenty four hours after the last injection, mice were weighed and sacrificed by total body anesthesia. Blood

was collected directly from the heart in heparinized tubes. Plasma was separated and frozen at -80°C till ELISA for testosterone (DIAMETRA, Lot no. DKO002) was carried out. Testes, epididymis and seminal vesicles were dissected out on ice, blotted free from blood, cleaned from extra tissue, and weighed on an electronic balance (Denver Instruments, Gottingen, Germany). Testis, epididymis and seminal vesicle of left side were fixed in Bouin's fluid for histology while those of right side were kept for biochemical estimations of testicular cholesterol, epididymal sialic and fructose in the seminal vesicle.

2.4 Histology

After fixation in Bouin's fluid, testis, epididymis and seminal vesicle were processed for routine histological procedure. Some 6-µm sections were deparaffinized and stained using Ehrlich's hematoxylin and eosin. The stained sections of the tissues were observed in a microscope (Leica MPV-3, Germany) and documented.

2.5 Biochemical Estimations

Cholesterol in testis was estimated using manufacturer's protocol (Bio Lab Diagnostics, India). The concentrations of sialic acid in the epididymis and fructose in the seminal vesicle were estimated following the methods of Aminoff² and Linder and Mann²⁰, respectively.

2.6 Hormonal Analysis

2.6.1 ELISA for Testosterone

The plasma levels of testosterone in the respective groups were estimated according to manufacturer's instruction. ELISA kit for testosterone assay was purchased from Dia Metra (Lot No; DKO002). According to the manufacturer's instruction, 25 µl of standard, control and sample were added in each well of the ELISA plate followed by addition of 100 µl of the enzyme conjugate solution and 100 µl of the testosterone antiserum. The ELISA plate was incubated with mild shaking at room temperature for one hour. Wells were aspirated and washed thrice with double distilled water. Then, 100 µl of the TMB chromogenic solution was added to each well and incubated the plate further at room temperature for 30 minutes. Finally, 100 µl of stop solution (0.2 M H₂SO₄) was added and the absorbance was recorded at 450 nm using a microplate ELISA reader (BioTek).

2.6.2 ELISA for Corticosterone

ELISA kit for corticosterone was gift from NIHF, New Delhi, India. According to the manufacturer's instruction, 50 μ l of standard, control and samples were added in each well of ELISA plate followed by addition of 50 μ l of HRP-corticosterone conjugate solution. The wells were incubated at room temperature with mild shaking for 60 minutes. The wells were then rinsed and flicked 7-10 times with running tap water. Then, 100 μ l of the substrate solution was added to each well and plate was incubated at room temperature for 15 minutes. Finally, 100 μ l of stop solution was added in each well and the absorbance was recorded at 450 nm.

2.7 Statistical Analysis

Statistical analysis of the data was performed with Student's 't'-test. The differences were considered significant when $P \leq 0.05$.

3. Results

3.1 Body Weight

No significant difference in body weight was observed between ethanolic saline-treated control mice and dexamethasone-treated mice (Figure 1).

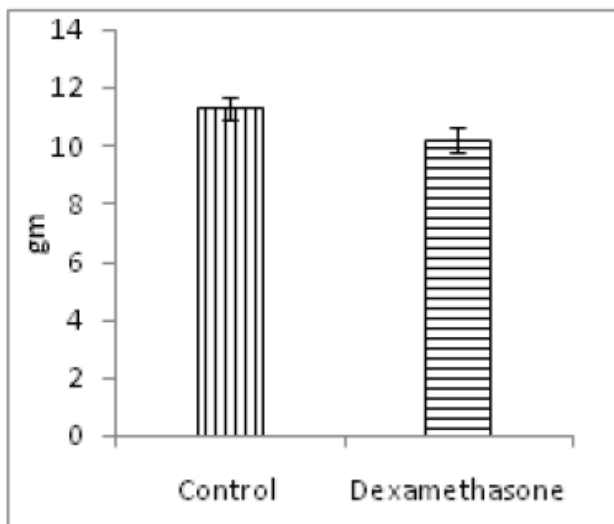


Figure 1. Effect of dexamethasone injections on body weight of male *M. terricolor*. Note significant change was found after the treatment. Values on vertical bars represent mean + SEM of six animals.

3.2 Weight of Reproductive Organs

Significant reductions were noticed in the relative weights of the testes (Figure 2), epididymis (Figure 3) and seminal vesicles (Figure 4) of dexamethasone-treated mice as compared with their respective controls.

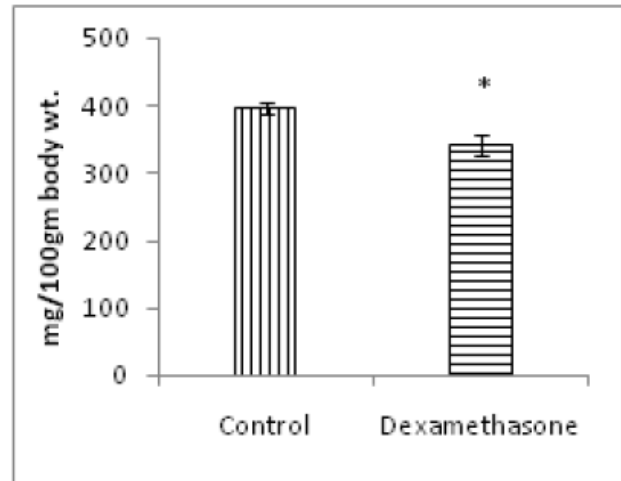


Figure 2. Effect of dexamethasone injections on relative weight of testes of *M. terricolor*. Note significant reduction in the testicular weight of treated mice. Values on vertical bars represent mean + SEM of six animals. * Significance of difference, $P < 0.05$ with respect to control.

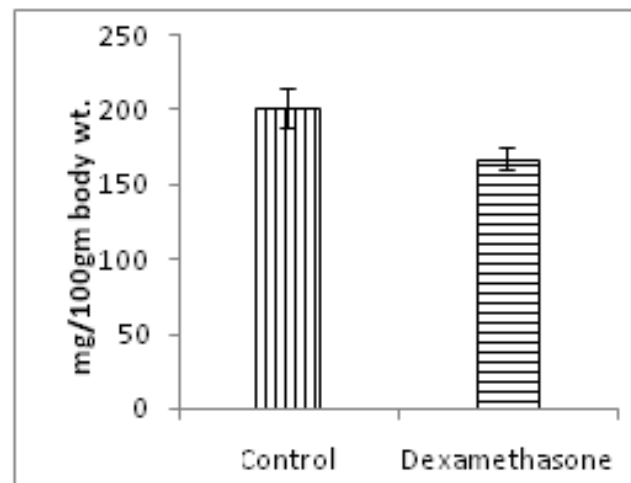


Figure 3. Effect of dexamethasone injections on relative weight of epididymis of *M. terricolor*. Note significant reduction in the weight of the epididymis of treated mice. Values on vertical bars represent mean + SEM of six animals. * Significance of difference, $P < 0.05$ with respect to control.

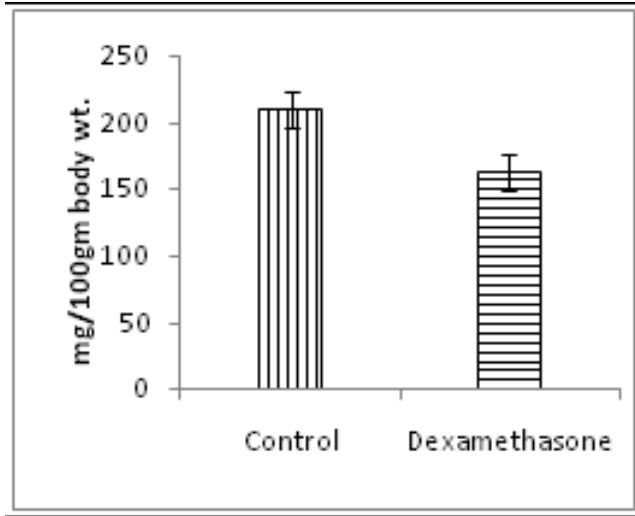


Figure 4. Effect of dexamethasone injections on relative weight of seminal vesicle of *M. terricolor*. Note significant reduction in the weight of the seminal vesicle of treated mice. Values on vertical bars represent mean + SEM of six animals. * Significance of difference, $P < 0.05$ with respect to control.

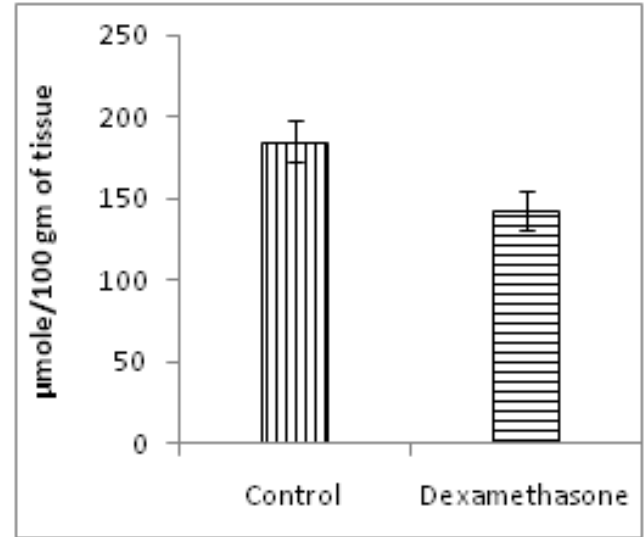


Figure 6. Effect of dexamethasone injections on the epididymal sialic acid of *M. terricolor*. Note significant decrease in the level of sialic acid. Values on vertical bars represent mean + SEM of six animals. * Significance of difference, $P < 0.05$ with respect to control.

3.3 Biochemical Parameters

A significant elevation in the content of testicular (Figure 5) cholesterol while significant reductions in the epididymal sialic acid (Figure 6) and seminal vesicular fructose (Figure 7) were observed in dexamethasone-treated group as compared with the control.

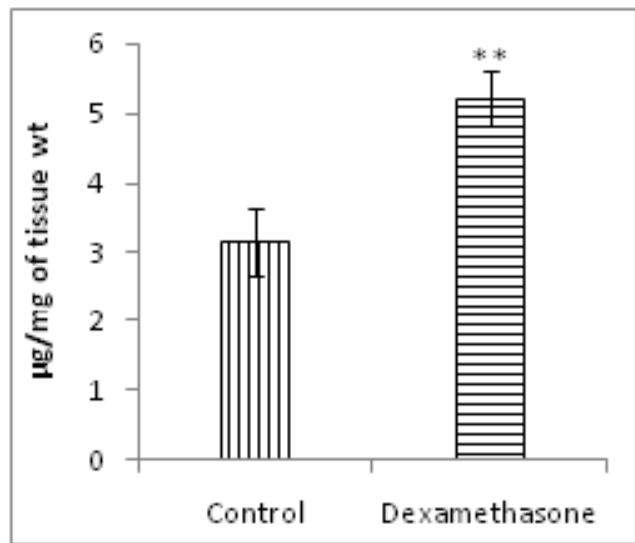


Figure 5. Effect of dexamethasone injections on the testicular cholesterol of *M. terricolor*. Note significantly elevated level of cholesterol in the treated group. Values on vertical bars represent mean + SEM of six animals. ** Significance of difference, $P < 0.01$ with respect to control.

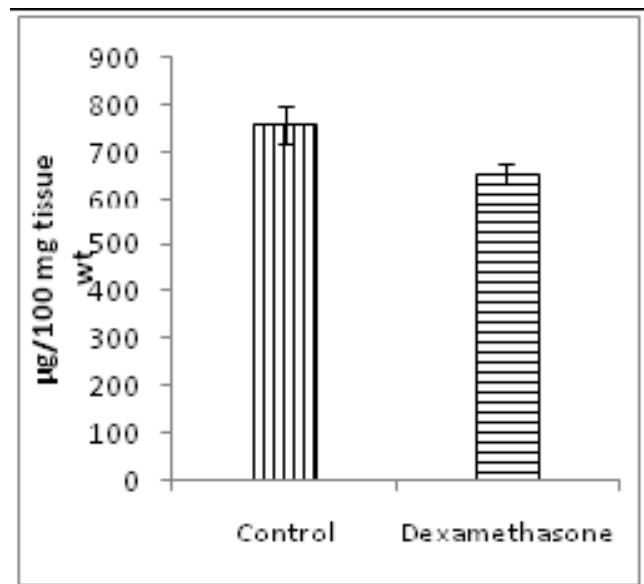


Figure 7. Effect of dexamethasone injections on seminal vesicular fructose of *M. terricolor*. Note significant reduction in the level of fructose of treated mice. Values on vertical bars represent mean + SEM of six animals. * Significance of difference, $P < 0.05$ with respect to control.

3.4 Hormonal Analysis

Significantly decreased levels of peripheral plasma testosterone (Figure 8) were noticed in dexamethasone-treated group when compared with their respective control

groups. While dexamethasone treatment led to a significant increase in the level of plasma corticosterone (Figure 9).

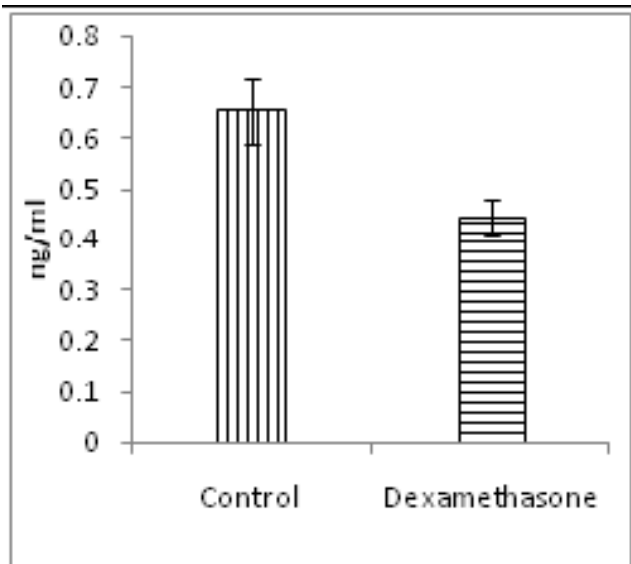


Figure 8. Effect of dexamethasone injections on the level of plasma testosterone of *M. terricolor*. Note significant reduction in the level of testosterone of treated mice. Values on vertical bars represent mean + SEM of six animals. * Significance of difference, $P < 0.05$ with respect to control.

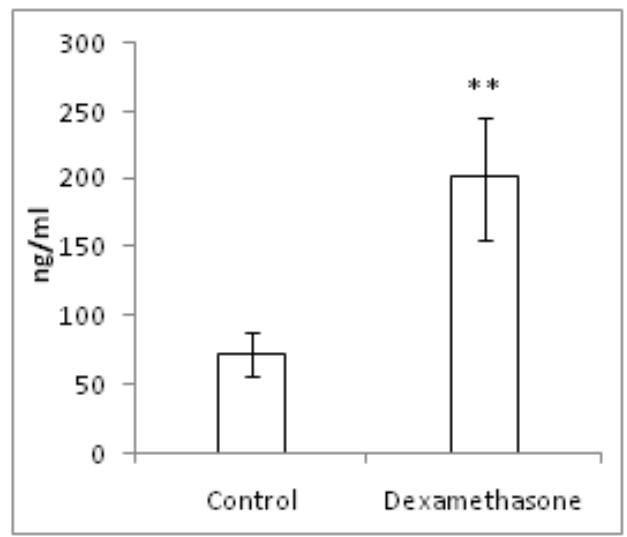


Figure 9. Effect of dexamethasone injections on the level of plasma corticosterone of *M. terricolor*. Note significant increase in the level of corticosterone in treated mice. Values on vertical bars represent mean + SEM of six animals. ** Significance of difference, $P < 0.01$ with respect to control.

3.5 Histological Observations

The testis of control animals showed normal histological features. Majority of the seminiferous tubules showed full

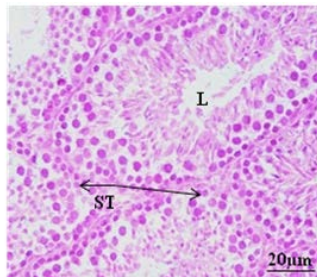


Fig. 1.10A

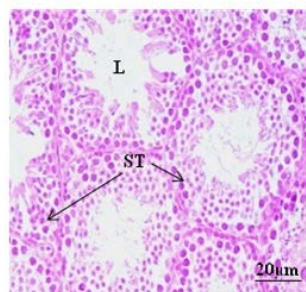


Fig. 1.10B

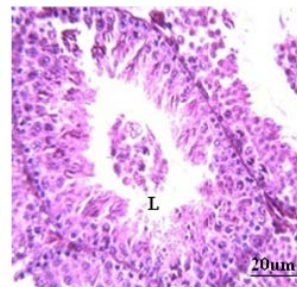


Fig. 1.10C

Figure 10A. T.S. of testis of *M. terricolor* following saline injection. Note the active seminiferous tubules presenting complete stages of spermatogenesis. EL: Epithelial lining, L: Lumen, ST: Seminiferous tubules.

B. T.S. of testis of *M. terricolor* following 15 days of dexamethasone injections. Note the regressive changes as indicated by thinning of tunica propria and loss of some stages of germ cells. EL: Epithelial lining, L: Lumen, ST: Seminiferous tubules.

C. T.S. of testis of *M. terricolor* following 15 days of dexamethasone injections showing sloughing of germ cells. EL: Epithelial lining, L: Lumen, ST: Seminiferous tubules.

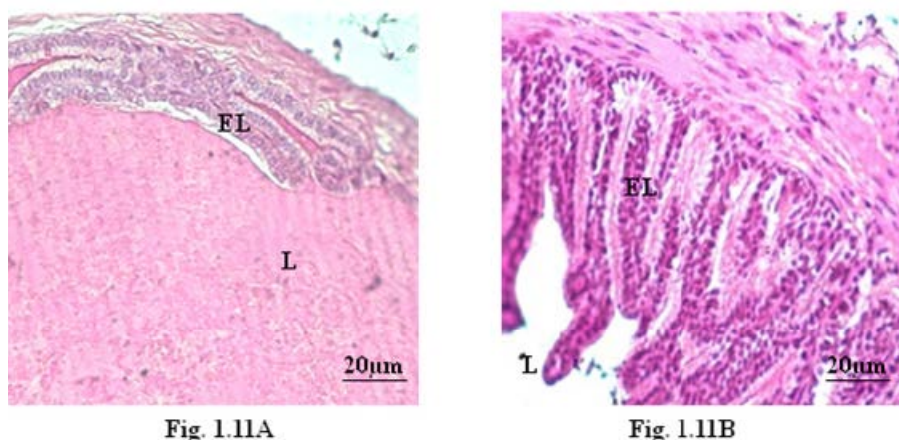


Figure 11. T.S. of seminal vesicle of *M. terricolor* following saline injection. Note the wide lumen filled with secretions. EL: Epithelial lining, L: Lumen.

B. T.S. of seminal vesicle of *M. terricolor* following 15 days of dexamethasone injections. Note the regressive changes as indicated by excessive inward ramification of epithelial lining and scanty secretion in the reduced lumen. EL: Epithelial lining, L: Lumen.

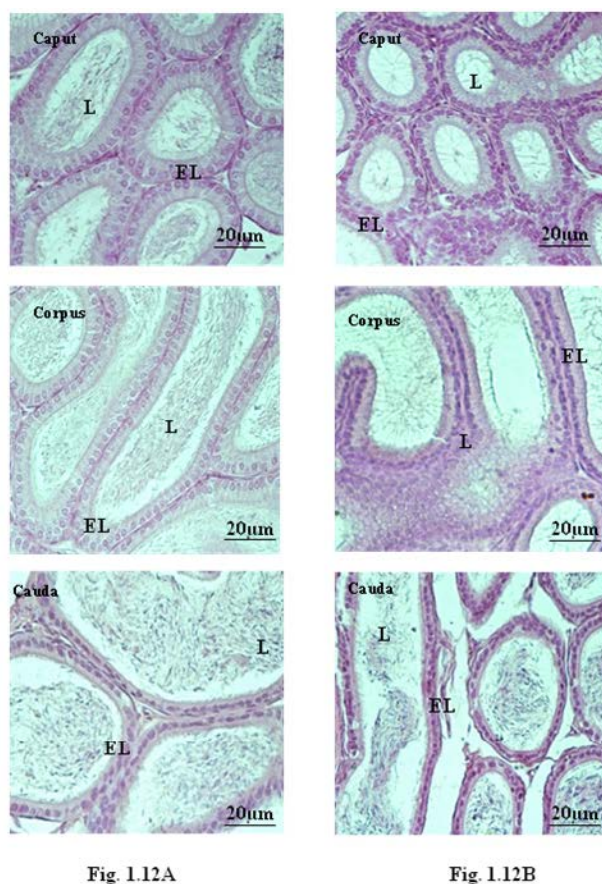


Figure 12. A. T.S. of epididymis (Caput, Corpus and Cauda) of *M. terricolor* following saline injections. Note the lumina filled with spermatozoa. EL: Epithelial lining, L: Lumen.

B. T.S. of the epididymis (Caput, Corpus and Cauda) of *M. terricolor* following 15 days of dexamethasone injections. Note the lumina devoid of spermatozoa containing sperm debris and few exfoliated germ cells. EL: Epithelial lining, L: Lumen.

spermatogenic activity with successive stages of transformation from spermatogonia to spermatozoa (Figure 10A). Dexamethasone treatment induced marked regressive histological changes in the seminiferous tubules as evidenced by thinning of tunica propria, loosening of the germ cells and loss of spermatocytes. Lumina of the majority of the tubules were devoid of spermatozoa, containing sperm debris and only few stages of germ cells (Figure 10B and C).

The caput, corpus and cauda epididymides of the control mice showed normal histological features (Figure 12A). In mice treated with dexamethasone, the epididymal lumina contained debris of spermatozoa and few or many exfoliated germ cells (Figure 12B).

The seminal vesicle of the control group showed normal histological features of abundant secretion in the wide lumen (Figure 11A). By contrast, seminal vesicle of mice treated with dexamethasone showed marked degenerative changes, as indicated by excessive inward ramification of epithelial lining and scanty secretion in the reduced lumen (Figure 11B).

4. Discussion

The suppressive effect of induced-stress has been reported in female *M. terricolor*³. The present experiment was carried out to study the effects of synthetic glucocorticoid dexamethasone on the reproductive functions of male *M. terricolor* during its reproductively active phase. The suppressive effects of dexamethasone treatment on the reproductive functions of mice were reflected in reduced weights of gonads and accessory sex organs accompanied by significant reduction in biochemical constituents like epididymal sialic acid, seminal vesicular fructose and plasma testosterone. However, the levels of plasma corticosterone and testicular cholesterol increased significantly following dexamethasone treatment. Increased gonadal cholesterol indicates low steroidogenesis since cholesterol is the precursor for steroidogenesis.

Whenever an animal is confronted with a stressful situation, the increased level of glucocorticoid leads to hyperactivation of HPA axis. The different components of HPA axis, consequently, act on HPG axis to suppress the secretion of GnRH, LH, and gonadal steroids, thereby the reproductive functions. Maeda and Tsukamura²¹, very nicely explained the logic behind this suppression of reproduction during stress; they say that the suppres-

sion of reproductive activities during stressful condition is to give priority to survival of the individual rather than propagation of the species.

In *M. terricolor* dexamethasone injections led to a reduction in the process of steroidogenesis as evident by the increased testicular cholesterol and decreased level of plasma testosterone. This reduction in the plasma testosterone might have led to suppression of the spermatogenic activity as exhibited by the histological sections of the testis. The reduction in the weights, biochemical constituents and degenerative changes in the histology of the epididymis and seminal vesicles can also be attributed to the reduced level of testosterone following dexamethasone treatment since these accessory sex organs are androgen dependent^{22,27}. Our results derive support from earlier studies which have also reported reduced testosterone level following glucocorticoid treatment and consequent inhibitory effects on male reproduction^{17,24,25,31,35}. Blood testosterone level and consequently acrosin activity was found to be reduced in Chios rams following dexamethasone injections³⁵. Orazizadeh *et al.*,²⁴ reported in mice that dexamethasone induces histopathological alterations such as epithelial vacuolization, atrophy and reduction in testicular spermatozoid. Yazawa *et al.*,^{36,37} demonstrated that stress and dexamethasone administration induced testicular germ cell apoptosis in rats and found it to be associated with increase in serum corticosterone and decline in serum testosterone.

Different workers have proposed different mechanisms for the action of this synthetic glucocorticoid. The Hypothalamo-Pituitary-Gonadal (HPG) axis can be affected at three levels by the glucocorticoids. One of the levels is brain, which will affect the neurosecretion. The second level is pituitary which will lead to altered secretion of gonadotropin. The third level, gonad, affects gonadal secretion²⁸.

Several studies have reported the suppression of LH secretion following glucocorticoid administration in different animals. This LH suppression consequently led to suppression of gonadal action^{1,5,12,13,17,23,25,29,30,31}. So there is a possibility that in *M. terricolor* dexamethasone treatment might have inhibited LH secretion by decreasing responsiveness of the pituitary to GnRH or it might be a direct action on the pituitary itself. Baldwin *et al.*,⁶ and D'Agostino *et al.*¹¹, suggested the direct action of corticosteroids on gonadotropin release at the level of anterior pituitary. Suter and Schwartz³³ and Kamel and Kubajak¹⁸ demonstrated that corticosterone and cortisol can sup-

press GnRH as well as basal LH release from rat anterior pituitary cells incubated *in vitro*. One of the mechanisms adopted by corticosteroids may also be modulation of opioid and catecholaminergic systems in the hypothalamus and higher brain centers^{10,19,34}. A direct inhibitory effect of corticosteroids on coupling of GnRH receptors to second-messenger systems, leading to impaired release of LH in response to GnRH stimulus is also reported by Kamel and Kubajak¹⁸. In the present study the reduced gonadotropin might have affected the secretion of gonadal steroids. Specific measurement of LH is required to support this inference but this measurement was not done due to lack of specific antibody.

M. terricolor is a wild and seasonally breeding rodent⁴. Therefore, it has to face various stressors and environmental challenges for its perpetuation. The, induced-stress following administration of dexamethasone, a synthetic, glucocorticoid, led to inhibition or suppression of reproductive functions of this tiny rodent. Thus, from the findings of this study, we infer that during stress the HPA axis of this rodent becomes active leading to inhibition of reproductive functions.

5. Acknowledgments

The authors thank the University Grants Commission, New Delhi, for financial support to Ms. Sweta Arora in the form of Research Fellowship. The instruments subsidiary award from Alexander von Humboldt Foundation, Bonn, Germany, to Prof. C. Haldar is gratefully acknowledged.

6. References

- Almeida SA, Anselmo-Franci JA, Silva AAR, Carvalho TL. Chronic intermittent immobilization of male rats throughout sexual development: A stress protocol. *Exp Physiol*. 1998; 83:701–4. <https://doi.org/10.1113/expphysiol.1998.sp004151> PMID:9793790
- Aminoff D. Methods for the quantitative estimation of N-acetylneuraminic acid and their application to hydrolysates of sialomucoids. *Biochem J*. 1961; 81:384–92. <https://doi.org/10.1042/bj0810384> PMID:13860975 PMCid:PMC1243351
- Arora S, Singh P, Haldar C. Influence of glucocorticoid-induced stress on reproductive function in female *Mus terricolor* during reproductively active phase. *J Endocrinol Reprod*. 2012; 16(2):47–56.
- Arora S, Basu P, Singh P, Haldar C. Reproductive seasonality in the Indian pygmy field mouse, *Mus terricolor*. *Biol Rhythm Res*. 2015; 46(1):13–32. <https://doi.org/10.1080/09291016.2014.939443>
- Baldwin DM. Effects of glucocorticoids on estrogen-dependent LH release in the ovariectomized rat and on gonadotropin secretion in the intact female rat. *Endocrinology*. 1979; 105:120–78. <https://doi.org/10.1210/endo-105-1-120> PMID:376294
- Baldwin DM, Srivastava P, Krummen LA. Differential actions of corticosterone on luteinizing hormone and follicle-stimulating hormone biosynthesis and release in cultured rat anterior pituitary cells: interactions with estradiol. *Biol Reprod*. 1991; 44:1040–50. <https://doi.org/10.1095/biolreprod44.6.1040> PMID:1908329
- Bardhan A, Sharma T. Meiosis and speciation: A study in a speciating *Mus terricolor* complex. *J Genet*. 2000; 79:105–11. <https://doi.org/10.1007/BF02715858>
- Basu P, Singaravel M, Haldar C. L-5-hydroxytryptophan resets the circadian locomotor activity rhythm of the nocturnal Indian pygmy field mouse *Mus terricolor*. *Naturwissenschaften*. 2012; 99:233–9. <https://doi.org/10.1007/s00114-012-0893-5> PMID:22331255
- Basu P, Singaravel M. Accurate and precise circadian locomotor activity rhythms in male and female Indian pygmy field mice, *Mus terricolor*. *Biol Rhythm Res*. 2012; 44:531–9. <https://doi.org/10.1080/09291016.2012.721587>
- Brann DW, Mahesh VB. Role of corticosteroids in female reproduction. *FASEB J*. 1991; 5:2691–8. PMID:1655548
- D'Agastino J, Valadka RJ, Schwartz NB. Differential effects of *in vitro* glucocorticoids on luteinizing hormone and follicle stimulating hormone: dependence on sex of pituitary donor. *Endocrinology* 1990; 127:891–9. <https://doi.org/10.1210/endo-127-2-891> PMID:2115436
- Dubey AK, Plant TM. A suppression of gonadotropin secretion by cortisol in castrated rhesus monkeys (*Macaca mulatta*) mediated by the interruption of hypothalamic gonadotropin-releasing hormone. *Biol Reprod*. 1985; 33:423–31. <https://doi.org/10.1095/biolreprod33.2.423>
- Gao HB, Tong MH, Hu YQ, You HY, Guo QS, Ge RS, Hardy MP. Mechanisms of glucocorticoid-induced Leydig cell apoptosis. *Mol Cell Endocrinol*. 2003; 199:153–63. [https://doi.org/10.1016/S0303-7207\(02\)00290-3](https://doi.org/10.1016/S0303-7207(02)00290-3)
- Gupta S, Haldar C. Physiological crosstalk between melatonin and glucocorticoid receptor modulates T cell mediated immune responses in a wild tropical rodent, *Funambulus pennanti*. *J Steroid Biochem Mol Biol*. 2012; 134:23–36. <https://doi.org/10.1016/j.jsbmb.2012.09.013> PMID:23059469
- Gur S, Bozkurt T, Turk G. Short term effects of dexamethasone on hyaluronidase activity and sperm characteristics in rams. *Anim Reprod Sci*. 2005; 90:255–63. <https://doi.org/10.1016/j.anireprosci.2005.01.021> PMID:16298273

16. Haldar C, Rai S, Singh, SS. Melatonin blocks dexamethasone-induced immune suppression in a seasonally breeding rodent Indian palm squirrel, *Funambulus pennanti*. *Steroids*. 2004; 69:367–77. <https://doi.org/10.1016/j.steroids.2004.03.006> PMID:15219786
17. Hales DB, Payne AH. Glucocorticoid-mediated repression of P450scc mRNA and de novo synthesis in cultured Leydig cells. *Endocrinology*. 1989; 124:2099–104. <https://doi.org/10.1210/endo-124-5-2099> PMID:2539967
18. Kamel F, Kubajak CL. Modulation of gonadotropin secretion by corticosterone: Interaction with gonadal steroids and mechanism of action. *Endocrinology*. 1987; 121:561–8. <https://doi.org/10.1210/endo-121-2-561> PMID:3109884
19. Kizer JS, Palkovits M, Zivin J, Brownstein M, Saavedra J, Kopin I. The effect of endocrinological manipulations on tyrosine hydroxylase and dopamine-13-hydroxylase activities in individual hypothalamic nuclei of the adult male rat. *Endocrinology*. 1974; 95:799–804. <https://doi.org/10.1210/endo-95-3-799> PMID:4153111
20. Lindner HR, Mann T. Relationship between the content of androgenic steroids in the testes and the secretory activity of the seminal vesicles in the bull. *J Endocrinol*. 1960; 21:341–60. <https://doi.org/10.1677/joe.0.0210341>
21. Maeda K, Tsukamura H. The impact of stress on reproduction: Are glucocorticoids inhibitory or protective to gonadotropin secretion? *Endocrinology*. 2006; 147:1085–6. <https://doi.org/10.1210/en.2005-1523> PMID:16481480
22. Mann T. Secretory function of the prostate, seminal vesicle and other male accessory organs of reproduction. *J Reprod Fertil*. 1974; 37:179–88. <https://doi.org/10.1530/jrf.0.0370179> PMID:4593605
23. Norman RL. Effects of corticotropin-releasing hormone on luteinizing hormone, testosterone, and cortisol secretion in intact male Rhesus macaques. *Biol Reprod*. 1993; 49:148–53. <https://doi.org/10.1095/biolreprod49.1.148> PMID:8353181
24. Orazizadeh M, Khorsandi LS, Hashemitabar M. Toxic effects of dexamethasone on mouse testicular germ cells. *Andrologia*. 2010; 42:247–53. <https://doi.org/10.1111/j.1439-0272.2009.00985.x> PMID:20629648
25. Orr TE, Taylor MF, Bhattacharyya AK, Collins DC, Mann DR. Acute immobilization stress disrupts testicular steroidogenesis in adult male rats by inhibiting the activities of 17 α -hydroxylase and 17,20-lyase without affecting the binding of LH/hCG receptors. *J Androl*. 1994; 15:302–8. PMID:7982797
26. Payne AH, Sha LL. Multiple mechanisms for regulation of 3 β -hydroxysteroid dehydrogenase/D5-D4-isomerase, 17 α -hydroxylase/C17-20 lyase cytochrome P450, and cholesterol sidechain cleavage cytochrome P450 messenger ribonucleic acid levels in primary cultures of mouse Leydig cells. *Endocrinology*. 1991; 129:1429–35. <https://doi.org/10.1210/endo-129-3-1429> PMID:1874181
27. Rajalakshmi M. Physiology of the epididymis and spermatozoa. *J Biosci*. 1985; 7:191–5. <https://doi.org/10.1007/BF02703587>
28. Rivier C, Rivest S. Effect of stress on the activity of hypothalamic-pituitary-gonadal axis peripheral and central mechanisms. *Biol Reprod*. 1991; 45:523–32. <https://doi.org/10.1095/biolreprod45.4.523>
29. Rosen I, Jameel ML, Barkan AL. Dexamethasone suppresses gonadotropin releasing hormone (GnRH) secretion and has a pituitary effects in male rats: Differential regulation of GnRH receptor and gonadotropin responses to GnRH. *Endocrinology*. 1988; 122:2873–80. <https://doi.org/10.1210/endo-122-6-2873> PMID:2836177
30. Saketos M, Sharma N, Santoro NF. Suppression of the hypothalamic-pituitary-ovarian axis in normal women by glucocorticoids. *Biol Reprod*. 1993; 49:1270–6. <https://doi.org/10.1095/biolreprod49.6.1270> PMID:8286608
31. Sapolsky RM. Stress, the aging brain, and the mechanisms of neuron death. Cambridge: MIT Press; 1992. PMID:PMC50488
32. Singh S, Cheong N, Narayan G, Sharma T. Burrow characteristics of the co-existing sibling species *Mus booduga* and *Mus terricolor* and the genetic basis of adaptation to hypoxic/hypercapnic stress. *BMC Ecol*. 2009; 9:6. <https://doi.org/10.1186/1472-6785-9-6> PMID:19358716 PMID:PMC2678975
33. Suter DE, Schwartz NB. Effects of glucocorticoids on secretion of luteinizing hormone and follicle stimulating hormone by female rat pituitary cells in vitro. *Endocrinology*. 1985; 117:849–54. <https://doi.org/10.1210/endo-117-3-849> PMID:3926469
34. Tong V, Couet J, Simard J, Pelletier G. Glucocorticoid regulation of proopiomelanocortin mRNA levels in rat arcuate nucleus. *Mol Cell Neurosci*. 1990; 1:78–83. [https://doi.org/10.1016/1044-7431\(90\)90043-4](https://doi.org/10.1016/1044-7431(90)90043-4)
35. Tsantarliotou MP, Taitzoglou IA, Goulas P, Kokolis NA. Dexamethasone reduces acrosin activity of ram spermatozoa. *Andrologia*. 2002; 34 (3):188–93. <https://doi.org/10.1046/j.1439-0272.2002.00491.x> PMID:12059816
36. Yazawa H, Sasagawa I, Ishigooka M, Nakada T. Effect of immobilization stress on testicular germ cell apoptosis in rats. *Human Reprod*. 1999; 14:1806–10. <https://doi.org/10.1093/humrep/14.7.1806> PMID:10402394
37. Yazawa H, Sasagawa I, Nakada T. Apoptosis of testicular germ cells induced by exogenous glucocorticoid in rats. *Human Reprod*. 2000; 15(9):1917–20. <https://doi.org/10.1093/humrep/15.9.1917> PMID:10966986