

Histology of parathyroid gland of the snake *Oligodon arnensis* (Shaw)

Anita S. Jadhav¹ and A.S. Padgaonkar²

¹Zoology Department, ICLES' M.J. College, Vashi, Navi Mumbai, Maharashtra, India

²Zoology Department, BNN College, Bhiwandi, Maharashtra, India

Summary

The snake *Oligodon arnensis* possesses two pairs of parathyroid glands. The rostral parathyroids (rPTG) are located at the bifurcation of the carotid artery, behind the angle of the jaw. The caudal parathyroids (cPTG) are located in the thyro-thymic region. The parathyroid gland is surrounded by a connective tissue capsule, and composed of cell cords of a single type of cell. Oxyphil cells are absent. The gland is profusely supplied with blood vessels.

Keywords: Parathyroid gland, *Oligodon arnensis*, snake.

Introduction

There are few reports on the parathyroid glands of reptiles, especially snakes. The presence of additional small gland has been occasionally reported, and these are regarded as accessory parathyroid glands (Singh and Kar, 1983a, b; Padgaonkar et al., 1992). Hence, we undertook studies on the parathyroid gland of ophidian species from five different habitats, namely terrestrial (Padgaonkar and Warbhuwan, 1990-1991), arboreal (Warbhuwan and Padgaonkar, 2002), freshwater (Warbhuwan and Padgaonkar, 1993), estuarine (Padgaonkar et al., 1992; Kagwade and Padgaonkar, 1992), and marine (Warbhuwan and Padgaonkar, 2001, 2002; Jadhav and Padgaonkar, 2007). Here in we extended our observation to the terrestrial snake, *Oligodon arnensis*.

Materials and Methods

Specimens of both sexes of *Oligodon arnensis* were procured locally from the suburbs of Mumbai. Specimens were dissected under Nembutal anesthesia (2.5mg/100g body wt). Looking through a dissecting microscope, the parathyroid glands were traced and removed surgically for fixation in Bouin's fluid. After routine dehydration and paraffin embedding, 5 µm thick sections were cut and stained with hematoxylin and phloxin.

Observations

Oligodon arnensis possesses two pair of parathyroid glands (PTGs), one rostral pair and one caudal pair. The rostral parathyroids (rPTG) are located one on either side near the bifurcation of the carotid artery, behind the angle of the jaw. The caudal parathyroids (cPTG) are located in the thyro-thymic region (Fig. 1, 2). These glands are spheroidal in shape and whitish translucent in appearance. All the four glands are of the same size.

Accessory parathyroid tissue is absent. Each parathyroid gland is surrounded by a connective tissue capsule. The gland is composed of cell cords, and all cells are chief cells. The cell boundaries are inconspicuous. The cells possess very little cytoplasm. The nuclei are oval or round. Oxyphil cells are absent. The gland has rich blood capillaries and sinusoids.

Discussion

The presence of two pairs of parathyroid glands in *Oligodon arnensis* matches the observation made in the other ophidian species (Saint-Remy and Prenant, 1904; Harrison and Denning, 1929; Neudeck, 1969; Clark, 1970; Oguro, 1970, 1972; Singh and Kar 1983a, b, 1984; Alcobandas, 1989; Padgaonkar and Warbhuwan, 1991, 1993; Padgaonkar et al., 1992; Kagwade and Padgaonkar, 1992; Warbhuwan and Padgaonkar, 2002; Jadhav and Padgaonkar, 2007). The location of the gland agrees with that reported by Herdson (Cited by Singh and Kar, 1984). The accessory parathyroid tissue reported to be present in some ophidian species (Clark, 1971; Singh and Kar, 1983a, b; Padgaonkar et al., 1992) is absent in this snake. The histological features of parathyroid gland of *Oligodon arnensis* has revealed connective tissue capsule, blood capillaries and cell cords of single type of cells homologous with the chief cells of mammalian parathyroids. Oxyphil cells are absent. The histological features of the parathyroid gland compare favourably well with those reported for the parathyroid of other ophidian species (Singh and Kar, 1983a, b, 1984; Padgaonkar and Warbhuwan, 1990-1991; Padgaonkar et al., 1992; Warbhuwan and Padgaonkar, 2001, 2002; Jadhav and Padgaonkar, 2007). The parathyroid glands of some snakes have been shown to contain some follicles (Clark, 1971; Oguro, 1970, 1972;

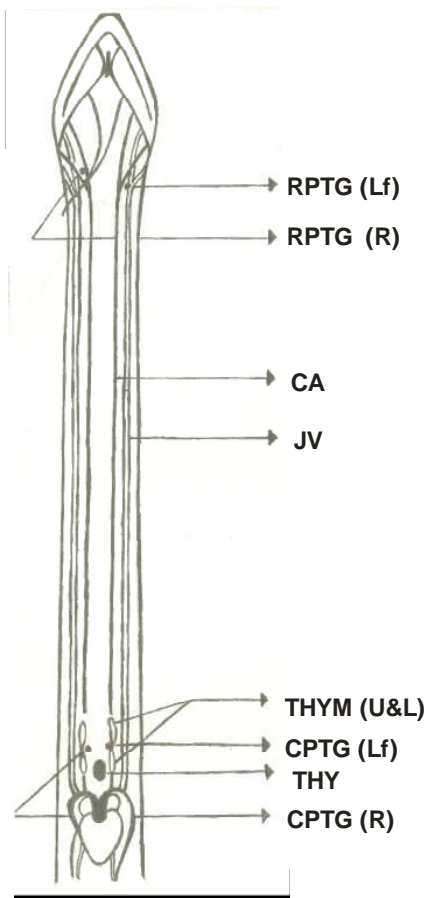
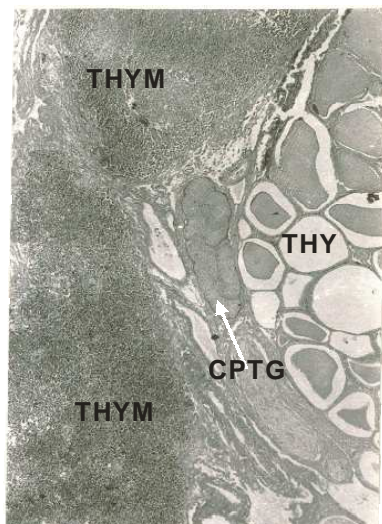


Fig 1 : Diagram showing the anatomical position of the endocrine gland of the snake *Oligodon arnensis*.

CA, carotid artery; JV, jugular vein



CPTG - Parathyroid gland
 THYM - Thymus
 THY - Thyroid

Fig 2 : Photomicrograph of the caudal parathyroid of the snake X 100

Singh and Kar, 1983a), while the parathyroids of other species contain large vesicles (Singh and Kar, 1983a, 1984). Follicles and vesicles are absent in the *Oligodon arnensis*. Thus, the parathyroids of *Oligodon arnensis* have features similar to other snakes in general, but absence of accessory parathyroid tissue and follicles/vesicles make this species a little different.

References

Alcobandas M (1989) VII Recherches sur le metabolisme Phosphocalcique au cours du cyclemmanuel et du cycle de la reproduction chez un Reptile *Vipera apis* (L). Ph.D. Thesis, University of Paris.

Clark NB (1970) The parathyroid. In: C. Gan T.S.,Parson (Eds) *The Biology of Reptilia*. Vol.3, Pp 235-262. Academic Press, New York.

Clark NB (1971) Function of the parathyroid gland in the snake *Thamnophis sirtalis*. *J Exp Zool* 178:9-14

Harrisson BM, Denning NE (1929) Embryonic development of the pharyngeal region in *Thamnophis radix*. *Am Zool* 9:1083-1084.

Jadhav AS, Padgaonkar AS (2007) Histology of parathyroid glands in the estuarine snake *Enhydrina schistose* (Daudin). *Trends Life Sci* 22:113-116.

Neudeck LD (1969) Histological investigation of snake parathyroid glands. *Am.Zool* 9:1083-1084.

Oguro C (1970) Parathyroid gland of the snake *Elaphe quadrivirgate*, with special reference to parathyroidectomy. *Gen Comp Endocrinol* 15: 313-319.

Oguro C (1972) Parathyroidectomy in the snake *Rhabdophis tigrinus tigrinus*. *Gen Comp Endocrinol* 18:412-415.

Padgaonkar AS, Warbhuwan AP (1991) Parathyroids and ultimobranchial glands of the snake *Argyrogena fasciolatus* (Shaw). *Biol Struct Morphogen* 3:97-100.

Padgaonkar AS, Kagwade MV (1992) Parathyroids and ultimobranchial glands of the smooth water snake *Enhydris enhydris* (Schneider). *Biol Struct Morphogen* 4:171-173.

Padgaonkar AS, Kagwade MV, Warbhuwan AP (1992) Parathyroids and ultimobranchial glands of the

- snake *Cerberus rhychops* (Schneider). *Gen Comp Endocrinol* 86: 395-397.
- Saint-Remy G, Prenant A (1904) Recherches sur le développement des dérivés branchiaux chez les sauriens et les ophidiens. *Arch Biol Paris* 20:142-216.
- Singh R, Kar I (1983a) Parathyroids and ultimobranchial glands of the sand boa *Eryx johnii* (Daudin). *Gen Comp Endocrinol* 51:66-70.
- Singh R, Kar I (1983b) Parathyroids and ultimobranchial glands of the fresh-water snake *Natrix piscator* (Schneider). *Gen Comp Endocrinol* 51:71-76.
- Singh R, Kar I (1984) Parathyroid gland structure in some species of Squamata. *Zool J Anat* 112:491-498.
- Warbhuwan AP, Padgaonkar AS (1993) Parathyroid and ultimobranchial of the fresh-water snake *Amphiesma stolata* (Linn). *Bull Int Zool Acad Sin* 32:157-161.
- Warbhuwan AP, Padgaonkar AS (2001) Occurrence of six parathyroid glands in the estuarine snake *Acrochordus granulatus* (Schneider). *Trends Life Sci* 16:113-117.
- Warbhuwan AP, Padgaonkar AS (2002) Parathyroid and Ultimobranchial of the marine snake *Hydrophis cyanocinctus* (Daudin). *Trends Life Sci* 17:33-36.
- Warbhuwan AP, Padgaonkar AS (2002) Histomorphological studies on the parathyroid and ultimobranchial gland of the green tree snake *Ahaetulla nasutus* (Lacepede). *Trends Life Sci* 17:45-47.