

HYPOTHYROIDISM AND SPECIFIC PHASE RELATION OF CIRCADIAN SEROTONERGIC AND DOPAMINERGIC OSCILLATORS IN GONADAL DEVELOPMENT OF JAPANESE QUAIL (*Coturnix coturnix japonica*)

TIWARI A C AND CHATURVEDI C M

Department of Zoology, Banaras Hindu University, Varanasi - 221 005, India.

SUMMARY

Sexually mature male Japanese quail were used to study thyroid-gonad relationship and reproductive effects of temporal phase relation (8-hr and 12-hr) of circadian serotonergic and dopaminergic oscillators in hypothyroidic condition. To induce hypothyroidism, birds were injected with an antithyroid drug (2-thiouracil - TU). Quail were divided into six groups. First group quail received two daily injections of normal saline (Control), second group quail received one daily injection of 2-Thiouracil (an antithyroid drug- TU group), third group received serotonin precursor (5-Hydroxytryptophan, 5-HTP) at 5.00 A.M. and dopamine precursor (L-dihydroxyphenylalanine, L-DOPA) at 1.00 P.M. (8-hr group), fourth group received 5-HTP and L-DOPA injections at the interval of 8 hours as in group third as well as one daily injection of TU (8-hr + TU group), fifth group received daily injections of L-DOPA 12 hours after the injections of 5-HTP (12-hr group) and sixth group received 5-HTP and L-DOPA injections at the interval of 12 hour as well as one daily injections of TU (12-hr +TU group). Quail received daily injections of 5-HTP and L-DOPA 8 hours and 12 hours apart respectively over a period of eleven days only. However, TU injections alone or along with 5-HTP and L-DOPA continued till the termination of study (i.e. 7 weeks). Findings indicate that cloacal gland volume; testicular activity and testosterone level along with thyroxin was significantly low in TU treated quail compared to control suggesting parallel thyroid-gonad relationship in this species. Quail of both 8-hr and 8-hr+TU treated group also showed reproductively regressed condition. On the other hand, testes of 12-hr quail showed full breeding condition, which was also maintained in 12-hr +TU quail. Obviously, gonadostimulatory effect of 12-hr temporal phase relation of 5-HTP and L-DOPA injections were maintained even in hypothyroidic condition suggesting that inhibitory effect of TU on gonadal development was overpowered by stimulatory effect of 12-hr phase relation. It is concluded that gonadal growth in Japanese quail requires the presence of optimal level of thyroid hormones and 12- hr temporal relation of circadian serotonergic and dopaminergic activities is a potent stimulator of neuroendocrine gonadal axis even in hypothyroidic condition, while 8-hr temporal phase relation of these neurotransmitter precursors inhibits gonadal activity. It is suggested that circadian temporal phase relation of neurotransmitters may modulate the activity of neuroendocrine axis.

Key words: 5-HTP, L-DOPA, Hypothyroidism, Thiouracil, Photosensitivity.

INTRODUCTION

Initial studies showed that thyroidectomy inhibits normal gonadal maturation in chickens and ducks (1) but contrarily it was also reported to prevent gonadal regression (2). Thereafter, effects of surgical thyroidectomy on annual reproduction have been studied extensively in subtropical birds along with

* Address for correspondence: Prof. (Mrs.) C.M. Chaturvedi, Department of Zoology, Molecular Endocrinology Lab, Banaras Hindu University, Varanasi – 221005. (UP), India. mohini@banaras.ernet.in
Tele Fax: +91 542 2368323.

seasonal variations in thyroid function of few species (3-8). Thyroidectomy increased gonadal growth in spotted munia, lal munia and female weaver bird (9-11) while gonadal regression was observed in male weaver bird, red vented bulbul, house sparrow, common myna and few others subtropical species as in duck and fowl (12-16). In view of above apparent diverse effects it is clearly evident that thyroid –gonad relationship varies from species to species (9, 17). A number of studies reported from Chaturvedi's group strongly indicate the effect of specific phase relation of serotonergic and dopaminergic oscillators on gonadal function of birds (18-23). In general L-dihydroxyphenylalanine (L-DOPA, a dopamine precursor) given 8 hours after the injection of 5-hydroxytryptophan (5-HTP, a serotonin precursor) induces gonadal inhibition while 12-hr relation between these two injections given over a period of 11-13 days leads to gonadal stimulation. Synchronized release of dopamine and serotonin in the hypothalamus of rat (24) supports the hypothesis that temporal phase relation of these neurotransmitters affects neuroendocrine axis. The effects of thyroid hormone and / or thyroidectomy on reproductive functions (stimulatory and/or inhibitory) can be mimicked by daily injections of 5-HTP and L-DOPA, given at specific temporal relations. In those species having parallel thyroid-gonad relationship viz. red headed bunting and male weaver bird, thyroidectomy as well as administration of 5-HTP and L-DOPA at the interval of 8 hours leads to suppression of gonadal development and hyperthyroidism and 12-hr relation of these precursor drugs induces gonadal growth (18,25). Thyroid functions have also been implicated in the development of photorefractoriness in birds held on long day lengths (26) and normal thyroid function is essential to develop relative photorefractoriness (27). Studies indicate that Japanese quail does not become refractory to long day length in classical sense but exhibit modified refractoriness i.e. relative refractoriness. Being an important metabolic hormone and essential for development of photorefractoriness, thyroid hormone is also reported to be essential for the maintenance of circadian expression and this permissive action of thyroxin may relate to its inhibitory effect on MAO (Monoamine oxidase) activity (28,29) hence activates serotonin (30). In view of thyroid-gonad relationship in birds and different effects of 8-hr and 12-hr relation of circadian serotonergic and dopaminergic activity on reproductive system, present study was undertaken. The aim was to study the role of temporal phase relation of neural oscillators in the reproductive regulation of hypothyroidic quail.

MATERIALS AND METHODS

Sexually mature (6 weeks old) male Japanese quail obtained from Central Avian Research Institute (CARI), Izatnagar, Bareilly (UP), were maintained in lightproof photoperiodic chambers and provided with commercial poultry feed and water *ad libitum*. After acclimatization to laboratory condition, length and width of cloacal gland was measured with dial calipers (i.e. observation before treatment) and volume was calculated using the formula $4/3\pi ab^2$ (where $a=1/2$ of long axis and $b=1/2$ of short axis). Thereafter, quail were divided into following six groups (n=6 in each group).

GROUP I: (Control) Received two daily injections of normal saline

- GROUP II: (TU) Received one daily injection of 2-Thiouracil, an antithyroid drug (4 mg/ 100 gm body weight)
- GROUP III: (8-hr) Received daily injection of 5- HTP (5-hydroxytryptoph 5mg/100gm body weight) at 5:00 A.M. and L-DOPA (L-dihydroxyphenylalanine) at 1:00 P.M. i.e. at the interval of 8 hours
- GROUP IV: (8-hr+TU) Received 5-HTP and L-DOPA injections at the interval of 8 hour as in group III as well as one daily injection of TU.
- GROUP V: (12-hr) Received 5-HTP injections daily at 5:00 A.M. and L-DOPA at 5:00 P.M. i.e. at the interval of 12 hours.

GROUP VI: (12-hr+TU) Received 5-HTP and L-DOPA injections at the interval of 12 hours as in group V as well as one daily injection of TU Quail of each group were maintained in individual wire net cages. During the period of treatment / injections, quail were maintained in LL (continuous condition of light) to avoid possible photoperiodic interference with neuroendocrine entrainment by drug injections. All the injections were given intraperitoneally (i.p.) in 0.1 ml of normal saline solution. 5-HTP and L-DOPA injections were given for 11 days only but TU injections were continued throughout the period of study (i.e. from the day one, along with 5-HTP and L-DOPA injections and even after the discontinuation of these precursor drug injections). On 12th day cloacal gland volume was recorded (i.e. observation after treatment) and all the groups were transferred in long day length (LD 16:8) and weekly observations were taken. At the termination of experiment (7 weeks following 5-HTP and L-DOPA treatment), birds were sacrificed by decapitation; testes were removed, measured, weighed and fixed in Bouin's fluid to be processed for histological studies. Blood was collected in heparinized tube; plasma was separated by centrifugation and stored in -20°C until assayed for testosterone and thyroxin level using commercial RIA kits. Data were analyzed by Student's 't' test.

RESULTS

Cloacal gland volume of quail of different groups varied after the treatment period (11 days) of 5-HTP and L-DOPA, when compared to initial cloacal gland volume (before treatment). It was observed that compared to control, TU, 8-hr and 8-hr+TU treated group quail showed significant decrease in their cloacal gland volume which was maintained till the termination of the study. On the other hand, both 12-hr and 12-hr+TU quail showed increased volume of cloacal gland. This increase compared to control, was evident immediately after the termination /11 days of 5-HTP and L-DOPA treatment and was maintained throughout the period of study i.e. upto 7 weeks when TU injections were continued (Fig.1). Similar trend of effect was noted in testicular volume (Fig.2) and weight (Fig.3) when observed at the termination of study. As expected, thyroxin level was significantly low in TU treated quail, but, it was also low in 8-hr and high in 12-hr quail compared to control (Fig.4). Plasma testosterone concentration also showed similar pattern (Fig. 5)

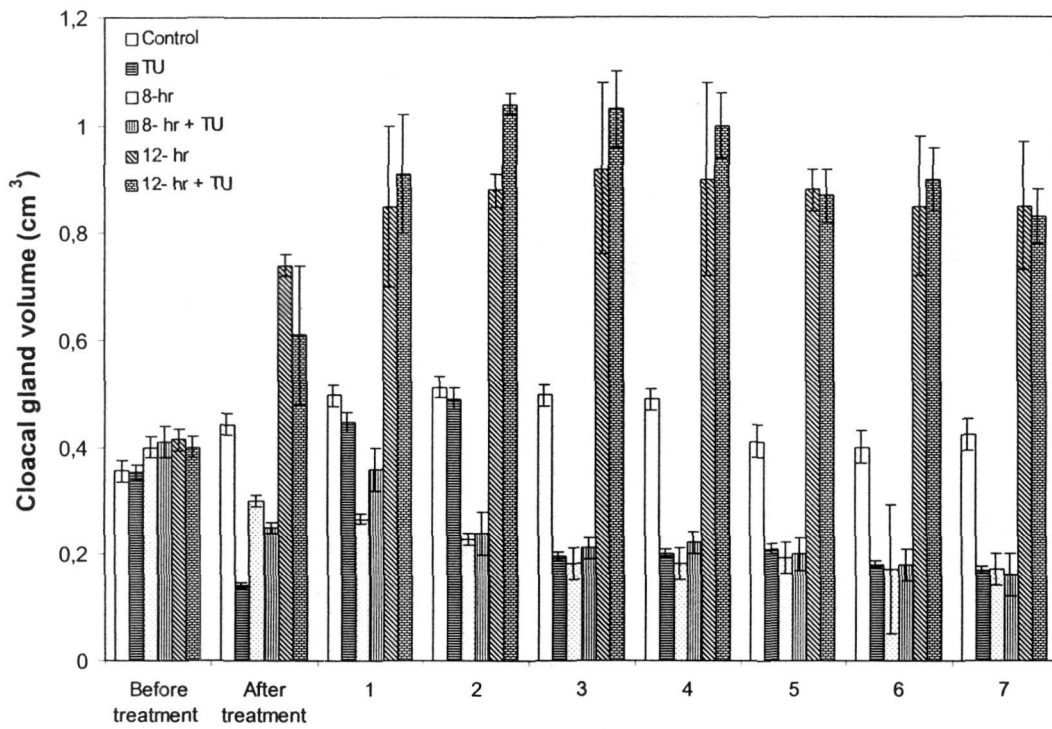


Fig.1. Effect of antithyroid drug 2-thiouracil (TU), 12-hr and 8-hr temporal phase relationship of 5-HTP and L-DOPA on cloacal gland volume of Japanese quail.
 * $p < 0.05$, ** $p < 0.01$, significance of difference from control

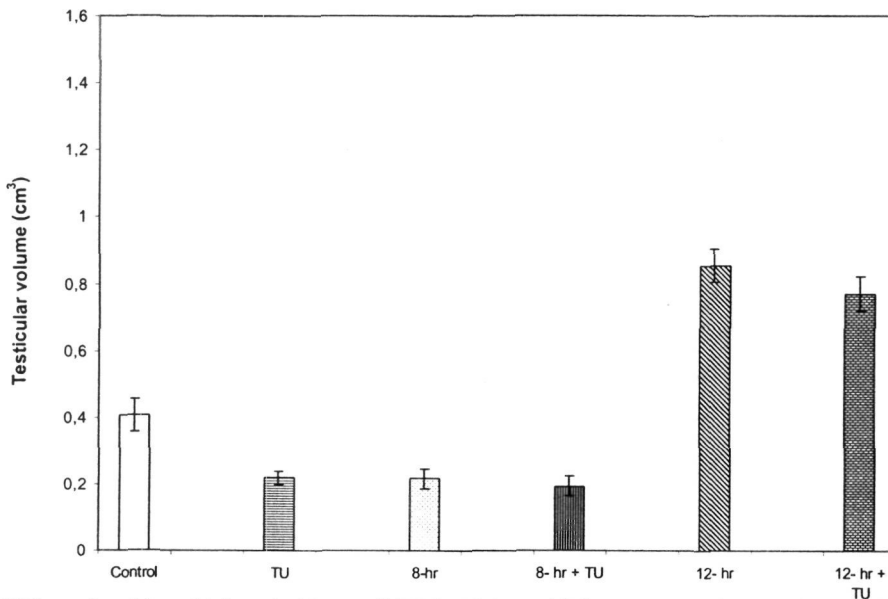


Fig.2. Effect of antithyroid drug 2-thiouracil (TU), 12-hr and 8-hr temporal phase relationship of 5-HTP and L-DOPA on testicular volume of Japanese quail
 * $p < 0.05$, ** $p < 0.01$ significance of difference from control

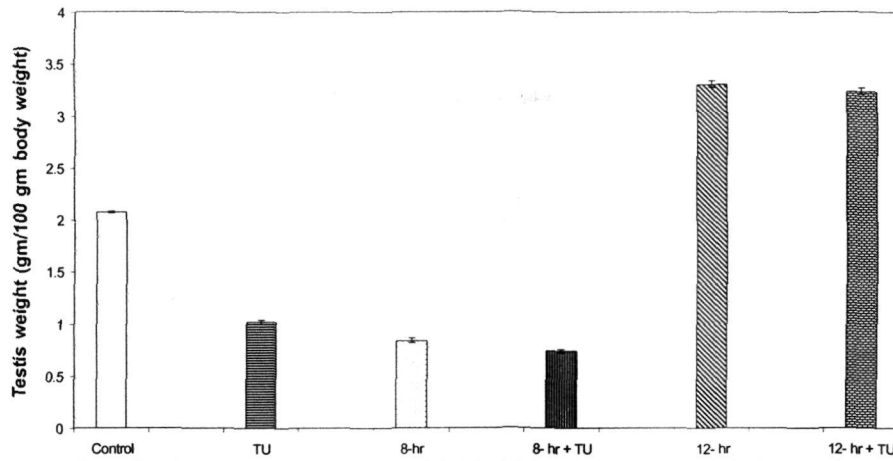


Fig.3. Effect of antithyroid drug 2-thiouracil (TU), 12-hr and 8-hr temporal phase relationship of 5-HTP and L-DOPA on testes weight of Japanese quail

* $p < 0.05$, *** $p < 0.001$ significance of difference from control

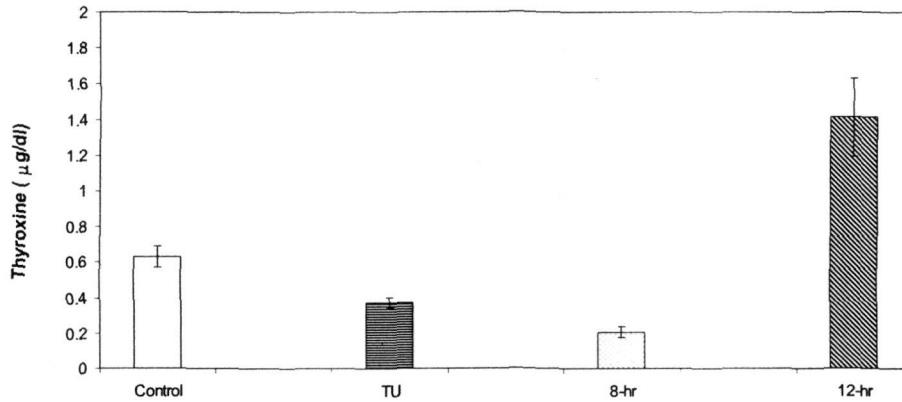


Fig.4. Effect of antithyroid drug 2-thiouracil (TU), 12-hr and 8-hr temporal phase relationship of 5-HTP and L-DOPA on plasma thyroxine level of Japanese quail.

* $p < 0.05$, ** $p < 0.01$ significance of difference from control

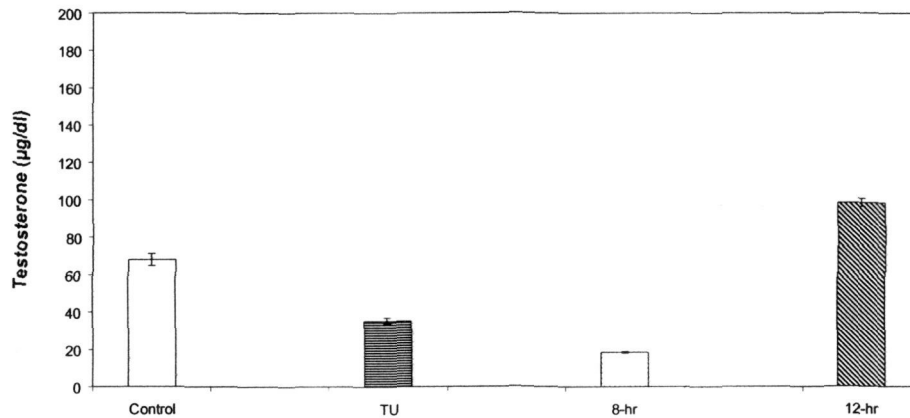


Fig.5. Effect of antithyroid drug 2-thiouracil (TU), 12-hr and 8-hr temporal phase relationship of 5-HTP and L-DOPA on plasma testosterone level of Japanese quail.

* $p < 0.05$, significance of difference from control

Histologically, T.S. of testis of control quail showed moderately active condition, having spermatogonia, primary and secondary spermatocytes and spermatozoa attached to spermatids. Whereas testis of TU (antithyroid drug) treated quail showed regressed condition, with increased (empty) intertubular spaces and cellular degeneration with debris in the lumen. 8-hr quail also showed the condition of atrophy with smaller seminiferous tubules, showing cellular degeneration and empty lumen. T.S. of testis of 8-hr+TU treated quail showed complete atrophy having remarkable shrinkage in seminiferous tubule size with increased and empty intertubular spaces and large amount of cellular debris in the lumen. On the other hand, testis of 12-hr treated quail showed full breeding condition. Enlarged seminiferous tubules had all the stages of spermatogenesis with bunch of spermatozoa in the lumen. The testis of 12-hr+TU group although showed breeding condition and seminiferous tubules were still large but lumen had eliminating spermatozoa and in some tubules cellular degeneration appeared to start. Increased intertubular spaces also showed cellular degeneration.

DISCUSSION

Administration of antithyroid drug (chemical thyroidectomy) and radioactive iodine (radiothyroidectomy) as an alternative to surgical thyroidectomy has been used experimentally to induce hypothyroidism and also to study thyroid-gonad relationship (31). Thyroidectomy is reported to decrease photoperiodic stimulation of the reproductive system in some birds but not in others (9, 32-34). Results of the present experiment indicate the existence of parallel thyroid-gonad relationship in Japanese quail since thiouracil (TU) treatment inhibited gonadal development. Present findings also reconfirmed that specific phase relation (i.e. 12-hr and 8-hr) of circadian serotonergic and dopaminergic activities play a role in reproductive development (stimulatory and inhibitory respectively) of quail. Chemical thyroidectomy induced by daily injections of antithyroid drug (2-thiouracil) inhibited gonadal growth. Significantly low level of plasma thyroxin and testosterone, compared to control confirms that antithyroid drug treatment has inhibited the rate of hormonogenesis of thyroid gland (hypothyroidism), which in turn led to gonadal suppression and hence decreased steroidogenesis (Fig. 4&5). Similarly, quail receiving two neurotransmitter precursor injections at 8-hr interval had low level of testosterone along with low concentration of T_4 . However, presently it is not possible to suggest the cause and effect of this gonad-inhibitory relationship (8-hr) on thyroid activity, except to support parallel thyroid-gonad relationship in this species as 8-hr induced gonadal suppression accompanies low thyroid activity. Further, antithyroid drug given simultaneously with 8-hr temporal phase relation of serotonergic and dopaminergic drugs has caused complete suppression of gonadal growth by influencing the activity of neuroendocrine-gonadal axis. On the other hand, 12-hr relation of serotonergic and dopaminergic activity stimulated gonadal development with simultaneous increase in testosterone and thyroxin levels. It is obvious that 12-hr relationship induced photosensitivity of

neuroendocrine-gonadal axis resulting in gonadal stimulation. Although exposure to long days is reported to stimulate the development of pituitary thyrotrophs and an increase in plasma thyroxin level in the duck and quail (35-37) but opposite results are also reported (38):

Higher level of plasma thyroxin and testosterone of control quail maintained under long days may be due to direct effect of daylength on neuroendocrine-thyroid and neuroendocrine-gonadal axis, but decrease in these hormones in 8-hr quail is cor-related with decreased gonadal condition which in turn possibly reduced thyroid function in view of parallel thyroid-gonad relationship. On the other hand, 12-hr temporal relationship of serotonergic and dopaminergic oscillators also appeared to increase the photosensitivity of neuroendocrine-gonadal and -thyroid axis resulting in increased plasma levels of testosterone and thyroxin. When 12-hr temporal phase relation of neural oscillators was combined with chemical thyroidectomy, the activity of neuroendocrine axis was not altered suggesting that inhibitory effect of antithyroid drug on gonad was overpowered by stimulatory effect of 12-hr and, hence, hypothyroidism induced gonadal suppression was not evident. Our findings conclude that in male Japanese quail gonadal growth requires the presence of optimal level of thyroid hormone (s) and chemical thyroidectomy causes inhibition of hormonogenesis of thyroid gland as well as gonadal suppression. This gonado-suppressive effect of hypothyroidism is comparable to the effect of 8-hr temporal relation of 5-HTP and L-DOPA administration. Moreover, gonado-stimulatory effect of 12-hr temporal relation of 5-HTP and L-DOPA was not suppressed by hypothyroidic condition. It is suggested that 12-hr relation of serotonergic and dopaminergic oscillators is a potent stimulator of neuroendocrine-gonadal axis and this stimulatory influence is maintained even in hypothyroidic condition which normally induces suppression of gonadal growth in view of parallel thyroid-gonad relationship in Japanese quail.

ACKNOWLEDGEMENT

Financial assistance from University Grants Commission - UGC F 3-201/2001 (SR-II) to CMC is gratefully acknowledged.

REFERENCES

- 1 Benoit J and Aron M (1934). Sure le conditionnement hormonal du developement testiculaire, Chez le coq et le canard. *Comptes Rendus Societe Biologie Paris* 116: 221-223.
- 2 Woitkawitsch AA (1940). Dependent of seasonal periodicity in gonadal changes on the thyroid gland in *Sturnus vulgaris*. *Comp Rend Acad Sci USSR* 27: 741.
- 3 Pandha S K and Thapliyal J P (1964). Effect of thyroidectomy upon the testes of *Uroloncha punctulata*. *Naturwissenschaften* 51: 202-204.

- 4 Thapliyal J P and Garg R K (1969). Relation of thyroid to gonadal and body weight cycles in male weaver bird, *Ploceus philippinus*. *Arch Anat Histol Embryol* 516: 689-695.
- 5 Wieselthiere A A and Van Tienhoven A (1972). The effect of thyroidectomy on testicular size and on the photorefractory period in the starling (*Sturnus vulgaris* L.). *J Exp Zool* 179: 331-338.
- 6 Thapliyal J P (1969). Thyroid in avian reproduction. *Gen Comp Endocrinol Suppl* 2: 111-122.
- 7 Chaturvedi C M and Thapliyal J P (1980). Light responses of thyroidectomized common myna, *Acridotheres tristis*. *Gen Comp Endocrinol* 42: 160-162.
- 8 Chaturvedi C M and Thapliyal J P (1983). Thyroid photoperiod and gonadal regression in common myna. *Gen Comp Endocrinol* 52 : 279-282.
- 9 Dawson A and Thapliyal J P (2001). The thyroid and photoperiodism. In: *Avian Endocrinology* (Dawson A and Chaturvedi CM, eds), pp 141-151. Narosa Publishing House, New Delhi, India.
- 10 Thapliyal J P and Pandha S K (1967). Thyroidectomy and gonadal recrudescence in lal munia, *Estrilda amandava*. *Endocrinologie* 81, 915-918.
- 11 Thapliyal J P and Bageshwar K (1970). Light responses of thyroidectomized weaver birds. *Condor* 72: 190-195.
- 12 Chandola A and Thapliyal J P (1974). Comparison of the effect of chemical, surgical and radiothyroidectomy in spotted munia, *Lonchura punctulata*. *Gen Comp Endocrinol* 22:128-131.
- 13 Höhn E U (1961). Endocrine glands, thymus and pineal body. In: *Biology and Comparative Physiology of Birds* (Marshall A J ed.) Vol. II. pp 87-112. Academic Press, New York / London.
- 14 Assemacher I (1973). Reproductive endocrinology: The hypothalamohypophyseal axis. In *Breeding of birds* (Farmer DS ed.). pp 158-191. National Academy of Science, Washington, D.C.
- 15 Thapliyal J P and Chandola A (1972). Thyroid in wild finches. *Proc Natl Aca. Sci India Section B* 42 Part 1, 1: 1-11.
- 16 Lal P (1988). Role of thyroid in seasonal and body weight cycles of the migratory red-headed bunting, *Emberiza bruniceps*. *Gen Comp Endocrinol* 70: 291-300.
- 17 Thapliyal J P (1997). Thyroid and gonadal hormones in initiation and termination of sexual cycles of Indian birds. In: *Frontiers in Environmental and Metabolic Endocrinology* (Maitra S K ed.). pp203-220. The University of Burdwan, India.
- 18 Chaturvedi C M and Bhatt R (1990). The effect of different temporal relationship of 5- Hydroxytryptophan (5-HTP) and L-Dihydroxyphenylalanine (L-DOPA) on reproductive and metabolic responses of migratory Red headed bunting (*Emberiza bruniceps*). *J Interdiscipl Cycle Res* 21: 129-139.

- 19 Chaturvedi C M, Bhatt R and Prasad S K (1994). Effect of timed administration of neurotransmitter precursor drugs on testicular activity, body weight and plumage pigmentation in the lal munia *Estrilda amandava*. *Ind J Exp Biol* 32: 238-242.
- 20 Phillips D and Chaturvedi CM (1995): Functional maturation of neuroendocrine gonadal axis is altered by specific phase relations of circadian neurotransmitter activity in Japanese quail. *Biomed Environ Sci* 8: 367-377.
- 21 Bhatt R and Chaturvedi CM (1998). Phase relation of neurotransmitter affecting drugs (5-HTP and L-DOPA) alters photo-sexual responses (scotosensitive and scotorefractory) in Japanese quail. *J Environ Biol* 19: 285-293.
- 22 Prasad SK and Chaturvedi CM (2003) Regulation of seasonal reproduction by neurotransmitter affecting drugs in spotted munia, *Lonchura punctulata*. *Pakistan J Zool* 35 : 181-189.
- 23 Tiwari AC and Chaturvedi CM (2003). Effect of temporal synergism of neural oscillators on gonadal development, egg production and hatchability of Japanese quail (*Coturnix coturnix*). *Indian J Poul Sci* 38 : 83-88.
- 24 Fetissov SO, Maguid MM, Chen C and Miyata G (2000). Synchronized release of dopamine and serotonin in the medial and lateral hypothalamus of rats. *Neuroscience* 101,3: 657-663.
- 25 Chaturvedi C M, Das U S and Thapliyal J P (1997). Comparative aspects in the reproductive endocrinology of two sexes of weaver bird, *Ploceus philippinus*. *XII International Congress of Comparative endocrinology*, Yokohama, Japan 16-21.
- 26 Dawson A, Goldsmith A R and Nicholls T J (1985). Thyroidectomy results in termination of photorefractoriness in starling (*Sturnus vulgaris*) kept in long day length. *J Reprod Fertil* 74: 527-533.
- 27 Chaturvedi C M and Meier A H (1989). Thyroid involvement in the relative photorefractoriness of Japanese quail. *J Exp Zool* 250: 63-66.
- 28 Meier A H, Martin D D and Mac Gregor R III (1971). Temporal synergism of corticosterone and prolactin controlling gonadal growth in sparrow. *Science* 173: 1240-1242.
- 29 John J M, Meier A H and Bryant E E (1972). Thyroid hormone and circadian rhythm of fat and crop sac responses to prolactin in the pigeon. *Physiological Zool* 45: 34-42.
- 30 Kovacs K and Peczely P (1983). Phase shift in circadian rhythmicity of total free corticosterone transcortin plasma levels in hypothyroid male Japanese quail. *Gen Comp Endocrinol* 50: 483-489.
- 31 Chandola A and Thapliyal J P (1974). Comparison of the effect of chemical, surgical and radiothyroidectomy in spotted munia, *Lonchura punctulata*. *Gen Comp Endocrinol* 22: 128-131.

- 32 Thapliyal J P (1969). Thyroid in avian reproduction. *Gen Comp Endocrinol Suppl 2*: 111-122.
- 33 Dawson A (1998). Thyroidectomy of house sparrow (*Passer domesticus*) prevents photoinduced testicular growth but not the increased hypothalamic gonadotrophin-releasing hormone. *Gen Comp Endocrinol 110* : 196-200.
- 34 Wilson F E and Reinert B D (1996). The timing of thyroid dependent programming in seasonally breeding male American tree sparrow (*Spizella arborea*). *Gen Comp Endocrinol 103*: 82-92.
- 35 Tixier-Vidal A and Gourdji D (1967). Influence compares de la castration de la lumiere permanente et de la testosterone sur les cdlu thyrotrope, gonadotrope (FSH, LH) et tropede la prehypophyse de canard male. *Gen Comp Endocrinol 9*: 500-505.
- 36 Tixier-Vidal A, Follet B K and Farner D S (1968). The anterior pituitary of the Japanese quail. The cytological effects of photoperiodic stimulation. *Z Zellforsch Mikrosk Anat 92*: 610-635.
- 37 Sharp P J and Klandrof H (1981). The interaction between day length and the gonads in the regulation of levels of plasma and thyroxin and tri-iodothyronine in Japanese quail. *Gen Comp Endocrinol 4*: 504-512.
- 38 Almeida O F X (1982). Hypothalamic secretion of thyrotropin releasing hormone is decrease in Japanese quail exposed to long day photoperiod. *J Endocrinol 92*: 261-265.