

# Scar Endometriosis: A Case Report and Review of Literature

Hemantkumar Gopal Borse<sup>1\*</sup> and Deepak Thombare<sup>2</sup>

<sup>1</sup>Professor, Department of General Surgery, Dr. Vasant Rao Pawar Medical College Hospital & RC, Nashik – 422003, Maharashtra, India; drhborse@gmail.com

<sup>2</sup>PG Resident, Department of General Surgery, Dr. Vasant Rao Pawar Medical College Hospital & RC, Nashik – 422003, Maharashtra, India; dr.dkthombare@gmail.com

## Abstract

Endometriosis is defined as the presence of functional endometrial tissue outside the uterus. Being a rare condition often it is not included in the differential diagnosis of abdominal wall swelling. The typical history is a swelling in the scar or near the scar of previous Gynaecological or Obstetric surgery. Most of the time the diagnosis is done only after excision of the swelling. A case of endometriosis in the scar of a caesarean section. We have also discussed clinical feature pathogenesis, diagnosis and treatment of scar endometriosis.

**Keywords:** Scar Endometriosis

## 1. Introduction

Endometriosis was first described by Karl Von Rokitansky in 1860<sup>1</sup>. It affects women in reproductive ages. It is defined as presence of functional and morphological endometrial glands and stroma outside the uterine cavity<sup>1</sup>, most frequently found in pelvis. Also found in extra pelvic area like - lungs, pleura, kidney, bladder, omentum, bowel, lymph node and abdominal wall<sup>2,3</sup>. Scar endometriosis is an abdominal wall endometriosis mostly occurring in old scar from obstetrical and gynecological procedures<sup>4</sup>. The variability of symptoms and clinical presentation as well as the lack of awareness about the disease can lead to difficulty in diagnosis and delay in treatment. This is a case report of scar endometriosis after cesarean section and reviews the literature about the disease.

## 2. Case Report

A 28-year-old female presented with subcutaneous swelling approximately 4cm above the scar of previous LSCS (Figure 1). There was history of increase in the size of

swelling and pain in the swelling (cyclical pain) associated with menstrual period. She had 4 similar episodes in last four months. She had history of lower segment cesarean section three years back. There was no other significant history

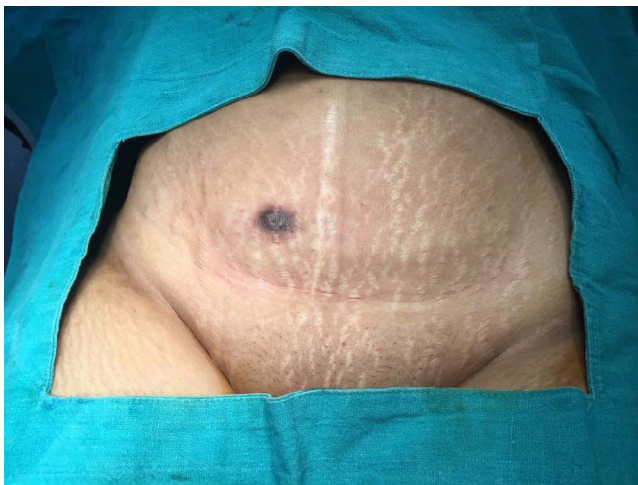
On examination there was a 2cm x 2cm swelling about 4cm above the LSCS scar. The scar of LSCS was normal. The skin above the swelling showed pigmentation. Ultrasonography of abdominal wall revealed a heterogeneous hypo echoic mass studded with echogenic spots. After routine investigations the patient was posted for surgery. Wide en bloc excision was performed with surrounding clear margins including overlying skin (Figure 2). The swelling was surrounded by fibrosis was extending upto the peritoneum. The histopathological examination revealed anterior abdominal wall endometriosis (Figure 3). The postoperative period was uneventful. After surgery her symptoms subsided.

## 3. Discussion

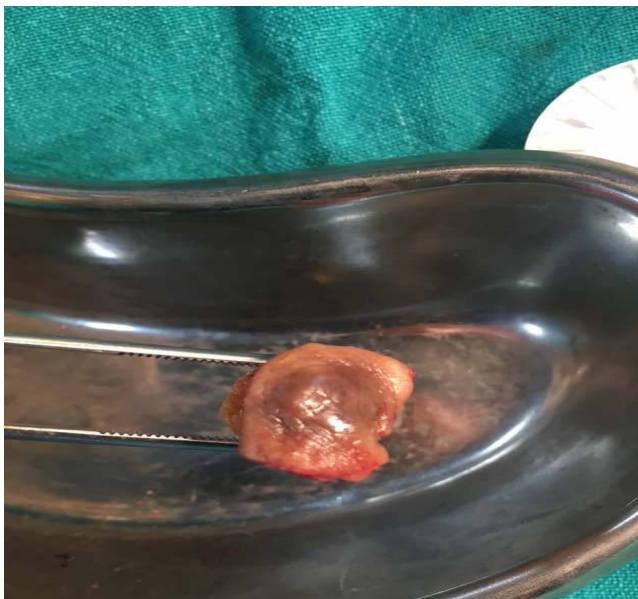Scar endometriosis is a rare condition. It is seen females after abdominal or pelvic operation. The patients of

\*Author for correspondence

scar endometriosis are referred to General Surgeons for painful swelling in the scar or near the scar of previous surgery (Figure 1). Some patients may take consultation of Dermatologist considering it to be a dermatological condition<sup>5</sup>. The incidence has been estimated to be only 0.03% to 0.15% of all cases of endometriosis<sup>6,7</sup>. Scar endometriosis is most frequently seen after LSCS. However in the literature it is mentioned that it can occur in scars of episiotomy, hysterectomy, hysterectomy and laparotomy<sup>8</sup>. When it is presents in abdominal wall it can be confused with abscess, lipoma, hematoma, sebaceous cyst, stitch granuloma, incisional hernia or tumors resulting in delay in diagnosis<sup>9</sup>.

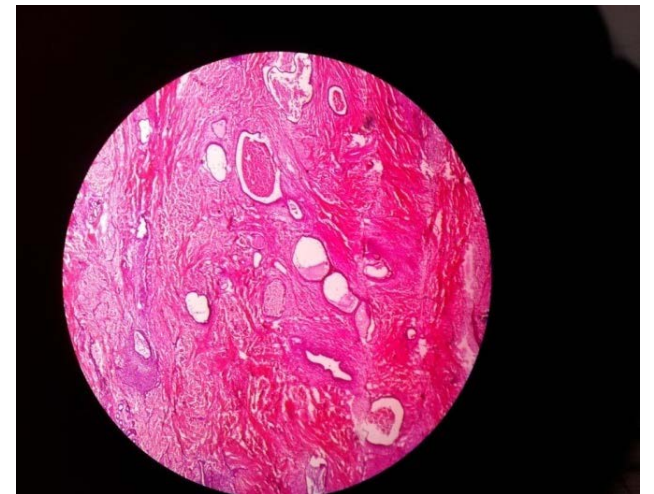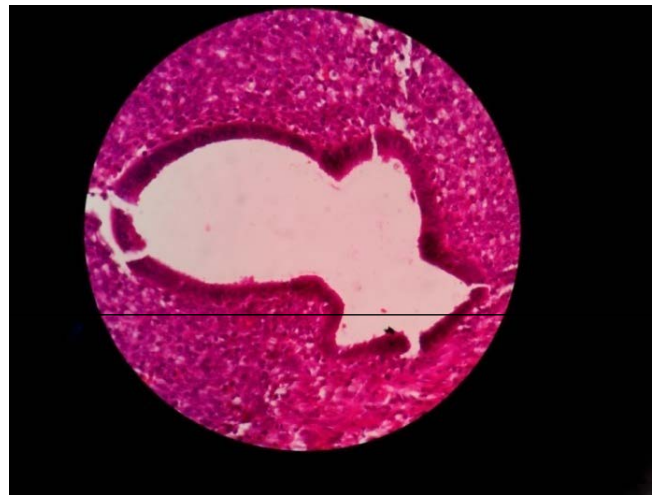


**Figure 1.** Swelling above the previous LSCS scar.



**Figure 2.** Wide local excision of the swelling.

During surgical procedure there is transplantation of endometrial or placental cells in the wound. This tissue is sensitive to hormonal changes. It is stimulated by estrogen which causes pain, swelling, tenderness, discharge which are typical symptoms of scar endometriosis<sup>2,6,7,10</sup>. Because of the variation of signs and symptoms, the diagnosis of scar endometriosis is often delayed. Cyclical changes in the size, intensity of pain during menstruation are classical for endometriosis, but only 20% of patient present with these symptoms<sup>11</sup>. Though implantation of endometrial cells occurs at the time of surgery, patient may present months or years after the surgery. The interval of 3 months to 10 years is reported in literature<sup>12,13</sup>.



**Figure 3.** Histopathology- scar endometriosis.

The diagnosis can be done on ultrasound with color Doppler, CT scan and MRI, but these investigations lack in specificity<sup>6</sup>. Fine needle aspiration cytology is a quick, cost effective and accurate diagnostic tool but there are

chances of seeding of cells along the tract of the needle. This may cause recurrence in future<sup>14</sup>.

The treatment is wide local excision with clear margins and reconstruction of damaged tissue<sup>8</sup>. Hormonal replacement may produce temporary relief of symptoms<sup>15</sup>. The definitive treatment is surgical excision (Figure 2, 3).

## 4. Conclusion

Scar endometriosis is a rare condition. In females presenting with swelling in or near the scar of previous pelvic surgery, scar endometriosis can be a differential diagnosis. High index of suspicion can help in early diagnosis.

## 5. References

1. American college of obstetrician and gynecologist. Practice bulletin no. 114: management of endometriosis. *Ostetrics and Gynecology*. 2010; 164(1):223–36.
2. Klinik N, Yalinkaya A, Ozaydin M. Nondecidualized and decidualized endometriosis of the abdominal wall (A report of two cases secondary to cesarean section). *Turk J Med Sci*. 2002; 32:505–8.
3. Gaunt A, Heard G, McKain ES, Stephenson BM. Cesarean scar endometrioma. *Lancet*. 2004; 364:368. [https://doi.org/10.1016/S0140-6736\(04\)16726-3](https://doi.org/10.1016/S0140-6736(04)16726-3)
4. Bektas H, Sar YS, et al. Abdominal wall endometrioma: A 10- year experience and brief review of the literature. *Journal of Surgical Research*. 2010; 164(1):e77–81. <https://doi.org/10.1016/j.jss.2010.07.043> PMID:20855082
5. Wolf Y, Haddad R, Werbin N, Skornick Y, Kaplan O. Endometriosis in abdominal scars: A diagnostic pitfall. *Am Surg*. 1996; 62:1042–4. PMID:8955245
6. Francica G, Giardiello C, Angelone G, Cristiano S, Finelli R, Tramontano G. Abdominal wall endometriosis near cesarean delivery scars. *J Ultrasound Med*. 2003; 22:1041–7. <https://doi.org/10.7863/jum.2003.22.10.1041> PMID:14606559
7. Kaloo P, Reid G, Wong F. Cesarean section scar endometriosis: Two cases of recurrent disease and literature review. *Aust NZ J Obstet Gynaecol*. 2002; 42:218–20. [https://doi.org/10.1111/j.0004-8666.2002.210\\_5.x](https://doi.org/10.1111/j.0004-8666.2002.210_5.x)
8. Blanco RG, Parithivel VS, Shah AK, Gumbs MA, Schein M, Gerst PH. Abdominal wall endometriomas. *Am J Surg*. 2003; 185:596–8. [https://doi.org/10.1016/S0002-9610\(03\)00072-2](https://doi.org/10.1016/S0002-9610(03)00072-2)
9. Koger KE, Shatney CH, Hodge K, McClenatha JH. Surgical scar endometrioma. *Surg Gynecol Obstet*. 1993; 177:243–6. PMID:8356497
10. Sasson IE, Taylor HS. Stem cell and pathogenesis of endometriosis. *Annals of New York Academy of Sciences*. 2008; 1127:106–15. <https://doi.org/10.1196/annals.1434.014> PMID:18443337 PMCid:PMC3107843
11. Ding CD, Hsu S. Scar endometriosis at the site of cesarean section. *Taiwanese J Obstet Gynecol*. 2006; 3:247–9. [https://doi.org/10.1016/S1028-4559\(09\)60234-5](https://doi.org/10.1016/S1028-4559(09)60234-5)
12. Chatterjee SK. Scar endometriosis: A clinicopathologic study of 17 cases. *Obstet Gynecol*. 1980; 56:81–4. PMID:7383492
13. Patterson GK, Winburn GB. Abdominal wall endometriomas: Report of eight cases. *Am Surg*. 1999; 65:36–9. PMID:9915529
14. Gupta RK. Fine needle aspiration cytodiagnosis of endometriosis in cesarean section scar and rectus sheath mass lesions: A study of seven cases. *Diagn Cytopathol*. 2008; 36:224–6. <https://doi.org/10.1002/dc.20797> PMID:18335552
15. Rivlin ME, Das SK, Patel RB, Meeks GR. Leuprolide acetate in the management of cesarean scar endometriosis. *Obstet Gynecol*. 1995; 85:838–9. [https://doi.org/10.1016/0029-7844\(94\)00270-N](https://doi.org/10.1016/0029-7844(94)00270-N)