

Impact on Visual Outcome and Complications in Postoperative Raised Intraocular Pressure (IOP) Patients of Cataract Surgery at a Tertiary Care Hospital

Saudamini Jaywantrao Jadhav¹ and Dhiraj Namdeo Balwir^{2*}

¹PG Resident, Department of Ophthalmology, Dr. Vasantrao Pawar Medical College and Research Centre, Nashik - 422003, Maharashtra, India; dr.saudaminijadhav@gmail.com

²Professor, Department of Ophthalmology, Dr. Vasantrao Pawar Medical College and Research Centre, Nashik - 422003, Maharashtra, India; dheeraj_balwir@yahoo.com

Abstract

Background and Objectives: Intraocular pressure increase frequently occurs in the early period after cataract Extraction. Some operated patients of cataract surgery, however, may experience pain, corneal oedema, glaucomatous nerve damage, or anterior ischemic optic neuropathy. Causes of this elevation in IOP include retained lens material, postoperative inflammation, and retention of viscoelastic substances within the anterior chamber. Postoperative increases in IOP are transient and benign. It is therefore important to monitor continuously the effect of new cataract surgical techniques on postoperative IOP as well as the impact of increased IOP on visual outcomes. **Materials and Methods:** Out of total patients who underwent cataract surgery at our institute 1311 had increase in intra-ocular pressure during November 2015 to October 2017. Out of those total number of 150 patients were selected at random after taking inclusion and exclusion criteria into consideration. Cases of increased intraocular pressure post cataract surgery were included in study were examined in full on observations documented on post-operative Day 1 then till discharge, after 7 days, 1 month and 3 months. **Results:** Thus, incidence of increase in intraocular pressure after cataract surgery in our institute is 24.15%. In the present study acute postoperative inflammation was the most common cause (39%) of increase in intraocular pressure. Other common causes were vitreous obstruction following posterior capsular rupture (27%), retained visco-elastic substances (22%). Least common cause (2%) in our study was retained lenticular fragments. **Conclusion:** Maximum patients (53%) with raised intra-ocular pressure post-cataract surgery had pressures in the range of 21 to 30 mm Hg. Majority (64%) had post-operative day 1 best corrected visual acuity between FC 1 m to 20/200. No patient had BCVA 20/20 to 20/40. Patients with increased IOP more than 40 mm Hg were associated poor visual outcome compared to patients with less IOP rise. In maximum patients (86%), intra-ocular pressure became normal (<21mm hg) within 7 days.

Keywords: Corneal Edema, Goldmann Applanation Tonometer, Intraocular pressure

1. Introduction

In the early period after cataract Extraction intraocular pressure frequently increases¹⁻⁵. Elevated IOP was transient and benign according to a study conducted

in 1976 on 630 cases of cataract extraction. Although pain, corneal oedema, glaucomatous nerve damage, or anterior ischemic optic neuropathy may occur in some cases of cataract surgery⁷.

*Author for correspondence

The most common postoperative complication demanding treatment after phacoemulsification is elevated intraocular pressure⁸. Major post-operative complication occurring within 24 hours after cataract surgery is raised intraocular pressure after cataract surgery⁹⁻¹¹. Causes of this elevation in IOP include retained lens material, postoperative inflammation, and retention of viscoelastic substances within the anterior chamber. With the potential risks caused by sudden pressure spikes, the possibility of a postoperative persistent elevation in IOP is of great concern to us^{12,13}.

After cataract surgery increase in intraocular pressure are transient and benign in majority of cases⁶. Once the IOP returned to normal in cases without glaucoma no visual field defects were seen⁶.

Radius and Maumenee¹⁴ studied the impact of elevation of intraocular pressure which was transient but significant. Clinical details of 24 patients were presented by him in whom there was IOP spike up to 85 mmHg which lasted from 3 h to 5 days after cataract surgery. There did not occur any permanent visual field defect in any of these cases after intraocular pressure was restored to normal. According to Duke-Elder¹⁵ who stated that after a single attack of high tension the visual field may be unaffected, these results were similar to Duke-Elder's findings, however repeated episodes of raised IOP result in general depression of all isopters is supported by the author¹⁵.

2. Materials and Methods

This study was conducted at a tertiary care centre well equipped ophthalmic set up. This study is a clinical, observational, prospective longitudinal study.

Out of total patients who underwent cataract surgery at our institute 1311 had increase in intra-ocular pressure during November 2015 to October 2017. Out of those total number of 150 patients was selected at random after taking inclusion and exclusion criteria into consideration.

2.1 Inclusion Criteria

1. Cases of increased intraocular tension post cataract surgery on postoperative 1st day that is post-operative intra-ocular pressure of more than 21mmHg by Goldmann tonometer.
2. Males and females of age more than 18 years.

2.2 Exclusion Criteria

1. Cases of primary glaucoma and pre-existing secondary glaucoma.
2. Undergoing cataract surgery.
3. Cases of ocular hypertension undergoing cataract surgery.
4. Cases of combined cataract extraction and glaucoma surgery.
5. Complicated cataract i.e. cataract associated with some other intraocular diseases like iridocyclitis, retinitis pigmentosa, retinal detachment and intraocular tumours.
6. Cases with pre-existing ocular inflammation.

In OPD, as a routine, detailed pre-operative examination was done including external torch light examination, IOP measurement by using Goldmann applanation tonometer, sac syringing was done followed by dilated fundus examination, refraction and slit-lamp examination to determine grade of cataract and to rule out any or chronic inflammation. Then best corrected visual acuity was measured for both distances as well as near using Snellen's Chart.

Patients willing for cataract surgery with decrease in visual acuity were advised basic blood investigations as complete haemogram, Fasting and post-prandial sugar, renal function test, routine chest X-ray (Postero-anterior view), electro-cardiogram and worked up for surgery. In addition, appropriate fitness, if required, were taken in cases with systemic illnesses. Patients who were on oral anticoagulants were asked to stop them 7 days prior to surgery. A-scan and keratometry were done, and intra-ocular lens power was calculated using SRK II formula.

Patients were admitted in ward after complete pre-surgical work up and posted for surgery on next day. Pre-operatively, oral antibiotic, Tablet Ciprofloxacin (500mg) BD was started on day prior to surgery. On the day of surgery, pre-operative pupillary dilatation was done with Flurbiprofen eye drop and Phenylephrine + Tropicacyl eye drop 2 hours prior to surgery.

In all patients of the study, we tried to put posterior chamber. Intra-ocular lens except cases in which intra-operative complication of posterior capsular rent occurred causing inadequate support for lens. In most of such cases anterior chamber intraocular lens was put. In remaining cases patients were left aphakic.

Peripheral button-hole iridectomy was not done in all cases but was particularly done in patients with posterior capsular rupture. In our institute we use Hydroxy propyl methyl cellulose as visco elastic device.

After completion of surgery, adequate anterior chamber wash was given to remove visco-elastic substance. Sub-conjunctival injection gentamycin + dexamethasone was given. Then Chloramphenicol eye-ointment was put and eye was padded.

Post-operatively pad was opened on next day morning and examined for Best corrected visual acuity, slitlamp examination, IOP measurement by Goldmann applanation tonometer.

Cases with increased IOP more than 21 mm Hg irrespective of the cause and those fulfilling eligibility criteria were included in study after written informed consent of patient and one relative.

Cases included in study were examined in full on observations documented on post-operative Day 1 then till discharge, after 7 days, 1 month and 3 months.

3. Observations and Results

The study conducted was Prospective, observational, longitudinal study conducted at our institute on 150 cases of both sexes who satisfied the criteria were included in the study and following observations were made:

Out of the total patients operated for cataract surgery in our institute in the study duration of 2 years, 1311 patients developed increase in intra-ocular pressure. Thus, incidence of increase in intra-ocular pressure after cataract surgery in our institute is 24.15%. 150 cases were selected at random from this sample population for this study.

Table 1. Sex distribution

Gender	No. of Patients	Percentage (%)
Male	84	56
Female	66	44
Total	150	100

In the present study, there was male preponderance. Out of 150 cases, males were 56% and females were 44%. Male to female ratio was 1.27:1 (Table 1 and Figure 1).

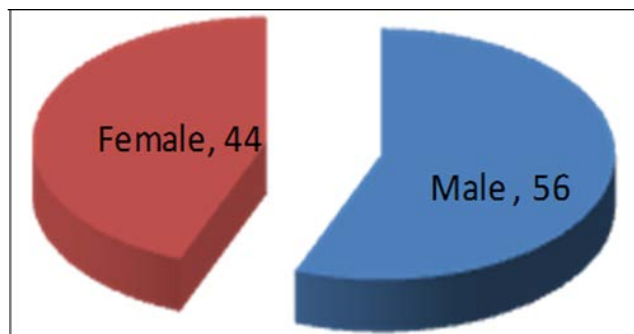


Figure 1. Pie chart showing sex distribution of patients.

Out of 150 patients there were 84 male and 66 females (Table 1).

Table 2. Age distribution table

Age in years	No. of Patients	Percentage
18-30	3	2
31-50	15	10
51-70	78	52
>70	54	16
Total	150	100

Majority patients were of the age group 51 to 70 year (Table 2).

Table 3. Distribution of cases according to type of surgery

Surgery	Sics	Phaco	Total
No. of cases	114	36	150
Percentage	76	24	100

Out of 150 cases, 114 (76%) were operated by SICS and 36(24%) by phacoemulsification (Table 3).

Table 4. Variation in IOP in patients on postop day 1

IOP Range (mm Hg)	No. of Patients	Percentage
21-30	81	53
31-40	45	31
41-50	15	10
51-60	6	4
61-70	3	2
>70	0	0
Total	150	150

In this study, maximum patients with increase in intra-ocular pressure had pressure in the range of 21 to 30 mm Hg, followed by range of 31-40 mmHg. IOP of more than 70 mm Hg was not present in any of the patient under this study (Table 4).

Table 5. Distribution of cases according to best corrected visual acuity (BCVA) on Post-Operative Day (POD) 1

BCVA (by Snellen's Chart) on POD 1	No. of Patients	Percentage (%)
No PL to FC <1 meter	48	32
FC1 meter to 20/200	96	64
20/120 -20/60	6	4
Total	150	100

In our study, best corrected visual acuity on post-operative day 1 was between FC 1 meter to 20/200 (6/60), seen in 64% of patients. Visual acuity of 6/12 or better was not seen in any of the patient under this study (Table 5).

Table 6. Distribution of patients according to cause of raised Intra-Ocular Pressure (IOP)

Cause of increase in IOP	No. of patients	Percentage (%)
Ocular visco-elastic device	34	22
Acute inflammation	58	39
Posterior Capsular rupture with vitreous loss	40	27
Water tight wound	9	6
Hyphaema	6	4
Retained lenticular fragments	3	2
Total	150	100

In the present study, acute post-operative inflammation is the most common cause of increase in intra-ocular pressure which is seen in 39% of cases, which is followed by retained visco-elastic devices (22%) Least common cause in our study was retained lenticular fragments seen in 2% of cases (Table 6).

Table 7. Distribution of cases according to time taken to normalise the intra ocular pressure

Follow up interval	No. of patients	Percentage (%)
Day 7	129	86

At 1 month	17	11
At 3 months	2	1
Total	148	98

In maximum patients, intra-ocular pressure became normal (<21mm hg) within 7 days (86%). In another 11% patients pressure became normal by 1 month. 2 patients had intra-ocular pressure within normal limits by 3 months. So, 98% of the patients had normal IOP by 3 months. Only 2 patients had increased intra-ocular pressure on follow up after 3 months (Table 7).

Table 8. Distribution of cases according to Best Corrected Visual Acuity (BCVA) at post-operative 3 months follow up

BCVA (by Snellen's Chart)	No. of Patients	Percentage (%)
NO PL to < FC 1 meter	3	2
FC 1 meter to 20/200	15	10
20/120 to 20/60	30	20
20/40 to 20/20	102	68
Total	150	100

Even after increase in intra-ocular pressure, maximum patients 68% developed post -operative Best Corrected Visual Acuity (BCVA) between 20/40 to 20/20. One patient had best corrected visual acuity of 1/4 meter due to bullous keratopathy (Table 8).

The highest intraocular pressure spikes were seen with SICS (40%).

Intraocular pressure of 21 to 30 mm Hg was seen in majority of the patients, i.e., 49% of patients with SICS and 69% of the patients who underwent phacoemulsification had an intraocular pressure of 21 to 30 mm Hg post operatively on day 1.

4. Discussion

The present study was Prospective, observational, longitudinal study conducted at our institute on 150 cases of both sexes who had raised intraocular pressure post cataract study were included in the study.

Out of the total patients operated for cataract surgery in our institute in the study duration of 2 years, 1311 patients developed increase in intra-ocular pressure. Thus, incidence of increase in intra-ocular pressure after cataract surgery in our institute is 24.15%. 150 cases were

selected at random from this sample population for this study.

Incidence of intraocular pressure elevation on day 1 post-operative after resident-performed cataract surgery was 22.0% according to a study conducted at Department of Ophthalmology, Harvard Medical School at the Comprehensive Ophthalmology Service of the Massachusetts Eye between 1 July 2001 to 30 June 2006¹⁶.

A 25% incidence of intraocular pressure spikes (>30mm Hg) 4-6 hrs following uncomplicated phacoemulsification and IOL implantation was reported by a study conducted at Royal Free hospital, London, United Kingdom. However, 24 hrs postoperatively the incidence of intraocular pressure spike declined significantly to 10% after 24 hrs following cataract surgery and also intraocular pressure was within normal limit (21mm Hg) 3 weeks later in all cases¹⁷.

In the present study, maximum number of patients i.e., 64% had BCVA on post-operative day 1 between FC 1 m to 20/200. None of the patients in our study had BCVA of 20/40 or better.

It was observed in our study that acute post-operative inflammation was the most common cause of increase in intra-ocular pressure post cataract surgery which is seen in 38.66% of cases, followed by vitreous obstruction after posterior capsular rupture. Raised intra-ocular pressure may be caused by pupillary block or angle obstruction.

Least common cause in our study was retained lenticular fragments seen in 2% of cases. Other causes such as early endophthalmitis, iris pigment release induced increased IOP or pupillary block due to optic capture were not seen in our study.

Majority of patients (56%) having vision of 20/40 or better had IOP within 10 – 15 mm Hg. No patient with visual acuity of 20/40 or better had increased intra-ocular pressure on 3 monthly follow up.

66.66% of patients with BCVA 20/200 or worse had IOP within normal limits. 20% had IOP less than 10 mm of Hg with no signs of ocular hypotony. 2 patients had elevated IOP of 28 and 26 mm of Hg even after 3 months of follow up. Same patient developed associated perimetric changes and glaucomatous disc changes. Patient was started on long term local anti-glaucoma treatment and was advised monitoring for glaucoma progression.

5. Summary and Conclusions

In the present study acute post-operative inflammation was the most common cause (39%) of increase in intra-

ocular pressure. Other common causes were vitreous obstruction following posterior capsular rupture (27%), retained visco-elastic substances (22%). Least common cause (2%) in our study was retained lenticular fragments.

Majority (64%) had post-operative day 1 best corrected visual acuity between FC 1 m to 20/200. No patient had BCVA 20/20 to 20/40.

At 3 months follow up postoperatively, maximum patients (68%) had post-operative BCVA between 20/40 to 20/20. Good visual outcome (84%) was seen in patients with IOP on day1 less than 40mmHg.

Patients with increased IOP more than 40 mm Hg had poor visual outcome compared to patients with less IOP rise.

74.41% of patients in whom IOP normalised by day 7 post operation achieved vision 20/40 or better indicating the relation between the duration of increased IOP with final visual outcome. Still we need to consider other confounding factors affecting final visual outcome. In maximum patient's intra-ocular pressure on follow up after 3 months was between 11 to 20 mm Hg (81.33%).

6. References

1. Gormaz A. Ocular tension after cataract surgery, *Am. J. Ophthalmol.* 1962; 53:832–41. [https://doi.org/10.1016/0002-9394\(62\)93405-0](https://doi.org/10.1016/0002-9394(62)93405-0).
2. Rich WJ. Intraocular pressure and wound closure after cataract extraction, *Trans Ophthalmol. Soc. UK.* 1968; 88:437–39.
3. Galin MA, Lin LL, Obstbaum SA. Cataract extraction and Intraocular pressure, *Trans Ophthalmol. Soc. UK.* 1978; 98:124–27.
4. Gross JG, Meyer DR, Robin AL, Filar AA, Kelley JS. Increased Intraocular pressure in the immediate post-operative period after extracapsular cataract extraction, *Am. J. Ophthalmol.* 1988; 105:466–69.
5. Kooner KS, Cooksey JC, Perry P, Zimmerman TJ. Intraocular Pressure following ECCE, phacoemulsification and PCIOL implantation, *Ophthalmic. Surg.* 1988; 19:643–46.
6. Tranos P, BharG, Little B. Postoperative intraocular pressure spikes: The need to treat, *Eye.* 2004; 18:673–79. <https://doi.org/10.1038/sj.eye.6701319>. PMID:15002028.
7. Ermis SS, Ozturk F, Inan UU. Comparing the effects of travoprost and brinzolamide on intraocular pressure after phacoemulsification, *Eye.* 2005; 19:303–07. <https://doi.org/10.1038/sj.eye.6701470>. PMID:15258611.
8. Hildebrand GD, Wickremasinghe SS, Tranos PG, et al. Efficacy of anterior chamber decompression in controlling

- early intraocular pressure spikes after uneventful phacoemulsification, *J. Cataract Refract Surg.* 2003; 29:1087–92. [https://doi.org/10.1016/S0886-3350\(02\)01891-6](https://doi.org/10.1016/S0886-3350(02)01891-6).
9. Percival SPB. Complications from use of sodium hyaluronate (Healonid) in anterior segment surgery, *Br. J. Ophthalmol.* 1982; 66:714–16.
 10. Passo MS, Ernest JT, Goldstick TK. Hyaluronate increases intraocular pressure when used in cataract extraction, *Br. J. Ophthalmol.* 1985; 69:572–75. <https://doi.org/10.1136/bjo.69.8.572>. PMID: 4016054, PMCID: PMC1040681.
 11. Böhmer TG, Lagreze WA, Funk J. Intraocular pressure rise after phacoemulsification with posterior chamber lens implantation: E Vect of prophylactic medication, wound closure, and surgeon's experience, *Br. J. Ophthalmol.* 1995; 79:809–13. <https://doi.org/10.1136/bjo.79.9.809>. PMID:7488598, PMCID:PMC505265.
 12. Rod Foroozan MD. Cataract surgery and Intraocular pressure. <http://www.medscape.com/viewarticle/571405>.
 13. Schwenn O, Dick HB, Krummenauer F, Krist R, Pfeiffer N. Intraocular pressure after small incision cataract surgery: Temporal sclerocorneal versus clear corneal incision, *J. Cataract Refract Surg.* 2001; 27:421–25. [PubMed]. [https://doi.org/10.1016/S0886-3350\(00\)00577-0](https://doi.org/10.1016/S0886-3350(00)00577-0).
 14. Radius RL, Maumenee AE. Visual field changes following acute elevation in intraocular pressure, *Trans. Am. Acad. Ophthalmol. Otolaryngol.* 1977; 83: 61–68.
 15. Duke-Elder S (ed). *System of Ophthalmology, Vol 11, Diseases of the lens and vitreous, Glaucoma and hypotony* CV Mosby Co.: St Louis, MO, 1969, p 602.
 16. Kim JY, Jo M-W, Brauner SC, Ferrufino-Ponce, Z, Ali, R, Cremers, SL and An Henderson B. Increased intraocular pressure on first postoperative day following cataract surgery, *Eye London.* 2011; 25(7):929–36. <https://doi.org/10.1038/eye.2011.93>. PMID: 21527959, PMCID: PMC3178167.
 17. Tranos P, Wickremasinghe S, Hildebrand D, Asaria R, Mearza A, Nouri S et al. Same vs first postoperative day review after uncomplicated phacoemulsification. Are we overtreating early intraocular pressure spikes, *J. Cataract Refract Surg.* 2003; 29(3):508–12. [https://doi.org/10.1016/S0886-3350\(02\)01649-8](https://doi.org/10.1016/S0886-3350(02)01649-8).

How to cite this article: Jadhav SJ, Balwir DN. Impact on Visual Outcome and Complications in Postoperative Raised Intraocular Pressure (IOP) Patients of Cataract Surgery at a Tertiary Care Hospital. *MVP J. Med. Sci.* 2019; 6(1):39-44.