

Clinical Study of Solitary Nodule of Thyroid at Tertiary Health Centre

Sudhir Bhamre¹ and Sanket Chaudhari^{2*}

¹Professor and Head, Department of Surgery, Dr. Vasant Rao Pawar Medical College Hospital and Research Centre, Adgaon - 422203, Nashik, Maharashtra, India; sudhirbhamare69@gmail.com

²PG Resident, Department of Surgery, Dr. Vasant Rao Pawar Medical College Hospital and Research Centre, Adgaon - 422203, Nashik, Maharashtra, India; sanketchaudhari90@yahoo.co.in

Abstract

Introduction: Solitary nodule of thyroid has increased in incidence in the present day as compared to two decades before. Because of possibility of malignancy, some clinicians especially those in surgical subspecialties recommended that all nodules have to be removed. **Material and Methods:** Data collection by meticulous history taking and clinical examination, appropriate laboratory and radiological investigations, operative findings, histopathological report and follow-up of cases. **Results:** Study was conducted with 35 patients. The peak incidence of solitary thyroid nodule was observed in 3rd to 4th decade with four times more common in females as compared to male. The common causes of solitary thyroid nodule were colloid goitre (31.4%), Multinodular goitre (20%) and adenomatous goiter (17.1%), 94% of cases presented with euthyroid state. Incidence of malignancy in solitary thyroid nodule was 23%. The most common cause of malignancy was papillary carcinoma (14.3%). **Conclusion:** Solitary thyroid nodule is more common in 3rd to 4th decades. Solitary thyroid nodule is more common in females. Most of the patients presenting with solitary thyroid nodule are euthyroid and only a small percentage of patient with toxicity or hypothyroidism. USG can be accurately used to detect patients with multinodular goiter who clinically present as solitary thyroid nodule. Common causes of solitary thyroid nodule are colloid goitre, MNG, and adenomatous goiter. The most common cause of malignancy in solitary thyroid nodule is papillary carcinoma followed by follicular carcinoma.

Keywords: Euthyroid, Malignancy, Solitary Nodule

1. Introduction

The Solitary Thyroid Nodule (STN) has aroused interest of thyroidologist since the time of Cole and Majarakis and his study concluded that incidence of malignancy is higher when compared with Multi-Nodular Goiter (MNG)¹. Thyroid nodules are very common entities, though varying in incidence in different geographical regions. The prevalence of palpable nodules in general population is 4-7%². Solitary nodules of thyroid are about four times more common in women than in men. Overall incidence of malignancy in STN ranges from 10% to 30%³. Thyroid nodule is palpably or radiologically distinct lesion from

the surrounding thyroid parenchyma. Many solitary nodules are found asymptotically, but because of their size and position can result in obstructive symptoms of trachea and oesophagus (dyspnoea and dysphagia). The major concern relates to the potentiality for malignancy of solitary nodule. There is a high risk of malignancy in STN than in multiple nodules. Because of this reason, STN have to be treated with high degree of suspicion and plan treatment in a systematic manner⁴. Radionuclide imaging has been the mainstay in the evaluation of STN since 1939 when Hamilton and Soley demonstrated that malignant thyroid tissue concentrates less radioactive iodine than normal thyroid tissue. Thyroid nodules are

*Author for correspondence

further classified into cold, warm and hot according to their ability to accumulate the radioactive isotope. Cold nodules are considered hypofunctional whereas warm nodules are normal and hot nodules are hyper functional. Thyroid Fine Needle Aspiration (FNA) biopsy is the most accurate test for determining malignancy and is an integral part of current thyroid nodule evaluation. Results are superior when FNA is performed with ultrasound-guidance FNA (USFNA)⁵.

2. Aims and Objectives

1. To determine the incidence of solitary nodule of thyroid in general population in relation to age and sex.
2. To determine the incidence of solitary nodule of thyroid turning out to be (MNG).
3. To study the incidences of euthyroid, hyperthyroid or hypothyroid states in patients presenting with solitary nodule of thyroid.
4. To study the role of FNAC in the management of solitary nodule of thyroid.
5. To determine the incidence of adenoma, carcinoma and thyroiditis as a cause of solitary nodule of thyroid in tertiary health center.

3. Material and Methods

The present study on clinical study of solitary nodule of thyroid at “tertiary health centre” has been conducted by utilising cases admitted in Department of Surgery at Dr. Vasantrao Pawar Medical College and Hospital from August 2015 to December 2017. Descriptive analysis of 35 cases of solitary thyroid nodule in the specified period done. These cases were selected by random sampling method and studied in detail clinically. Routine investigations and specific investigations including FNAC of the nodule, thyroid profile USG neck were done in all cases. All the patients were managed by surgery and diagnosis was confirmed by histopathological examination.

3.1 Inclusion Criteria

- Patients presenting clinically with solitary thyroid nodule.
- Both male and female patients are included in study.

3.2 Exclusion Criteria

- Patients clinically with multinodular goitre.
- Patients with diffuse swelling of thyroid.
- Patients refusing for investigations or management.

The patients were grouped according to different variables like age, sex, size of the nodule, site of the nodule, functional thyroid status, FNAC reports and histopathological examination reports, then analysed and compared with the previous similar studies conducted elsewhere. Finally, conclusions were drawn accordingly.

3.3 Treatment

3.3.1 Preoperative

Antithyroid drugs, beta blockers, blood transfusions or any other medications were described based on individual status and was noted.

3.3.2 Peroperative

Position of the patient, type of anaesthesia, incision, type of operation planned, peroperative findings and type of operation performed were recorded.

3.3.3 Postoperative

Every patient was followed up postoperatively during the course of management in the hospital to note the development of and management of complications.

3.3.4 Follow-up

At the time of discharge, all the patients were advised to attend the surgical OPD regularly for follow up. Any recurrences or complications were noted. Thyroid functional status was assessed, accordingly thyroxine tablets prescribed if necessary.

4. Results

Total of 35 cases of solitary thyroid nodule studied and following conclusions were drawn:

- Mean age of study cases was 38.32 years with most of the subjects between 21-40 years (65.7%) of age.

- Female preponderance was seen in the cases with solitary thyroid nodule with 80% females to 20% males.
- Most common presenting feature was swelling (100%) followed by pain (14.3%) and discomfort (11.4%). Dysphagia was seen in 5.7% cases.
- Size of the nodule between 1-2 cm and 2-3 cm was seen in 51.4% and 31.4% cases respectively with nodule greater than 5 cm was seen in 11.4% cases. Hard consistency and ill-defined margins were seen in 14.3% and 17.1% cases respectively.
- Out of 35 cases, 33 (94.3%) had normal thyroid functions while hyperthyroidism was seen in only 2 (5.7%) cases.

Table 1. FNAC reports

FNAC Reports	No of Patients
Adenomatous Goitre	6
Benign Thyroid Follicular Cells in Clusters	1
Follicular Adenoma	2
Colloid goitre	18
Suspicious	2
Medullary Ca	1
Papillary Ca	5
Total	35

As per FNAC report, colloid goitre was the most common observation (51.4%) followed by adenomatous goitre (17.1%). Papillary and medullary carcinoma was seen in 14.3% and 2.9% cases respectively. Suspicious FNAC report was given in 2 cases (5.7%) (Table 1 and Figure 1).

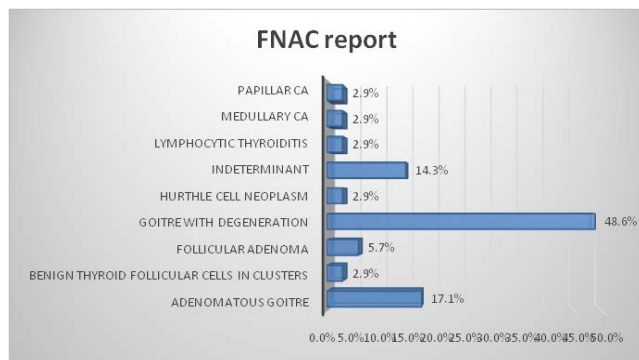


Figure 1. FNAC reports.

Table 2. Surgery/operative procedure

Procedure performed	No of patients
Total thyroidectomy	8
Hemithyroidectomy	22
Subtotal thyroidectomy	7
Total	35

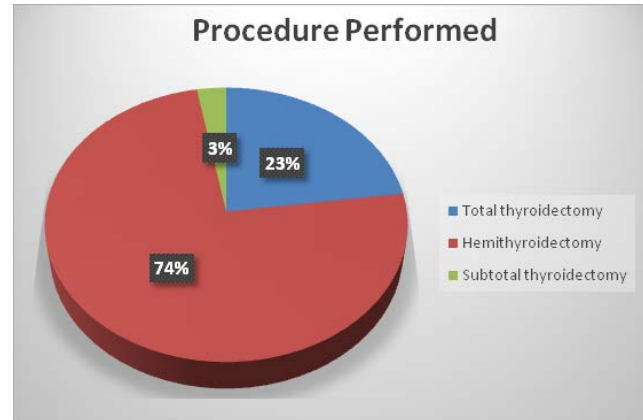


Figure 2. Procedure performed.

Table 3. Postoperative histopathological report

HPE Report	No of patients
Adenomatous goitre	6
Colloid goitre	11
Follicular adenoma	3
Follicular variant of Papillary Ca	2
Multinodular goitre	7
Medullary Ca	1
Papillary Ca	5
Total	35

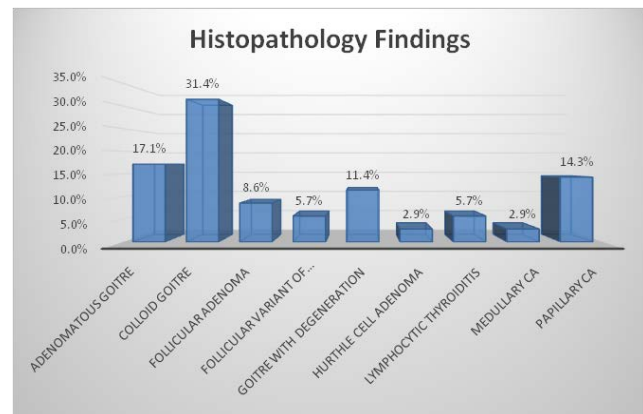


Figure 3. Histopathology findings.

As per histopathology report, colloid goitre (31.4%) was the most common observation in cases of solitary thyroid nodule followed by multinodular goitre (20%) and adenomatous goitre (17.1%). Other findings included follicular adenoma (8.6%), papillary carcinoma (14.3%), follicular variant of papillary carcinoma (5.7%) and medullary carcinoma (2.9%) (Table 2-3 and Figure 2-3).

5. Discussion

The present prospective observational study was done to evaluate the spectrum of cases presented to a tertiary care centre as solitary thyroid nodule and to determine the incidence of adenoma, carcinoma and thyroiditis as a cause of solitary nodule of thyroid.

5.1 Demography

Mean age of study cases was 38.32 years with most of the subjects between 21-40 years (65.7%) of age. Female preponderance was seen in the cases with solitary thyroid nodule with 80% females to 20% males.

This is similar to study conducted by Fenn *et al.*, in which maximum incidence was in the age group of 30-40 (35%)¹¹. Study¹² the mean age of presentation was 49 years. Study¹¹ incidence in females was higher i.e. 71% as compared to 29% in males¹¹. In the study⁶ commonest age group of presentation was 31-40 years with mean age was 35.5 years. Ratio of female to male was 70% to 30%.

5.2 Clinical Presentation

Solitary thyroid nodule is a palpable nodule in a otherwise apparently normal thyroid gland². The clinical spectrum ranges from the incidental, asymptomatic, small, solitary nodule in which the exclusion of cancer is the major concern, to the large, partly intrathoracic nodule that causes pressure symptoms, for which treatment is warranted regardless of cause. History and Physical examination remain the cornerstone in the evaluation of solitary thyroid nodule.

Most common presenting feature observed were swelling (100%) followed by pain (14.3%) and discomfort (11.4%). In the study by Keshri *et al.*,⁶ swelling was observed in all cases (100%) followed by pain (15%). Study⁸ observed swelling in all cases while pain and discomfort in 4% and 7% cases.

Presence of pressure symptoms is uncommon with solitary thyroid nodule as nodules are usually not large enough. However, presence of pressure symptoms is

a poor prognostic factor as it is commonly associated with malignancy¹⁶. Pressure symptoms arise because of pressure on trachea, oesophagus, recurrent laryngeal nerve manifesting as stridor, dysphagia or hoarseness of voice respectively¹⁴⁻¹⁶.

In our study only 2 patients had pressure symptoms in the form dysphagia (5.7%) while none had change in voice or dyspnoea. Similar observation¹³ incidence of patients presenting with pressure symptoms was 5%. Keshri *et al.*,⁶ in their study dyspnoea and dysphagia was seen in 4% and 15% cases. Study⁸ observed pressure symptoms and voice change in 1.5% and 3% cases.

5.3 Examination

A solitary thyroid nodule can be hard or firm in consistency. In our study 5 patients (14.3%) had hard nodules on clinical examination. Out of these 5 patients, 3 patients turned out to be cancerous and 2 multinodular goitre on final histopathology. Similar observations¹⁷ found hard consistency in 18% cases of STN and malignancy in 66% of patients with hard nodules.

Size of the nodule between 1-2 cm and 2-3 cm was seen in 51.4% and 31.4% cases respectively while nodule greater than 5 cm was seen in 11.4% cases. On comparing the association between the size of nodule and incidence of malignancy, size of the nodule >5 cm was seen in 4 cases and 3 of these were malignant and 1 colloid goitre on histopathology. Similar observations¹⁸ found that chance of malignancy is greatly increased if size of the nodule is more than 5 cm.

A thyroid nodule is considered ill-defined when more than 50% of its border is not clearly demarcated. Furthermore, nodules can be classified according to their contours as smooth and rounded or irregular with jagged edges. An ill-defined and irregular margin in a thyroid tumour suggests malignant infiltration of adjacent thyroid parenchyma with no pseudo capsule formation^{19,20}.

In our study, out of 35 patients 29 patients (82.9%) had nodules with well-defined margins while remaining 6 patients (17.1%) had nodules with ill-defined margins. Further it was found that out of 6 patients having nodule with ill-defined margin, 5(83.9%) were diagnosed to have malignant nodule and 1 colloid goitre on histopathology. In a study²¹ 77.4% malignant nodules had irregular margins.

5.4 Thyroid Function Test

All patients in our study were subjected for thyroid function tests. Thyroid function test includes serum TSH,

Total T4 and T3 and free T4. Because TSH levels change dynamically in response to alterations in T3, T4, a logical approach is first to determine whether TSH is suppressed, normal or elevated³. TSH is the only test necessary in most patients with thyroid nodules that clinically appear to be euthyroid. Most patients with solitary thyroid nodule in our study were euthyroid.

In our study only two patients (5.7%) had hyperthyroidism which is in accordance with observations¹³ where incidence of nodules presenting with deranged thyroid function test being 5.5%.

Keshri *et al.*,⁶ in their study observed 3% patients had TFT suggestive of hyperthyroidism and 2% hypothyroidism. Study⁸ observed hyperthyroidism in 10.9% cases with solitary thyroid nodule. Similar observations 7%¹¹, and 4%¹².

6. Fine Needle Aspiration Cytology

In our study, as per FNAC report, colloid goitre was the most common observation (51.4%) followed by adenomatous goitre (17.1%). Papillary and medullary carcinoma was seen in 14.3% and 2.9% respectively. Suspicious FNAC report was given in 2 cases (5.7%).

Fine needle aspiration cytology has become the initial test in most patients because it is safe and inexpensive and leads to a better selection patient for surgery than any other test¹⁵. Provided that an adequate specimen is obtained three cytological results are possible: Benign, Suspicious, Malignant and Indeterminate. The reported accuracy of cytological diagnosis ranges from 70%-97%²².

Keshri *et al.*,⁶ on FNAC observed that 58% of nodules were benign and 12% were malignant. Out of the total 58 benign samples, 25 (43%) of benign lesion were colloid nodule. Study²³ of 50 cases observed following FNAC findings: Benign (64%), suspicious (20%), malignant (10%) and indeterminate (6%). In¹⁰ a large series also showed colloid goitre as the most common observation in FNAC (53%) followed by adenomatous goitre (19.1%). Malignancy was reported in 6% while 20% of thyroid lesions showed follicular cells¹⁰.

7. Histopathological Examination

As per histopathology report, colloid goitre (31.4%) was the most common observation in cases of solitary

thyroid nodule followed by multinodular goitre (20%) and adenomatous goitre (17.1%). Other findings included follicular adenoma (8.6%), papillary carcinoma (14.3%), follicular variant of papillary carcinoma (5.7%) and medullary carcinoma (2.9%). Out of total 35 cases, 77.1% were benign pathologies while 22.9% were malignant pathologies. Most common benign lesion was colloid goiter (31.4%) followed by multinodular goitre (20%) while most common malignant lesion was papillary carcinoma (14.3%) followed by medullary carcinoma (2.9%).

This is similar to study¹³ incidence of malignant lesions was 14% while 86% were benign pathologies. In the study⁶ 79% of clinically diagnosed solitary nodules were benign and 21% of nodule were malignant. Most common benign nodule was benign follicular adenoma (31%) followed by colloid nodule (24%) while prevalence of multinodular goitre was 17%. Most common malignant lesion was papillary carcinoma (13%) followed by medullary carcinoma (3%). In another similar study⁷, out of 162 cases, 138 (85.18%) were diagnosed as non-neoplastic lesions, while the rest 24 (24.82%) were diagnosed as a neoplastic entity. Among the 138 non-neoplastic lesions, the commonest lesion was colloid goitre seen in 56 cases while papillary carcinoma was the commonest malignant lesion. The prevalence of malignant lesion as observed by other studies 10.8%⁸, 18%²³, and 4.16%²⁴.

8. Conclusion

The present study is a descriptive study of 35 cases of solitary thyroid nodule admitted in tertiary care centre during the period of August 2015 to December 2017. The following conclusions can be drawn:

- Solitary nodule of thyroid is more common in the age group of 20-40 years.
- Solitary nodule of thyroid is more common in females.
- Most of the patients with solitary nodule of thyroid present with swelling alone.
- After evaluation of solitary nodule of thyroid, 20% of all the clinically solitary thyroid nodule turned out to be multinodular goitre.
- Most of the patients with solitary nodule of thyroid are in euthyroid state and only few present with toxicity.

- Common causes of solitary nodule of thyroid are colloid goitre (31.4%), multinodular goitre (20%), adenomatous goiter (17.1%) and follicular adenoma (8.6%). Incidence of malignancy of solitary thyroid nodule is about 22.9%.
- USG can be used to detect multinodular goitre in patients presenting with solitary nodule of thyroid.
- FNAC is the investigation of choice in the evaluation of solitary nodule of thyroid. It has few pitfalls. In such situations, only histopathology can confirm the exact pathology. It detects papillary carcinoma in a solitary thyroid nodule with high sensitivity and specificity.
- Papillary carcinoma is most common malignancy of thyroid followed by follicular carcinoma.

9. References

1. Cole WH, Majarakis JD. Incidence of carcinoma of thyroid in nodular goiter, *J. Clin. Endocrinol.* 1949; 9:1007–11. <https://doi.org/10.1210/jcem-9-10-1007>. PMID: 18142433.
2. Bentley AA, Gillespie C, Malis D. Evaluation and management of a solitary thyroid nodule in a child, *Otolaryngol Clin. North Am.* 2003; 36:117–28. [https://doi.org/10.1016/S0030-6665\(02\)00131-7](https://doi.org/10.1016/S0030-6665(02)00131-7).
3. Harrison BJ, Maddox PR, Smith DM. Disorders of thyroid gland. In: Cuschieri A, Steele RJ, Moossa AR, editors. *Essential Surgical Practice*. 4th ed. London: Arnold; 2002. p. 95–110.
4. Dorairajan N, Jayashree N. Solitary nodule of the thyroid and the role of fine needle aspiration cytology in diagnosis, *J. Indian Med. Assoc.* 1996; 94:50–2,61.
5. Belfiore A, La Rosa GL. Fine-needle aspiration biopsy of the thyroid, *Endocrinol Metab. Clin. North Am.* 2001; 30:361–400. [https://doi.org/10.1016/S0889-8529\(05\)70191-2](https://doi.org/10.1016/S0889-8529(05)70191-2).
6. Shyam Prasad Keshri. Clinico-Pathological Study of Solitary Thyroid Nodule with Special Reference to Fine Needle Aspiration Cytology, *IJSR.* 2017; 6(2):789–94.
7. Prakash H Muddegowda. Panoramic ultrasound of the thyroid, *Int. J. Med. Health Sci.* 2012; 1(1):19–23.
8. Sarda AK, Gupta A, Jain PK, Prasad S. Management options for solitary thyroid nodules in an endemic goitrous area, *Postgrad. Med. J.* 1997; 73:560–64. <https://doi.org/10.1136/pgmj.73.863.560>. PMID: 9373596, PMCID: PMC2431457.
9. Williams N, O'Connell PR, editors. *Bailey and Love's Short Practice of Surgery* 26E. Crc Press; 2013 Feb 18.
10. Boyd LA, Earnhardt RC, Dunn JT, et al. Preoperative evaluation and predictive values of fine needle aspiration and frozen section of thyroid nodules, *J. Am. Coll. Surg.* 1998; 187:494–502. [https://doi.org/10.1016/S1072-7515\(98\)00221-X](https://doi.org/10.1016/S1072-7515(98)00221-X).
11. Fenn AS et al. Solitary thyroid nodules of thyroid gland- A review of 342 cases, *Indian J. Surg.* 1980 April; 42:175–77.
12. Zeki Acun MD, Mustafa Comert MD, Alper Cihan MD, Suat Can Ulukent MD, Bulent Ucan MD, Guldeniz Karadeniz C. Akmak: Near-Total Thyroidectomy could be the best treatment for thyroid disease in endemic Regions, *Arch. Surg.* 2004; 139:444–47. <https://doi.org/10.1001/archsurg.139.4.444>. PMID: 15078715.
13. Tarrar AM, Wahla MS, Ilyas S, Khan OU, Waqas A, Raza A. Solitary Thyroid Nodule; Frequency of Malignancy at Combined Military Hospital Rawalpindi, *Professional Medical Journal.* 2010 Oct 1; 17(4).
14. Raza S, Saeed Z, Raza H, Ahmed M. FNAC in the management of solitary thyroid nodule, *Professional Med. J.* 2006; 13(4):596–603.
15. Sarfraz T, Ullah K, Muzaffar M. The frequency and histological types of thyroid carcinoma in northern Pakistan, *Pak. Armed. Forces Med. J.* 2000; 50(2):98–101.
16. Wong CK, Wheeler MH. Thyroid Nodules: Rational management, *World J. Surg.* 2000; 24:934–41. <https://doi.org/10.1007/s002680010175>. PMID:10865037.
17. Christensen SB, Bondeson L, Ericsson UB, Lindholm K. Prediction of malignancy in the solitary thyroid nodule by physical examination, thyroid scan, fine-needle biopsy and serum thyroglobulin. A prospective study of 100 surgically treated patients.
18. McCoy KL, Jabbour N, Ogilvie JB, Otori NP, Carty SE, Yim JH. The incidence of cancer and rate of false-negative cytology in thyroid nodules greater than or equal to 4 cm in size, *Surgery.* 2007 Dec 31; 142(6):837–44. <https://doi.org/10.1016/j.surg.2007.08.012>. PMID: 18063065.
19. Moon WJ, Jung SL, Lee JH, Na DG, Baek JH, Lee YH, et al. Benign and malignant thyroid nodules: US differentiation–multicenter retrospective study, *Radiology.* June 2008; 247:762–70. <https://doi.org/10.1148/radiol.2473070944>. PMID: 18403624.
20. Takashima S, Fukuda H, Nomura N, Kishimoto H, Kim T, Kobayashi T. Thyroid nodules: Reevaluation with ultrasound, *J. Clin. Ultrasound.* 1995; 23(3):179–84. <https://doi.org/10.1002/jcu.1870230306>. PMID: 7730464.
21. Enrico Papini, Rinaldo Guglielmi, Antonio Bianchini, Anna Crescenzi et al. Risk of Malignancy in Nonpalpable Thyroid Nodules: Predictive Value of Ultrasound and Color-Doppler Features, *The Journal of Clinical Endocrinology and Metabolism.* May 1 2002; 87(5):1941–46. <https://doi.org/10.1210/jc.87.5.1941>.
22. Hamberger B, Gharib H, Melton LJ III, Goellner JR, Zinsmeister AR. Fine needle aspiration cytology of thyroid

- nodules: impact on thyroid practice and cost of care, *Am. J. Med.* 1982; 73:381–84. [https://doi.org/10.1016/0002-9343\(82\)90731-8](https://doi.org/10.1016/0002-9343(82)90731-8).
23. Kaur K, Sonkhya N, Bapna AS, Mital P. A comparative study of fine needle aspiration cytology, ultrasonography and radionuclide scan in the management of solitary thyroid nodule: A prospective analysis of fifty cases, *Ind. J. Otolaryngol head neck surg.* 2002 June; 54(2):96–101.
24. Mundasad B, Mcallister I, Carson J, Pyper P. Accuracy of fine needle aspiration cytology in diagnosis of thyroid swellings, *Internet J. Endocrinol.* 2006; 2(2):15–19. <https://doi.org/10.5580/484>.
-

How to cite this article: Bhamre S., Chaudhari S. Clinical Study of Solitary Nodule of Thyroid at Tertiary Health Centre. *MVP J. Med. Sci.* 2019; 6(1):15-21.