

Evaluation of Variations of Maxillary Sinus on Computed Tomography

Abhay G. Kakade¹, Nilesh H. Chaudhari¹, Sumit M. Baviskar², Rounak R. Bagga^{3*} and Zoya M. Patni³

¹Associate Professor, Department of Radio-diagnosis, Dr. Vasantrao Pawar Medical College Hospital and Research Centre, Nashik - 422003, Maharashtra, India; drabhaykakade@gmail.com, nilsrad777@gmail.com

²Assistant Professor, Department of Radio-diagnosis, Dr. Vasantrao Pawar Medical College Hospital and Research Centre, Nashik - 422003, Maharashtra, India; baviskar.sumit54321@gmail.com

³PG Resident, Department of Radio-diagnosis, Dr. Vasantrao Pawar Medical College Hospital and Research Centre, Nashik - 422003, Maharashtra, India; dr.drounakbagga@gmail.com, zoya.patni@gmail.com

Abstract

Background: Maxillary sinus although shows normal anatomical variations and it is important to know about them. Evaluating maxillary sinus and identifying its variations on Computed Tomography not only detects the different variations but also helps in planning and guiding Various Sinus Surgery and preventing possible complications. **Purpose:** Aim of this study was to detect anatomical variations of maxillary sinuses in patients using Multi-detector Computed Tomography. **Materials and Methods:** Paranasal sinuses of 130 patients who were subjected to Computerised Tomography of Paranasal Sinus with CT (Seimens 128 slice Somatom Perspective) machine were studied. **Results:** A total PNS Para Nasal Sinuses of total 130 patients were studied. Out of which only 36 patients had maxillary sinu variations. Among accessory ostia of maxillary sinus was the commonest anatomical variation and was seen in 23 (18%) of cases. Hyperpneumatization of maxillary sinus was detected in 7cases (5%) and Antral septa were found in 13 cases (10%). **Conclusion:** Thus, it's important to accurately assess the maxillary sinus on Computed Tomography and to determine the various anatomical variations of the same so as to differentiate pathological lesions from an anatomical variation and avoiding unnecessary surgical explorations and complications.

Keywords: Computerised Tomography (CT), Functional Endoscopic Sinus Surgery (FESS), Paranasal Sinuses (PNS)

1. Introduction

Computed tomography provides an excellent image with multiplanar reformats to identify various details of the paranasal sinuses including the maxillary sinus. A precise knowledge about the various normal anatomical variations of maxillary sinus is essential to understand the impact of it in the disease process and management. Also,

with the advent of various new techniques of surgeries it's important to know about exact anatomical details of the maxillary sinuses to guide the surgeons and thus preventing the avoidable complications.

The maxillary sinuses are pyramidal shaped cavities located in the face lateral to the nasal cavity on either side with its base directed towards the lateral nasal wall and apex extends to the zygomatic process of maxilla¹. The various anatomic variations

*Author for correspondence

of maxillary sinuses seen are hyper-pneumatization, hypoplasia, antral septa and variations in location of the arteries².

This article emphasizes on the various anatomical variations of maxillary sinuses.

2. Aims and Objectives

To evaluate the normal anatomical variations of Maxillary sinus using Computed Tomography.

3. Materials and Methods

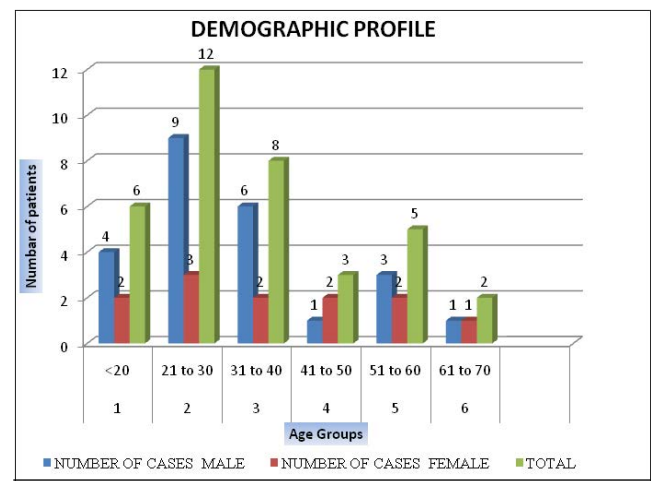
It is a retrospective study and was carried out for a period of 12 months. The CT PNS of 130 patients were performed who were referred to the Department of Radio diagnosis at Dr. Vasantao Pawar Medical College, Hospital and Research Centre, Nashik. The clinical and demographic data were recorded after due consent. The patients with tumours, polyposis, previous trauma or surgery were excluded from the study. Computed Tomography optimally displays air within the sinuses, soft tissue and bony structure and thus provides an excellent depiction of the anatomy as well as the disease extent, in and around the sinuses.

All the patients were subjected to computerized tomography of the PNS with CT (Seimens 128 slice Somatom Perspective) machine. Direct scans of 1 mm thickness with an increment of 0.5 mm were made. Multiplanar reconstruction was done in axial, coronal, and sagittal planes. For the axial scans the orbito-meatal line was taken as reference with the patient in supine position. The exposure settings used were 100 kVp and 300 to 325 mAs. For the evaluation of maxillary sinus septations the axial images were used. Whereas for evaluation of the presence of mucosal thickening on the maxillary sinus floor and patency of the antral sinus ostium the coronal images were used.

4. Results

The present study was carried out to describe normal anatomical variations of maxillary sinus. Only patients fulfilling the inclusion and the exclusion criteria were

included in the study. Findings in the patients studied were tabulated using Microsoft Excel software. During the period of 24 months of the study, total 130 patients were studied. Out of 130 patients 36 patients i.e., 27.7% patients have anatomical variations in the maxillary sinus. The demographic profile of the patients with variations in the maxillary sinus were given in (Figure 1) with the sex distribution of the same mentioned in (Figure 2). The incidences of different anatomical variations of the maxillary sinus were detailed in (Table 1) with accessory ostia being the most common anatomical variations and was seen in 23 patients out of 130 (i.e. 18%). Maxillary sinus hypoplasia was not seen in any patient in this study.



Males in² 1 – 40 years formed the bulk of study i. e. 15 (41.6%).

Figure 1. Demographic Profile.

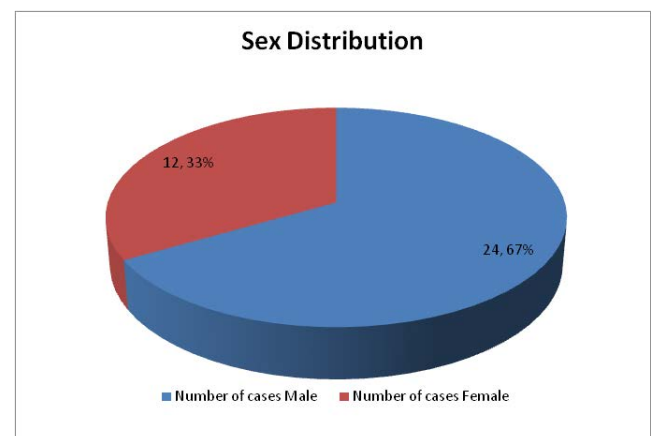


Figure 2. Sex distribution.

Table 1. Types of maxillary sinus variations

Variations of maxillary sinus			
Sr. No.	Variations	Present in number of cases	Percentages
1	Hyperpneumatized	7	5%
2	Septae	13	10%
3	Accessory Ostia	23	18%

The most common variation of maxillary sinus is accessory ostia and is seen in 23 cases comprising 18%.

5. Discussion

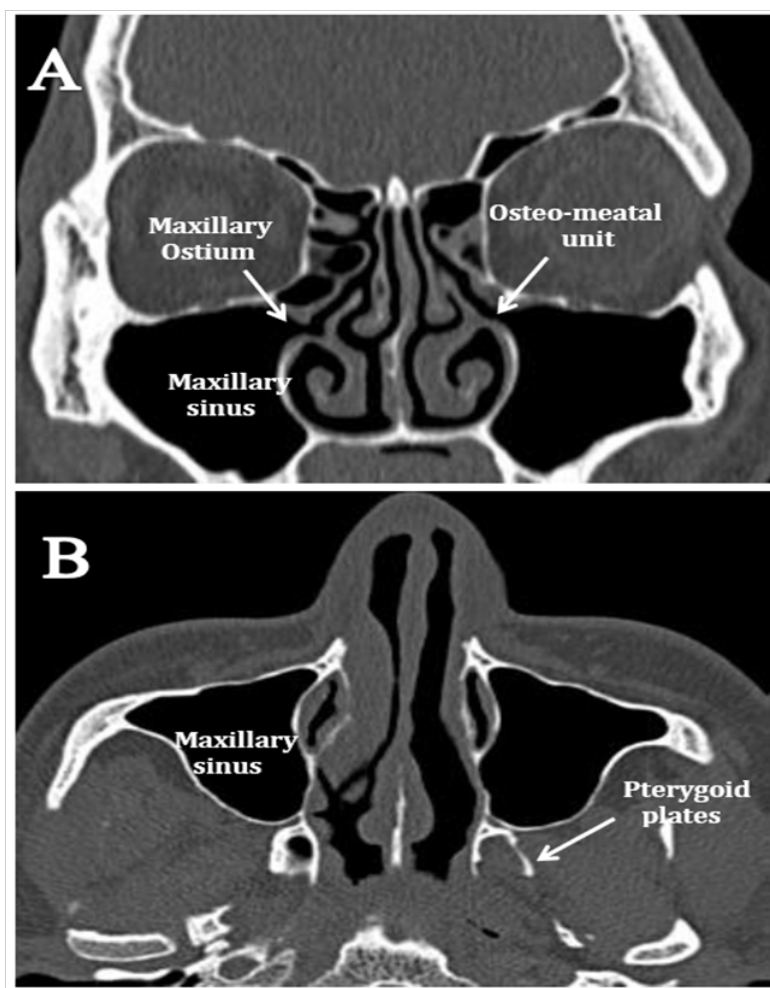
Normal anatomical variations and congenital anomalies in the paranasal sinus region are significant findings

as they at times have pathological consequence or may be the source of difficulty/complication during sinus surgeries. CT is the preferred modality for evaluation of paranasal sinuses. Although the associations of the normal variations with sinusitis is not exactly known, detailed anatomical knowledge of maxillary sinus and their normal anatomical variations should be pursued before any surgical intervention to avoid potential dreadful complications.

6. Variations of Maxillary Sinus

6.1 Maxillary Sinus Hypoplasia

It is not a common condition and so is misdiagnosed as chronic sinusitis³. Failure to recognize maxillary sinus hypoplasia during the endoscopic surgery can lead



A. Coronal CT image shows normal maxillary sinus and ostium (arrow).
 B. Axial CT image shows normal maxillary sinus.

Figure 3. Normal maxillary sinus.

to injury to the medial orbital wall⁴. In such cases it is difficult to find the maxillary sinus ostium.

6.1.1 Classification of Maxillary Sinus

Hypoplasia⁴

There are three distinct types of hypoplasia as follows:

Type I. Mild sinus hypoplasia:

- Normally development of uncinata process as well as of infundibular passage.

Type II. Significant sinus hypoplasia:

- Absence or hypoplasia of uncinata process, indistinct infundibular passage and complete opacification of affected sinus.

Type III. Profound sinus hypoplasia:

- Absence of uncinata process. Sinus is seen as a shallow cleft in the lateral wall of the nasal cavity.

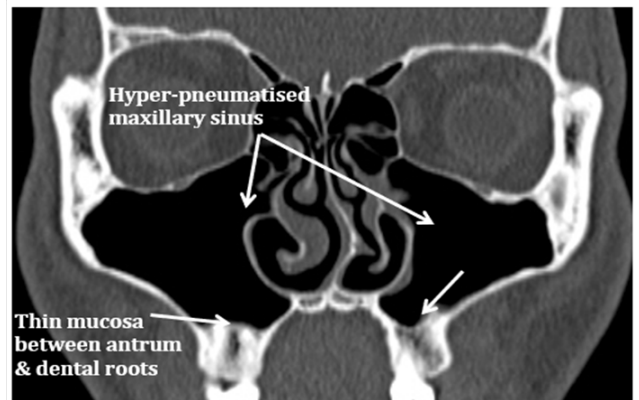
The incidence of maxillary sinus hypoplasia has been reported in literatures as being very uncommon and is mainly detected on the coronal sections of CT scan. Maxillary sinus hypoplasia is many a time associated with frontal sinus hypoplasia, thickened bony sinus wall, mucosal pathology, orbital enlargement, variation of anterior ethmoidal cell, therefore to prevent complications these anatomical variations must be identified prior to surgery⁵. Bolger *et al.*,⁴ reported incidence of maxillary sinus hypoplasia as 10.4% while in Kantarci *et al.*,⁶ maxillary sinus hypoplasia was seen in 7% in a study of 512 patients. Zinreich *et al.*,⁷ found the incidence of unilateral hypoplasia of maxillary sinus as 10.4%. In our study Maxillary sinus hypoplasia was not seen.

7. Hyper-pneumatized Maxillary Sinus

Rarely there is dehiscence of bone over the maxillary tooth roots, often over the roots of molars or premolars with a thin mucosal lining between the antrum and the roots⁸ (Figure 4). These can lead to oroantral fistula formation following the tooth extraction or also can predispose to recurrent sinusitis from dental infection⁹.

Maxillary Sinus Variations

Hyperpneumatized Maxillary Sinus



Coronal CT image shows a thin mucosal lining between the maxillary antrum and the dental roots (arrow).

Figure 4. Hyperpneumatized maxillary sinus.

8. Septage Within the Maxillary Sinus

These are uncommon, and septa usually divide the maxillary antrum into anterior and posterior parts, each of them may drain via accessory ostia into the nasal fossa. Very rarely, a horizontal septum can divide the maxillary antrum into superior and inferior parts, or the maxillary antrum may be divided by a sagittal septum into medial and lateral parts¹⁰. These septae can affect the maxillary drainage pathways¹¹.

According to John Earwaker¹², maxillary sinus showed septations in about 19 cases out of 800 patients studied. The incidence of antral septa in the report of Velasquez- Plata *et al.*,¹³ from the University of Detroit, Michigan, USA, was in 24% on CT scan analysis of maxillary sinuses, Won-Jin¹⁴ reported a prevalence of 24.6%, among Koreans in Jeonju, and the antralseptal prevalence reported by Ulm¹⁵, (18.3%), from the University of Vienna, Austria. In our study maxillary sinus septations was seen in about 10%, Krenmair *et al.*,¹⁶ (14.3%), from the University of Vienna, Austria.

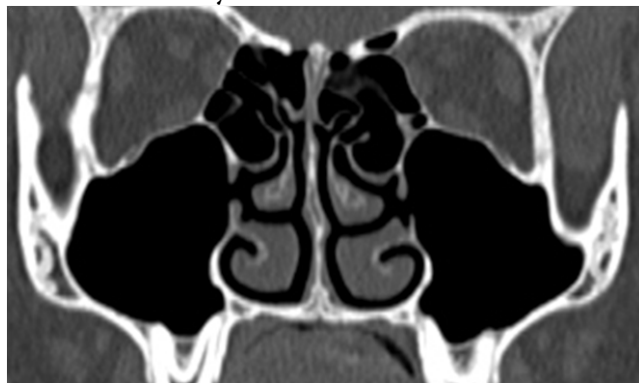9. Accessory Ostia of Maxillary Sinus

Accessory ostium drains into either the infundibulum or more commonly into the posterior fontanel, behind the

natural ostia¹⁷ (Figure 5). To prevent recurrent sinusitis, it's important to connect both natural & accessory ostia¹⁸.

Accessory Maxillary Ostium (AMO) may have a role in the development of maxillary sinusitis¹⁹. Although still it is not known whether AMO is a congenital or whether it's an acquired structure some investigators suggest that the accessory ostium may develop after acute maxillary sinusitis²⁰. AMO was seen in 19.1% patients in a study Yenigun *et al.*,¹⁹. According to Earwaker¹² the prevalence of AMO was seen in 14%. In the present study, 18% of patients had AMO.

Bilateral Accessory Ostia



Coronal CT image showing bilateral accessory ostia draining into the middle meatus on either side (arrows).

Figure 5. Bilateral accessory ostia in maxillary sinus.

10. Conclusion

Accurate imaging assessment of maxillary sinus reveals anatomical variations of the maxillary sinus on Multi-detector Computed Tomography and it is important to detect them so as differentiate between pathological lesion form and anatomical variation. Since some of these variations can modify the surgical planning to more specialized procedures, they are crucial to be recognized and mentioned to avoid unnecessary surgical explorations and potential complications. Today Computed Tomography is an integrated diagnostic method for assessing the maxillary sinus variations.

11. References

1. Orhan K, Kusakci Seker B, Aksoy S, Bayindir H, Berberoğlu A, Seker E. Cone beam CT evaluation of maxillary sinus septa prevalence, height, location and morphology in children and an adult population, *Medical Principles Practice*. 2013; 22:47–53. <https://doi.org/10.1159/000339849>.
2. Lana JP, Carneiro PM, Machado Vde C, de Souza PE, Manzi FR, Horta MC. Anatomic variations and lesions of the maxillary sinus detected in cone beam computed tomography for dental implants, *Clin Oral Implants Research*. 2012; 23:1398–403. <https://doi.org/10.1111/j.1600-0501.2011.02321.x>. PMID: 22092889.
3. Vinson RP, Collette RP. Maxillary sinus hypoplasia masquerading as chronic sinusitis, *Postgraduate Medical Journal*. 1991; 89:189–90. <https://doi.org/10.1080/00325481.1991.11700871>.
4. Bolger WE, Woodruff WW, Morehead J, et al. Maxillary sinus hypoplasia: Classification and description of associated uncinete process hypoplasia, *Otolaryngology Head Neck Surgery*. 1990; 103(5):759–65. <https://doi.org/10.1177/019459989010300516>. PMID: 2126098.
5. Betts NJ, Miloro M. Modification of the sinus lift procedure for septa in the maxillary antrum. *Journal of Oral Maxillofacial Surgery*. 1994; 52:332–3. [https://doi.org/10.1016/0278-2391\(94\)90313-1](https://doi.org/10.1016/0278-2391(94)90313-1).
6. Kantarci M, Karasen RM, Alper F, Onbas O, Okur A, Karaman A. Remarkable anatomic variations in paranasal sinus region and their clinical importance, *European Journal of Radiology*. 2004; 50:296–302. PMID: 15145491. <https://doi.org/10.1016/j.ejrad.2003.08.012>.
7. Zinreich SJ. Paranasal sinus imaging, *Otolaryngology Head Neck Surgery*. 1990; 103(5):868–69. <https://doi.org/10.1177/01945998901030S505>.
8. Ritter R. *The Paranasal Sinuses: Anatomy and Surgical Technique*. 2nd ed. St. Louis: CV Mosby; 1978.
9. athananthar S, Nagaonkar S, Paleri V, et al. Canine fossa puncture and clearance of the maxillary sinus for the severely disease maxillary sinus, *Laryngoscope*. 2005; 115:1026–29. <https://doi.org/10.1097/01.MLG.0000162651.22019.4A>. PMID: 15933514.
10. Peter M. Som, William Lawson, Girish M. Fatterperkar, S. James Zinreich, Joel Shugar. Section I: Midface and Sinonasal cavities, Chapter 2: Embryology, Anatomy and Physiology and Imaging of the Sinonasal Cavities in *Head and Neck Imaging*, 5th edition, St. Louis: CV Mosby; 2011; 99–140.
11. Sarna A, Hayman A, Laine F, et al. Coronal imaging of the ostiomeatal unit: Anatomy of 24 variants, *Journal of Computer Assisted Tomography*. 2002; 26(1):153–7. <https://doi.org/10.1097/00004728-200201000-00027>. PMID: 11801923.
12. Earwaker J. Anatomic variants in sinonasal CT, *Radiographics*. 1993;13(2):381–415. <https://doi.org/10.1148/radiographics.13.2.8460226>. PMID: 8460226.
13. Velasquez-Plata D, Hovey LR, Peach CC, Alder ME. Maxillary sinus septa: A 3 dimensional computerized tomo-

- graphic scan analysis, *The International Journal of Oral and Maxillofacial Implants*. 2002; 17:854–60. PMID: 12507246.
14. Lee WJ, Lee SJ, Kim HS. Analysis of location and prevalence of maxillary sinus septa, *Journal Periodontal Implant Science*. 2010; 40:56–60. <https://doi.org/10.5051/jpis.2010.40.2.56>. PMID: 20498761, PMCID: PMC2872816.
 15. Ulm CW, Solar P, Krennmair G, Matejka M, Watzek G. Incidence and suggested surgical management of septa in sinus lift procedures, *The International Journal of Oral and Maxillofacial Implants*. 1995; 10:462–65. PMID: 7672849.
 16. Krennmair G, Ulm CW, Lugmayr H. Maxillary sinus septa: Incidence, morphology and clinical implications, *Journal Cranio-maxillofacial Surgery*. 1997; 25:261–65. [https://doi.org/10.1016/S1010-5182\(97\)80063-7](https://doi.org/10.1016/S1010-5182(97)80063-7).
 17. Jog M, McGarry GW. How frequent are accessory ostia? *Journal of Laryngology Otolaryngology*. 2003; 117:270–72. <https://doi.org/10.1258/00222150360600869>. PMID:12816215.
 18. Wormald PJ. Uncinectomy and middle meatal antrostomy including canine fossa puncture/trephine. In: Wormald PJ, editor. *Endoscopic sinus surgery: Anatomy, three-dimensional reconstruction and surgical technique*. 3rd edition. New York: Thieme Medical Publishers; 2013. p. 28–44.
 19. Yenigun A, Fazliogullari Z, Gun C, Uysal II, Nayman A, Karabulut AK. The effect of the presence of the accessory maxillary ostium on the maxillary sinus, *European Archives of Oto-Rhino-Laryngology*. 2016; 273:4315–19. <https://doi.org/10.1007/s00405-016-4129-8>. PMID: 27300297.
 20. Genc S, Ozcan M, Titiz A, Unal A. Development of maxillary accessory ostium following sinusitis in rabbits, *Rhinology*. 2008; 46:121–24. PMID: 18575013.