

Clinico-Pathological Study of Cervical Lymphadenopathy in a Tertiary Care Centre

Hemantkumar Borse¹ and Aakash Bhamre^{2*}

¹Professor, Department of Surgery, Dr. Vasant Rao Pawar Medical College, Hospital and Research Centre, Adgaon - 422003, Nashik, Maharashtra, India; drhborse@gmail.com

²PG Resident, Department of Surgery, Dr. Vasant Rao Pawar Medical College, Hospital and Research Centre, Adgaon - 422003, Nashik, Maharashtra, India; aakashbhamre07@gmail.com

Abstract

Introduction: Cervical lymphadenopathy is common in India and may present as diagnostic problem to the clinician. Diseases affecting cervical lymph nodes are of varying severity starting from simple curable infection to difficult incurable malignant disease. **Objective:** The purpose of this study was to observe the various clinical presentations of cervical lymphadenopathy and correlate histopathological findings with the clinical diagnosis. **Methods:** A cross sectional study was conducted during the period from August 2015 to December 2017 at a tertiary care centre on 50 patients presenting with cervical lymphadenopathy. **Results:** In this series, tissue diagnosis by biopsy found Tuberculosis (TB) 74% cases, metastatic carcinoma in 12%, and non-specific reactive hyperplasia in 10% and lymphoma in 4% cases. Seventy six percent cases were below 40 years of age. **Conclusion:** Thirty-Seven (74%) cases were diagnosed clinically as tubercular lymphadenitis, 05(10%) as metastatic carcinoma, 06(12%) non-specific reactive hyperplasia and 02(4%) cases were of lymphoma which was nearly similar to histopathological diagnosis.

Keywords: Biopsy, Cervical Lymphadenopathy, Fine Needle Aspiration Cytology (FNAC), Non-Specific Reactive Hyperplasia, Tubercular Lymphadenitis

1. Introduction

There are approximately 800 lymph nodes in the body. More than 300 of them lie in the neck which is involved in the various pathological conditions. Lymphadenopathy is a disease process which involves lymph nodes that are abnormal in consistency and size. Lymphadenitis refers specifically to lymphadenopathies which are caused due to inflammatory processes.

Lymphadenopathy is one of the most common clinical manifestations of many diseases. It is defined as an abnormality in the size and character of the lymph nodes caused by the invasion or propagation of either inflammatory cells or neoplastic cells into the lymph node¹.

Cervical lymphadenopathy is defined as any cervical lymph nodal tissue more than 1cm in diameter. It may affect any age group; however, the possible cause for such adenopathy varies in each age group². The enlargement of these lymph nodes is quite significant in that there so many etiological agents and is an index of spread of infection and malignancy. The evaluation of lymph node enlargement in the neck is not an easy task and the diagnosis of this condition is a difficult task because most of the diseases resemble each other. Improper diagnosis and the treatment may convert a potentially curable one into incurable.

The purpose of this study is to describe the pattern of lymphadenopathy with demographic and clinical profiles

*Author for correspondence

of the patients presenting in the outpatient department of an Indian hospital. This would help the doctors attending patients in India to have a basic idea about prevalence of different clinical profiles of cervical lymphadenopathy for easier case detection and better therapeutic outcome. The study intends to find out systematically the various pathological conditions presenting with enlarged lymph nodes in the neck, also the various modes of clinical presentation and behaviour of these conditions.

2. Materials and Methods

This cross-sectional study was carried out over a period from August 2015 to December 2017. The study was conducted on 50 patients visiting the OPD &/or admitted in the IPD for Lymph node enlargement(s) in the neck during the above-mentioned period of evaluation at a tertiary care centre. Exclusion criteria included the cases which did not come for regular follow-up and who did not complete or receive any medical or surgical treatment and cases who were not willing to be part of this study. A detailed history was taken and a thorough clinical examination with careful attention to the involved lymph nodes and its draining area was done. After making a clinical diagnosis, further investigations were carried out. Radiological investigations and endoscopy were carried out in relevant cases. Fine Needle Aspiration Cytology (FNAC)/Lymph node biopsy was done in all the 50 cases and diagnosis was confirmed by histology.

3. Observations and Results

Table 1. Age distribution of study participants

Age group (yrs)	N	%
<= 20	13	26.0%
21-40	25	50.0%
41-60	11	22.0%
> 60	1	2.0%
Total	50	100.0%

Mean age - 28.32 +/- 4.16 years

Table 2. Distribution of cases as per clinical diagnosis

Clinical Diagnosis	N	%
Tuberculosis	37	74.0%
Chronic NSL	6	12.0%

Secondaries	5	10.0%
Hodgkins	2	4.0%
Total	50	100.0%

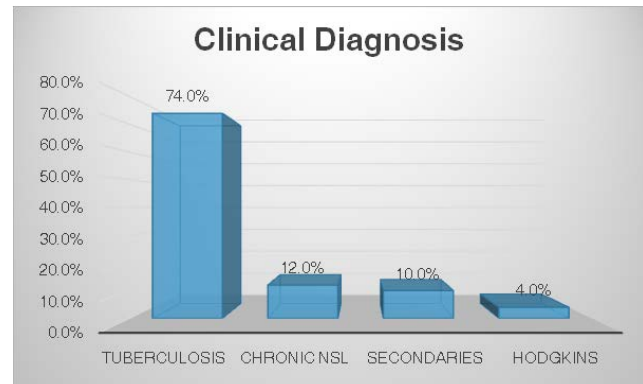


Figure 1. Clinical diagnosis in study participants.

Table 3. Distribution of cases as per histopathological diagnosis

Histopathological Diagnosis	N	%
Tuberculosis	37	74.0%
Chronic NSL	5	10.0%
Secondaries	6	12.0%
Hodgkins	2	4.0%
Total	50	100.0%

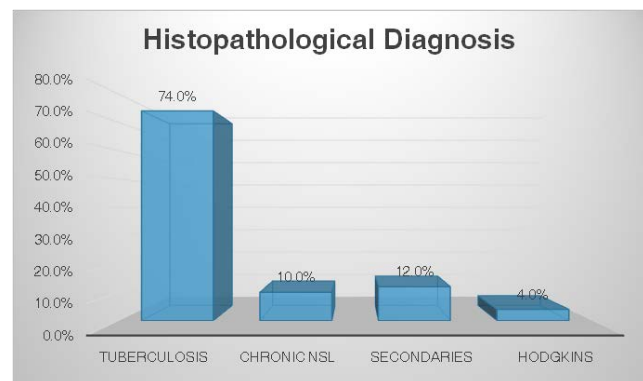


Figure 2. Distribution of cases as per histopathological diagnosis.

4. Discussion

The study intends to find out systematically the various pathological conditions presenting with enlarged lymph nodes in the neck, also the various modes of clinical presentation and behaviour of these conditions. This study involved 50 cases presenting with cervical lymphadenopathy. The study was conducted at tertiary

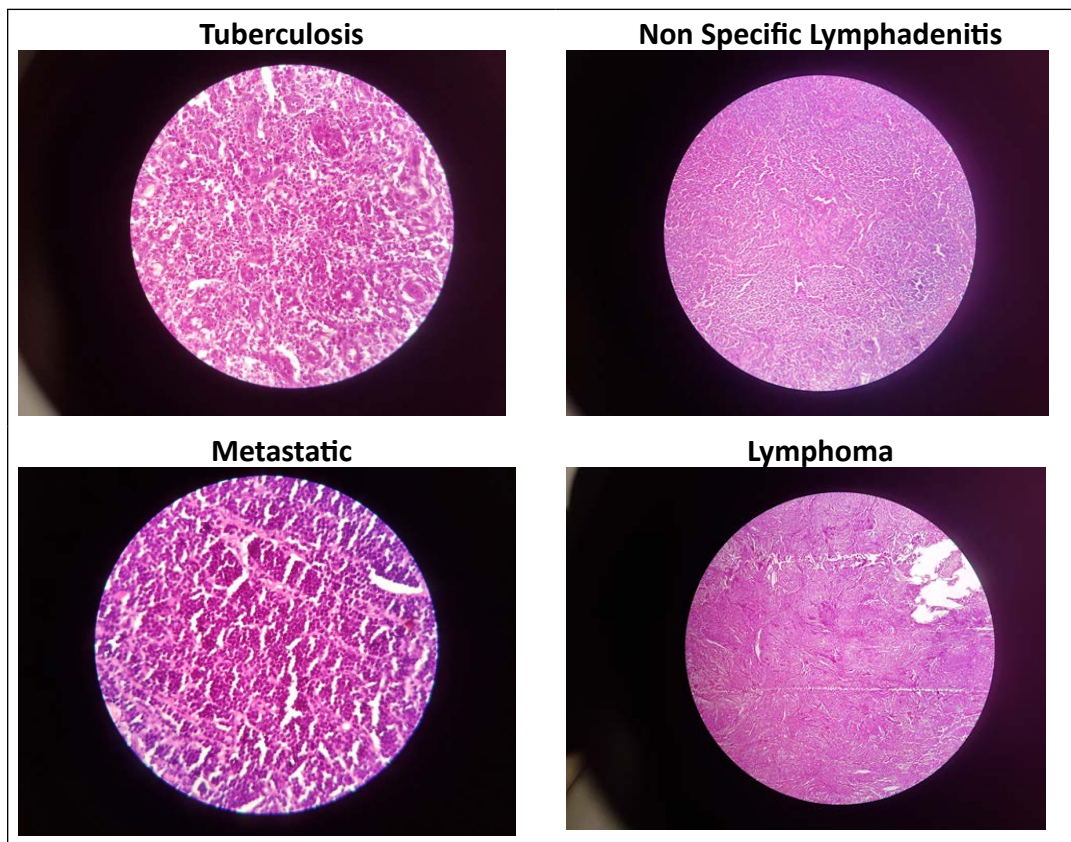


Figure 3. Microscopic findings on Histopathology.

Table 4. Association of age with type of lesion

Age Group	Diagnosis				Total
	Tuberculosis	Chronic NSL	Secondaries	Hodgkins	
<= 20	10	3	0	0	13
21-40	21	2	1	1	25
41-60	6	0	4	1	11
> 60	0	0	1	0	1
Total	37	5	6	2	50

Table 5. Correlation of clinical and histopathological diagnosis

Clinical Diagnosis	Histopathological Diagnosis				Total
	Tuberculosis	Chronic NSL	Secondaries	Hodgkins	
Tuberculosis	36	1	0	0	37
Chronic NSL	1	4	1	0	6
Secondaries	0	0	5	0	5
Hodgkins	0	0	0	2	2
Total	37	5	6	2	50

care hospital, Data has been analysed with regard to age and sex of patients, presenting complaints and other symptoms, clinical findings, examination findings and histological investigations

4.1 Aetiology of Cervical Lymphadenopathy

Of all the 50 cases, 88% were benign lesions and 12% malignant lesions. In the benign lesions, it was observed that tuberculous lymphadenopathy was the commonest cause of cervical lymphadenopathy (74%) followed by chronic nonspecific lymphadenopathy (12%). In malignancy there were 10% secondaries and 4% cases of Hodgkins lymphoma (Table 2, Figure 1).

Similar etiological presentation has been reported by various other authors. Reported³ that on clinical diagnosis of 50 cases 38 cases were benign of which 26 cases were TB lymphadenitis (52%), and 12 cases (24%) nonspecific lymphadenitis noted. Remaining accounted for malignancy i.e. secondaries in the neck accounted for 10 cases (20%) and lymphomas 2 cases (4%). Which is in accordance with the findings of the present study?

In the reports⁴ of 359 patients 253 cases (86%) had tuberculous lymphadenitis 42 had nonspecific lymphadenitis 36 had secondaries and 18 had lymphomas. Analysis⁵ showed that the tubercular lymphadenitis ranked on the top (45.4%) followed by secondary metastasis from different other Primary malignancies (21.2%), Reactive hyperplasia (19.9%), lymphoma (7.0%), chronic granuloma (3.5%) and Non-specific inflammatory involvement of lymph node (2.8%). Also, observed⁶ that most common cause was TB lymphadenitis (49.5%), 2nd most common cause was reactive change (18.0%) followed by chronic non-specific lymphadenitis (12%), Non-Hodgkin's lymphoma (8%) and Hodgkin's lymphoma (5%) (Table 2).

TB lymphadenitis has also been seen to be the most common cause observed in young female (65.2%) in cases of cervical lymphadenopathy⁷.

Moreover, tuberculosis has previously been documented in several reports as the commonest cause of cervical lymphadenopathy in the tropics⁸. Furthermore, peripheral tuberculous lymphadenopathy has been reported as the commonest form of extra pulmonary tuberculosis⁹. However, a study¹⁰ reported that in their population, we found more malignancy and little TB, less than 10% of adults or children with a pathologically confirmed cause of cervical lymphadenopathy were diagnosed with TB.

This can be attributed the fact that Chronic lymphadenopathy in developing countries has a high incidence of tuberculosis. In countries with a high prevalence of tuberculosis, people are exposed more intensively.

4.2 Age incidence

In the present study, Mean age of the patients was 28.32 +/-4.16 years with 50% of the patients from 21-40 years of age group, 26% were less than 20 years of age, 22% in 40-60 years and there was only 1 patient above 60.

In the study¹¹ to clinico-pathologically assess the cases of cervical lymphadenopathy observed that maximum number of cases were in the age group of 21-30 years (36 cases, 36%). Next commonest age group involved was between 12-20 years (23 cases, 23%), (14 cases, 14%) cases were in the age group of 31-40 years and 12 cases were in the age group of 41-50 years. Only 6 cases were found to be above 60 years. Conducted a retrospective study¹² of cervical lymphadenitis, of which the mean age of presentation was 21-30 years, of which peak incidence was 23-26 years of age.

In a study¹³ the mean age was 26 years, whereas in the retrospective study¹⁴ the mean age of presentation was 25 years. The findings of our study compare well with these studies.

4.3 Age Predilection for Aetiology

In present study, (up to 20 years), the non-specific lymphadenitis/reactive hyperplasia seemed to be the most frequent form of lymph node disease and it was revealed to be significant, of the 5 cases of NSL in our study 3 patients were in this age group (Table 1).

On the other hand, in 21-40 years age group Tubercular lymphadenitis was the most common aetiology (21 cases) while Carcinomatous involvement of lymph node respectively were found to be significantly more frequent in above 40 years of age (Table 4).

As per the findings¹⁵ reactive hyperplasia was the most frequent form of lymphadenitis in children followed by granulomatous involvement.

Found that¹⁰ 50.4, 22.4, 4.8 and 10% diseased lymph node were involved in Reactive hyperplasia, TB, Malignancy and Granuloma respectively. Highest incidence of Cancer was seen in fifth decades (50.0%) whereas tubercular lymphadenopathy was found with increasing frequency through childhood (10.5%) and

adolescence (21.7%) to young adulthood (30.4%). Which is in accordance with the present study?

Another study¹⁶ reported in their study that reactive hyperplasia was most common (74.5%) in 1st two decades of life and tuberculosis of lymph nodes in 2nd and 3rd decades (58.9%). 88% of metastasis lymph nodes were found over 40 years of age.

Also, showed¹⁷ that peak TB lymphadenitis occurred in 2nd-3rd decades of life.

4.4 Clinico-Pathological Correlation

FNAC is the confirmatory diagnostic aid. It was done in all the cases. Of which 74% were tuberculous in origin and 10% cases were diagnosed as reactive lymphadenitis i.e. nonspecific lymphadenitis, cases of secondaries were 12% and there were 4% cases of Hodgkins lymphoma (Table 5).

All the 74% of the patients confirmed on FNAC were diagnosed clinically to have tuberculosis. In our study, Hodgkin's lymphoma was diagnosed clinically in 100% of the cases, while 100% of the metastatic lesions were provisionally diagnosed to have a malignancy based on clinical grounds. One of the patients with non-specific lymphadenitis was incorrectly diagnosed clinically and one of the secondaries was diagnosed histologically which was missed clinically. In the present study the histological diagnosis was taken as the final diagnosis (Figure 3).

In the present study, the overall accuracy of FNAC in diagnosis of cervical lymphadenopathy was found to be 94%. The findings of the present study were comparable with other studies.

Conducted a similar study⁶ on 100 patients and reported the accuracy of FNAC in their study was 82%. Reported the results¹⁸ were showing 92.8% accuracy for FNAC, which is exactly similar to the present study.

In the retrospective study¹⁹ the accuracy was found to be exactly the same as the present study, Reported similar results²⁰ of 83% accuracy.

Reported⁴ diagnostic accuracy of FANC was 97% in their study. In²¹ series FNAC accuracy was 88.3% and in²² series FNAC accuracy was 98%.

It can be thus suggested that FNAC forms an important diagnostic tool to aid in the diagnosis of cervical lymphadenopathy as FNAC is very cost effective.

5. Conclusion

Lymphadenopathy is a clinical manifestation of regional as well as systemic disease, which serves as an excellent

clue to diagnosis. It can arise either from benign or malignant causes. In our study, tuberculosis was found to be the most common cause of lymphadenopathy, followed by chronic non-specific lymphadenitis. Benign lesions are more common than malignant lesions in lymph nodes. Tuberculosis affects younger age group whereas, malignancies affect older age groups. The common group of lymph nodes affected in tuberculosis was jugulodigastric nodes followed by posterior triangle nodes.

Tuberculosis is an important disease, one of the commonest diseases affecting lymph nodes. It is curable with anti-tubercular drugs if administered according to WHO guidelines under RNTCP. A constitutional symptom in cervical tubercular lymphadenitis has limited significance and clinical behaviour can be highly variable. Early diagnosis and complete treatment will prevent further progression of the disease and helps to cure it.

Present study may act as source of knowledge regarding age-sex distribution of lymph node diseases, their mode of presentation and predilection for different aetiology groups. It can help the care giver doctors, especially at primary care level, to think in a systematic way for detection/referral of the respective cases early and thereby avoiding the diagnostic delay in cases like TB/ Metastasis of lymph nodes. It can be of very helpful for the urban or rural primary health care levels where, in many places, improved diagnostic facility to detect lymph node diseases is yet to be available due to scarcity of resources.

Fine needle aspiration cytology has higher accuracy for diagnosing tuberculous lymphadenitis, lymphomas, and secondary deposits.

It can also be concluded that FNAC is a reliable diagnostic tool in helping invasive surgical procedures undertaken in the diagnosis of tuberculous adenitis. The Ziehl-Neelsen stain to identify AFB should be incorporated as an adjunct to increase the diagnostic accuracy of tuberculous lymphadenitis. In cervical lymphadenopathy clinical evaluation followed by FNAC is most reliable diagnostic tool, which is easy to perform cost effective, speedy results can be obtained and accurate. The main requirement for this is the specialist input.

6. References

1. Gosche JR, Vick L. Acute, subacute, and Chronic Cervical Lymphadenitis in children, *Semin. Pediatr. Surg.* 2006; 15:99-106. <https://doi.org/10.1053/j.semped-surg.2006.02.007>. PMID: 16616313.

2. Bradbury AW. «Lymphedema» in Bailey and Love's Short Practice of Surgery, 24th Edition Arnold, 2004; 974p.
3. Bhatt JV, Shah JM, Shah F. Clinico-pathological profile of cervical lymphadenopathy: A prospective study, *J. Appl. Basic. Med. Sci.* 2002; 2(2):35-39 <http://www.nhlmmcgym.com/clinico-pathological-profile-cervical.htm>.
4. Fijten GH, Blijham GH. Unexplained lymphadenopathy in family practice. An evaluation of the probability of malignant causes and the effectiveness of physicians' workup, *J. Fam. Pract.* 1988; 27:373-76.
5. Buli G, Lukas F. Cytologic patterns of lymph node diseases in Hawassa University Referral Hospital, Southern Ethiopia, *Journal of Coastal Life Medicine.* 2015; 3:395-97. <https://doi.org/10.12980/JCLM.3.2015JCLM-2015-0024>.
6. Shaikh SM, Balochi I, Bhatti Y, Shah AA, Shaikh GS, Deenari RA. An audit of 200 cases of cervical lymphadenopathy, *Med. Channel.* 2010; 16(1):85-87.
7. Mukherjee AK. Tuberculosis control programme in India: Progress and prospects, *Indian J. Tuberc.* 1995; 42:75-85.
8. Hooper AA. Tuberculous peripheral lymphadenitis, *Br. J. Surg.* 1972; 59:353-9. <https://doi.org/10.1002/bjs.1800590506>. PMID: 5021137.
9. Parisi E, Glick M, Cervical lymphadenopathy in the dental patient: A review of clinical approach, *Quintessence Int.* 2005; 36(6):423-426.
10. Shakya G, Malla S, Shakya KN, Shrestha R. A study of FNAC of cervical lymph nodes, *J. Nepal Health Res. Council.* 2009; 7(14):1-5. <https://doi.org/10.3126/jnhrc.v7i1.2267>.
11. Larsson LO, Bentzon MW, Berg K, Mellander L, Skoogh BE, Stranegård IL. Palpable lymph nodes of the neck in Swedish schoolchildren, *Acta. Paediatrica.* 1994; 83:1092-94. <https://doi.org/10.1111/j.1651-2227.1994.tb12992.x>. PMID:7841711.
12. Andrew Coughlin, Shraddha S Mukerji. Pediatric Cervical Lymphadenopathy. Grand Rounds Presentation, The University of Texas Medical Branch, Department of Otolaryngology, Sep 2019. https://www.researchgate.net/publication/267551437_Pediatric_Cervical_Lymphadenopathy
13. Cummings: *Otolaryngology: Head and Neck Surgery*, 4th ed.
14. Narang RK, Pradhan S, Singh RP, Chaturvedi S. Place of fine needle aspiration cytology in the diagnosis of lymphadenopathy, *Ind. J. Tub.* 1990; 37:29-31.
15. Khan RA, Wahab S, Chana RS, Naseem S, Siddique S. Children with significant cervical lymphadenopathy: Clinico-pathological analysis and role of fine-needle aspiration in Indian setup, *J. Pediatr.* 2008; 84(5):449-54. <https://doi.org/10.2223/JPED.1840>. PMID: 18923792.
16. Khajuria R, Goswami KC, Singh K, Dubey VK. Pattern of lymphadenopathy on FNAC in Jammu, *JK Science.* 2006; 8(3):157-9.
17. Biswas G, Das A, Haldar D, Mukherjee A, Dutta S, Sinha R. Clinico-pathological correlates of cervical lymphadenopathy: A hospital based study, *Indian Journal of Otolaryngology and Head and Neck Surgery.* 2013 Jul 1; 65(1):42-7. <https://doi.org/10.1007/s12070-011-0443-z>. PMID:24427614, PMCID:PMC3718945.
18. Morland B. Lymphadenopathy, *Arch. Dis. Child.* 1995; 73:476-79. <https://doi.org/10.1136/adc.73.5.476>. PMID:8554372, PMCID:PMC1511364.
19. Pangalis GA, Vassilakopoulos TP, Boussiotis VA, Fessas P. Clinical approach to lymphadenopathy, *Semin. Oncol.* 1993; 20:570-82.
20. McHenry CR, Cooney MM, Slusarczyk SJ, Khiyami A, A Supraclavicular lymphadenopathy: The spectrum of pathology and evaluation by fine needle aspiration biopsy, *Am. Surgery.* 1999; 65:742-46.
21. Choi P, Qin X, Chen EY, Inglis AF Jr, Ou HC, Perkins JA, Sie KC, Patterson K, Berry S, Manning SC. Polymerase chain reaction for pathogen identification in persistent pediatric cervical lymphadenitis, *Arch. Otolaryngol Head Neck Surg.* 2009; 135:243-48. <https://doi.org/10.1001/archoto.2009.1>. PMID:19289701.
22. Vincet C, Cervical lymphadenopathy: What radiologists need to know, *Cancer Imaging.* 2004; (4):116-20. <https://doi.org/10.1102/1470-7330.2004.0020>. PMID: 18250018, PMCID: PMC1434593.

How to cite this article: Borse H., Bhamre. Clinico-Pathological Study of Cervical Lymphadenopathy in a Tertiary Care Centre. *MVP J. Med. Sci.* 2019; 6(1):22-27.