

# Study to Assess for Improvement in Renal Function following Anderson Hynes Pyeloplasty for Congenital Pelvi Ureteric Obstruction in Children

Shishir Kamble<sup>1</sup> and Mandar Vaidya<sup>2\*</sup>

<sup>1</sup>Former PG Resident, Department of Surgery, Dr. Vasant Rao Pawar Medical College Hospital and Research Centre, Nashik – 422003, Maharashtra, India

<sup>2</sup>Associate Professor, Department of Surgery, Dr. Vasant Rao Pawar Medical College Hospital and Research Centre, Nashik – 422003, Maharashtra, India; mandarvaidya63@yahoo.com

## Abstract

**Background:** Pelvi Ureteric Junction Obstruction (PUJO) is defined as an obstruction to the free flow of urine from the renal pelvis to the proximal ureter<sup>1</sup>. It is the most common cause of obstructive uropathy in the paediatric age group. **Aims:** To check for improvement in renal function following Anderson Hynes pyeloplasty for congenital PUJ obstruction and to find out at what age should a child be operated for best improvement in renal functions. **Material and Methods:** A total of 20 patients undergoing Anderson Hynes Pyeloplasty were included after they satisfied the inclusion and exclusion criteria. **Results:** In this study it was observed that post Anderson Hynes pyeloplasty, a total of 60% children showed improvement in renal functions, in 30% there was no change in renal function while 10% showed deterioration in renal functions, requiring re-operation. The improvement was statistically significant Mean eGFR in cases improved from 32.25 to 38.5 mL/min/1.73 m<sup>2</sup> after Anderson Hynes pyeloplasty. The improvement was statistically significant Mean renal functions in cases improved from 29.05% to 33.7% after Anderson Hynes pyeloplasty. No complications were reported in 85% of the cases after Anderson Hynes pyeloplasty. UTI developed in 2 cases (10%) while pyonephrosis was seen in 1 case (5%). **Conclusion:** Anderson Hynes Pyeloplasty is an effective treatment for congenital Pelvi Ureteric Junction obstruction in pediatric population. In this study it was observed that the earlier we operate the better is the improvement in function.

**Keywords:** Anderson Hyles Pyeloplasty, Congenital, Hydronephrosis, Pelvi-ureteric Obstruction

## 1. Introduction

Pelvi Ureteric Junction Obstruction (PUJO) is defined as an obstruction to the free flow of urine from the renal pelvis to the proximal ureter<sup>1</sup>. It is the most common cause of obstructive uropathy in the paediatric age group<sup>1,2</sup>.

Pelvi Ureteric Junction (PUJ) obstruction is the commonest cause of pediatric hydronephrosis occurring in 1 in 1000-2000 live births<sup>3</sup>.

Pelvi Ureteric Junction Obstruction (PUJO) is broadly classified as primary and secondary. Most of the cases of PUJO are congenital where etiology is due to insertion anomalies of ureter, ureteral muscular hypertrophy or peri pelvicalyceal fibrosis. Secondary PUJO results either from post-operative or inflammatory strictures, calculi or urothelial neoplasms. Obstruction leads to increase

back pressure on the kidneys leading to progressive deterioration of function<sup>4</sup>.

Most of the cases of hydronephrosis are now diagnosed by antenatal scans. Based on the presentation PUJO can be categorized into two groups—first where the condition is diagnosed antenatally and the second where presentation is due to symptoms at later age. Children diagnosed in antenatal period are followed postnatally. Depending upon the dimension of the renal pelvis and symptoms these children are either treated conservatively or surgically. Indications for surgery in PUJO are palpable kidneys, obstruction with differential function <40%, T<sub>½</sub> greater than 20 minutes on diuretic renogram and deterioration of renal function<sup>4</sup>.

Congenital obstructive nephropathy is the main cause of End Stage Renal Disease (ESRD) in children.

\*Author for correspondence

PUJO can present at any time between neonatal and old age. In older children PUJO has varied presentation and outcomes. Delay in presentation or detection of PUJO is associated with renal damage. The natural history of PUJ obstruction varies considerably, but the severity of renal pelvis dilatation usually correlates with the prognosis<sup>4</sup>.

A number of modifications have been made regarding surgical intervention. Anderson and Hynes modified Kuster's dismembered pyeloplasty in 1949<sup>5</sup>. It has been in use for more than 50 years and is considered to be a gold standard procedure with success rate greater than 90%<sup>6</sup>. Patients with moderately impaired preoperative function and those diagnosed postnatally because of symptoms are those with the greatest likelihood of having a functional improvement after surgery<sup>7</sup>.

Though recently minimally invasive techniques have been developed in an attempt to reduce post-operative morbidity and pain, open dismembered pyeloplasty continues to be preferred surgery for correction of ureteropelvic junction obstruction in developing countries like India.

The present study thus aimed to evaluate the improvement in renal function following Anderson Hynes pyeloplasty for congenital PUJO and to find out at what age child should be operated for best improvement in renal functions.

## 2. Aims and Objectives

To check for improvement in renal function following Anderson Hynes pyeloplasty for congenital PUJ obstruction and to find out at what age should a child be operated for best improvement in renal function.

## 3. Materials and Methods

Study Design: Observational study.

Study Setting: Department of Surgery of a Medical College and a tertiary health care centre.

Study Duration: August 2018 to December 2020.

Study Participants: Sample Size: 20.

### 3.1 Eligibility Criteria

#### 3.1.1 Inclusion Criteria

- Cases of congenital pelvi ureteric obstruction coming to Surgery OPD and admitted in surgery department.

- Cases which were regular for post treatment follow-up.
- Parents/LAR willing to be part of this study.

#### 3.1.2 Exclusion Criteria

- Patients with: Ectopic or solitary kidney
- PUJ obstruction secondary to stones, adhesions or external compression.
- Active bleeding diatheses.

## 3.3 Methodology

Patients were evaluated by taking detailed history, physical examination and investigations such as, urine analysis, blood CP, blood sugar, urea and serum creatinine, serum electrolytes, sonography and intravenous urography. Renal scan was done in patients where excretory urography did not show significant contrast excretion. MCUG was also done.

Standard open Anderson-Hynes dismembered pyeloplasty was done in all patients through anterior or subcostal incision. Accessory renal arteries crossing the ureter at PUJ obstruction were searched for. Repair was performed using vicryl 6-0 sutures. DJ stent was placed in antegrade fashion intraoperatively. Drain was placed adjacent to repair. Foley catheter was kept in the bladder. Post-operative complications were recorded. Foley catheter was removed after 24 hours and drain was removed when there was minimal drainage. DJ stent was removed after 6 weeks. Patients were followed at 6 weeks and at 3 months. The success was defined with asymptomatic, maintained renal function and unobstructed PUJ on urography

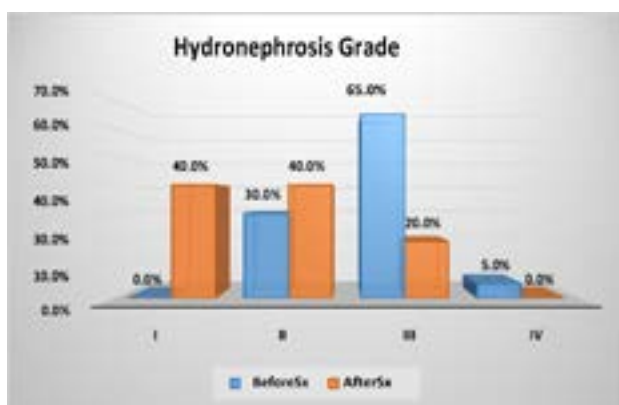
## 4. Results

In this study it was observed that post Anderson Hynes pyeloplasty, a total of 60% children showed improvement in renal functions, in 30% there was no change in renal function while 10% showed deterioration in renal functions, requiring re-operation. After the Anderson Hynes pyeloplasty, 40% each had grade I and II and 20% had grade III hydronephrosis while no case had grade IV hydronephrosis. The improvement was statistically significant Mean eGFR in cases improved from 32.25 to 38.5 mL/min/1.73m<sup>2</sup> after Anderson Hynes pyeloplasty. The improvement was statistically significant Mean renal functions in cases improved from 29.05% to 33.7%

after Anderson Hynes pyeloplasty. No complications were reported in 85% of the cases after Anderson Hynes pyeloplasty. UTI developed in 2 cases (10%) while pyonephrosis was seen in 1 case (5%).

**Table 1.** Distribution of the study cases as per hydronephrosis grade before and after surgery

Hydronephrosis Grade	Before Sx		AfterSx	
	N	%	N	%
I	0	0.0%	8	40.0%
II	6	30.0%	8	40.0%
III	13	65.0%	4	20.0%
IV	1	5.0%	0	0.0%
<b>Total</b>	<b>20</b>	<b>100.0%</b>	<b>20</b>	<b>100.0%</b>
<b>P-value &lt;0.01</b>				



**Table 2.** Distribution of the study cases as per mean eGFR before and after surgery

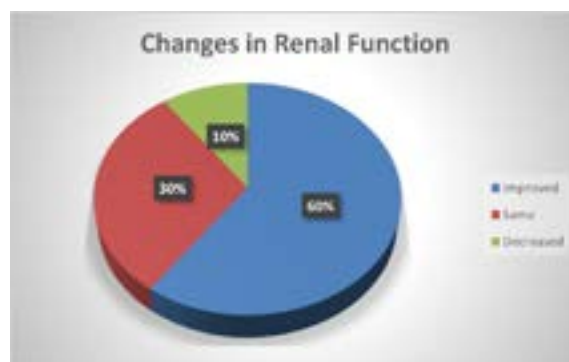
Variables	N	Mean	SD	p- value
eGFR (mL/min/1.73 m <sup>2</sup> )	Pre	20	32.25	<0.01
	Post	20	38.50	
30.00		30.00		
25.00		25.00		
20.00		20.00		
15.00		15.00		
10.00		10.00		
5.00		5.00		
0.00	Pre	Post	0.00	Pre
				Post

**Table 3.** Distribution of the study cases as per mean renal function (%) before and after surgery

Variables	GDM- FBS/ PLBS	N	Mean	SD	p- value
Renal Functions (%)	Pre	20	29.05	6.94	<0.01
	Post	20	33.70	7.10	

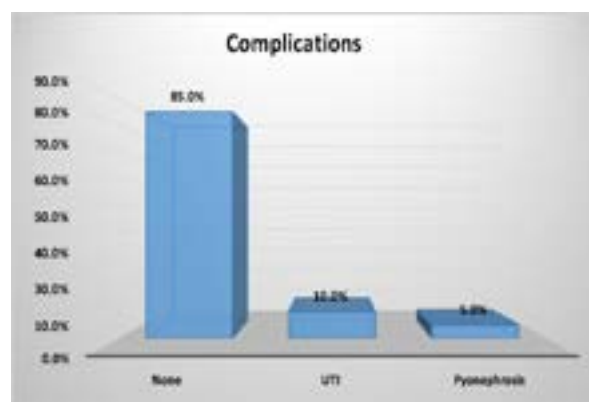
**Table 4.** Distribution of the study cases as per change in renal functions after surgery

Changes in Renal Function	N	%
Improved	12	60.0%
Same	6	30.0%
Decreased	2	10.0%
<b>Total</b>	<b>20</b>	<b>100.0%</b>



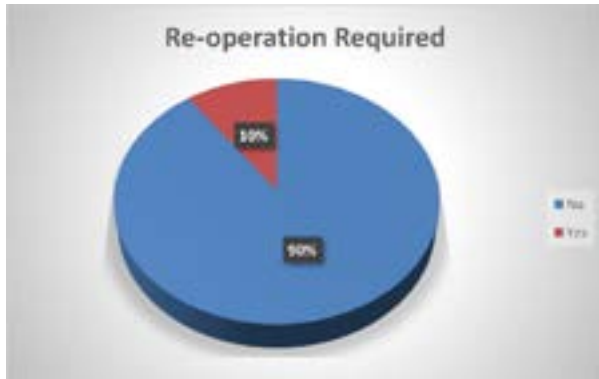**Table 5.** Distribution of the study cases as associated complications

Complications	N	%
None	17	85.0%
UTI	2	10.0%
Pyonephrosis	1	5.0%



**Table 6.** Distribution of the study cases as per requirement of re-operation

Re-operation Required	N	%
No	18	90.0%
Yes	2	10.0%
Total	20	100.0%



## 5. Discussion

The present study was done to evaluate the improvements in congenital PUJ obstruction post Anderson hynespyeloplasty and at what age should the child be operated for best improvement in renal functions.

Mean age of the children in the present study when they presented with congenital PUJ obstruction was 10.9 months and ranges from 3 months to 6 years with male child predominance.

Right side involvement was seen in 60% cases while left side was involved in 40% cases with congenital PUJ obstruction.

Antenatal diagnosis of congenital PUJ obstruction in the present study was also done in 80% of the cases.

Presentation in the newborn includes a palpable abdominal mass caused by an enlarged obstructed kidney. Other presentations include urinary tract infection, hematuria or failure to thrive. Renal failure is not a common presentation. Older children can present with intermittent flank pain which may worsen during brisk diuresis and have associated nausea and vomiting.

With the advent of modern imaging techniques, most of the cases were diagnosed antenatally and presented before development of symptoms.

A total of 30% and 65% children had grade II and III hydronephrosis while 1 had (5%) grade IV hydronephrosis prior to surgery. After the Anderson Hynes pyeloplasty, 40% each had grade I and II and 20%

had grade III hydronephrosis while no case had grade IV hydronephrosis ( $p < 0.01$ ) (Table 1).

Mean eGFR in cases improved from 32.25 to 38.5 mL/min/1.73m<sup>2</sup> after Anderson Hynes pyeloplasty ( $p < 0.01$ ).

Mean renal functions in cases improved from 29.05% to 33.7% after Anderson Hynes pyeloplasty ( $p < 0.01$ ) (Table 2).

Post Anderson Hynes pyeloplasty, a total of 60% children showed improvement in renal functions, in 30% there was no change in renal function while 10% (Table 3) showed deterioration in renal functions, requiring re-operation.

No complications were reported in 85% of the cases after Anderson Hynes pyeloplasty. UTI developed in 2 cases (10%) while pyonephrosis was seen in 1 case (5%) (Table 5).

Re-operation was required in 2 cases (10%). In both the cases there was worsening of function (Table 6).

## 6. Conclusion

Pelvi Ureteric Junction is common site of obstruction in the upper urinary tract. Post-operative recovery of renal function is achieved in majority of patients using Anderson-Hynes Pyeloplasty. It is a safe and effective treatment of UPJO in the pediatric population, not only providing relief of obstruction but also improvement of renal function. It remains the treatment of choice for this patient group. Statistically, there are improvements of function of kidney and the improvements of the remission of symptoms as a result of Anderson-Hynes Pyeloplasty.

## 7. Summary

Pelvi Ureteric Junction Obstruction is the most common site of obstruction in the upper urinary tract. It is defined as an obstruction to the flow of urine from renal pelvis to the proximal ureter. As a result of back pressure within renal pelvis, a progressive renal damage and deterioration sets in. In 1949 Anderson and Hynes published their experience with an operation that included complete transection of the upper ureter, subsequent spatulation of the ureter and trimming of the redundant pelvis.

Anderson hynespyeloplasty has been considered as the treatment of choice for congenital PUJO with hydronephrosis. This study would help us in getting better results for children with congenital PUJO with

hydronephrosis and help reduce morbidity associated with it by performing Anderson hynespyeloplasty at an appropriate age.

## 8. References

---

1. Sikandar AM, Sirajuddin S. Pelvi-ureteric Junction Obstruction in children. *Journal of Surgery Pakistan*. 2008; 13(4):163–6.
2. Lee H, Han SW. Uretero-pelvic Junction Obstruction: What we know and what we don't know. *Korean Journal of Urology*. 2009; 50(5):423–31. <https://doi.org/10.4111/kju.2009.50.5.423>
3. Rodriguez MM. Congenital anomalies of the kidney and the urinary tract (CAKUT). *Fetal Pediatr Pathol*. 2014 Oct 1; 33(5-6):293–320. PMID: 25313840 PMCID: PMC4266037. <https://doi.org/10.3109/15513815.2014.959678>
4. Mughal SA, Soomro SI. Pelvi-ureteric Junction Obstruction in children. *Journal of Surgery Pakistan (International)*. 2008 Oct; 13:4.
5. Rasool M, Sheikh HM, Ali S, Ahmed I. Pyeloplasty; Comparison of results of repair with and without stents. *The Professional*. 2005; 12:159–65.
6. Elafifi M, Eltatawy H, Haroon H, Gaber M, Farha MA. Evaluation of non-stented dismembered pyeloplasty in children suffering from Pelvic Ureteric Junction Obstruction. *Ann Pediatr Surg*. 2009; 5:52–7.
7. Castagnetti M, Novara G, Beniamin F, Vezzú B, Rigamonti W, Artibani W. Scintigraphic renal function after unilateral pyeloplasty in children: A systematic review. *BJU International*. 2008 Oct; 102(7):862–8. PMID: 18336599. <https://doi.org/10.1111/j.1464-410X.2008.07597.x>

---

**How to cite this article:** Kamble, S. and Vaidya, M. Study to Assess for Improvement in Renal Function following Anderson Hynes Pyeloplasty for Congenital Pelvi Ureteric Obstruction in Children. *MVP J. Med. Sci.* 2020; 8(2): 278-282.