

# A Study of Nd:YAG Laser Capsulotomy in the Management of Posterior Capsular Opacification

Mrunal Suresh Patil<sup>1</sup>, Dhiraj Namdeo Balwir<sup>2\*</sup> and Swapnil Vidhate<sup>3</sup>

<sup>1</sup>Dean & Professor, Department of Ophthalmology, Dr. Vasantrao Pawar Medical College Hospital & RC, Adgaon, Nashik - 422003, Maharashtra, India

<sup>2</sup>Associate Professor, Department of Ophthalmology, Dr. Vasantrao Pawar Medical College Hospital & RC, Adgaon, Nashik - 422003, Maharashtra, India; dheeraj\_balwir@yahoo.com

<sup>3</sup>Postgraduate Resident, Department of Ophthalmology, Dr. Vasantrao Pawar Medical College Hospital & RC, Adgaon, Nashik - 422003, Maharashtra, India

## Abstract

**Aims:** To study the visual outcome following Nd:YAG laser posterior capsulotomy and to study the complications associated with Nd:YAG laser posterior capsulotomy. **Material and Methods:** The study included a total of 100 eyes of 100 patients who fulfilled the inclusion and exclusion criteria. Once diagnosed to have posterior capsular opacification they were subjected to a detailed clinical examination. All patients underwent Nd:YAG laser capsulotomy. Patients were followed up at 1 hour, 4 hour, 1 day, 1 week, 1 month, 3 month. At every follow up detailed examination was done. BCVA and any complications were noted. **Results:** Post-laser, 87% patients had BCVA 6/12 or more at 3 month follow up. 10% patients had BCVA 6/24 to 6/18. Only 3% patients had visual acuity improved to less than 6/24. Out of 3 patients, 1 patient had visual acuity improved to 6/60 & in remaining 2 visual acuity improved to 6/36. The complications were seen in 31 (31%) patients. Most common complication observed was transient rise in IOP. 17 eyes (17%) had transiently raised IOP. Second most common noted was pitting of IOL. Pitting was present in 7 (7%) patients, 3 (3%) patients had ruptured anterior face of vitreous, 2 (2%) patients had iritis, 1 (1%) had hyphema and 1 (1%) developed CME. IOP rise was related to grade of PCO and energy used. **Conclusion:** Improvement in visual acuity after Nd:YAG laser posterior capsulotomy is excellent. Complications associated with Nd:YAG laser capsulotomy are minimal. Nd: YAG laser capsulotomy is a safe method of restoring vision in patients with posterior capsule opacification.

**Keywords:** Complications, Nd:YAG laser, Posterior Capsulotomy

## 1. Introduction

Cataract is the most common cause of curable blindness in the world. Cataract remains the leading cause of blindness in India (62.60%)<sup>1</sup>. In India cataract has been reported to be responsible for 50-80 % of the bilaterally blind in the country<sup>2</sup>.

Extracapsular Cataract Extraction (ECCE) with posterior chamber Intraocular Lens (IOL) implantation is the preferred surgical technique over Intracapsular Cataract Extraction (ICCE) for the treatment of cataract in developed countries and most surgeons in developing countries are now being trained in this method<sup>3</sup>. In ECCE, the lens contents are removed leaving the posterior lens capsule intact forming an anatomical barrier between

the anterior and posterior segments of the eye. However, leaving the capsule intact may result in late complications, mainly that of Posterior Capsule Opacification (PCO)<sup>4</sup>.

PCO is the commonest complication of cataract surgery occurring in up to 50% of patients after 2-3 years of surgery<sup>5</sup>. PCO results from growth and trans-differentiation of LECs left on the anterior capsule at the time of cataract surgery<sup>6,7</sup>. These cells proliferate to form monolayers on the capsular surfaces and such monolayers continue to line the anterior capsule leaflet many years after surgery. Equatorial differentiation of cells to Fibre-like structures leads to Soemmerring's ring formation and peripheral thickening of the capsular bag. Closer to the rrhexis, cell swelling can result in globular Elschnig's pearls, which may occlude the visual axis. Posterior

\*Author for correspondence

Capsular Opacification (PCO), by causing forward and backward light scattering, reduces Visual Acuity (VA) and Contrast Sensitivity (CS)<sup>8-14</sup>.

Visual symptoms do not always correlate to the observed amount of PCO. Some patients with significant PCO on slitlamp examination are relatively asymptomatic while others have significant symptoms with mild apparent haze, which is reversed by capsulotomy<sup>8</sup>.

Laser capsulotomy using Nd:YAG laser is the choice of treatment for PCO. The use of the Nd:YAG laser was permanently established in ophthalmology independently by Fankhauser in Switzerland and Aron-Rosa in France. This causes photo- disruption of the capsule and thus clears the visual axis. The procedure involves clearing of the visual axis by creating a central opening in the opacified posterior capsule by focusing a Nd:YAG laser pulse, with energy of few millijoules and duration of a few nanoseconds, just behind the posterior capsule<sup>6,15</sup>. Indications for Nd: YAG laser capsulotomy includes a thickened capsule leading to functional impairment of vision and the need to evaluate and treat posterior segment pathology. Nd:YAG laser posterior capsulotomy may be associated with complications such as transient rise in IOP, enhanced risk of retinal detachment (particularly marked in axial myopia), cystoid macular oedema, lens damage/ pitting, endophthalmitis, vitreous prolapse into the anterior chamber and anterior hyaloid disruption.

In this study an attempt has been made to evaluate the visual outcome of Nd-YAG laser capsulotomy for posterior capsular opacification and also to evaluate the complications following laser capsulotomy.

## 2. Material and Methods

The study included a total of 100 eyes of 100 patients who fulfilled the inclusion and exclusion criteria. Once diagnosed to have posterior capsular opacification they were subjected to a detailed clinical examination.

### 2.1 Inclusion criteria

- Patients undergoing Nd:YAG laser posterior capsulotomy.
- Age group 20-80 years.
- Patients willing to give informed consent for treatment and study.
- Patients ready to come for follow up.

### 2.2 Exclusion criteria

- Active ocular pathology such as uveitis, infection.
- Pre-existing ocular condition which can lead to decrease in vision after laser capsulotomy such as glaucoma, any retinal pathology.
- Any media opacity preventing focussing of laser.
- Patients not willing to give informed consent or not attending follow up.

An informed consent was obtained from every patient.

### 2.3 Pre-laser examinations

Complete ocular examination was done which included

- Complete ophthalmic history and medical history
- Visual Acuity; aided and best corrected with Snellens' chart
- Intra-ocular pressure measurement by applanation tonometry.
- Complete and detailed Slit lamp examination.
- Fundus examination with direct and indirect ophthalmoscope.
- Grading of PCO was done.

### 2.4 Pre-Laser Medication

- Timolol 0.5% 1 drop was instilled 1 hour before in the eye which is undergoing laser capsulotomy.
- Dilatation of the pupil was done with Tropicamide 0.8% and Phenylephrine 5% eyedrops

### 2.5 Anaesthesia

- All capsulotomies were performed under topical anaesthesia with 0.5% proparacaine.

### 2.6 Procedure

- The patient is introduced to the equipment in a reassuring way.
- The head was gently placed in front of the laser on chin rest & head strap was applied.
- Contact lens was applied.
- Areas were noted where the lens capsule was thinnest and where the capsule appeared to be under tension.
- A thin tense lens capsule is desirable because flaps of the capsule will separate when the capsule is photodisrupted.
- Settings of 0.8 millijoules of power were delivered in a single pulse mode.

- The power was increased until this occurs.
- In pseudophakic eye with the secondary membrane in close proximity to the posterior surface of the optic, the laser was defocused.
- Cruciate openings were made beginning at 12 o’ clock periphery and progressing towards 6 o’ clock position.

### 2.7 Post-laser Medication

Timolol 0.5%, 1 drop twice a day for 7 days

## 3. Results

A total of 100 eyes of 100 patients in 24-74 years age groups with 38 females and 62 males, in accordance to the inclusion and exclusion criteria, were thoroughly evaluated before capsulotomy, grading of PCO was done and Laser capsulotomy was performed.

In maximum patients who were having PCO, the cataract surgery was performed >24 month back. 8 patients developed PCO within 12 months of cataract surgery. In 38 patients duration between cataract surgery and PCO was 12-24 months. In 4 patients who were below 45 years of age PCO developed within 6 months of cataract surgery. Mean duration between cataract surgery and PCO was  $30.49 \pm 17.83$  months.

The maximum number of patients were having grade 2 PCO, followed by grade 3 and grade 1.

Mean energy used was  $62.47 \pm 33.65$  mJ. Mean energy used per pulse was  $1.9 \pm 0.6$  mJ. Mean number of shots

were  $30.81 \pm 7.9$ . Higher energy was required for higher grades of PCO.

The Nd: YAG laser was effective in clearing pupillary opening in all 100eyes (100%). None of the patients required retreatment. Post-laser, 67% patients had BCVA 6/9 or more at 3 month follow up. 30% patients had BCVA 6/24 to 6/12. Only 3% patients had visual acuity improved to less than 6/24. Out of 3 patients, 1 patient had visual acuity improved to 6/60 & in remaining 2 visual acuity improved to 6/36. None of the patients had decreased visual acuity than pre-laser level (Figure 1, 2, 3).

Visual outcome was not affected by any complications.

The complications were seen in 31 (31%) patients. Most common complication observed was transient rise in IOP. 17 eyes (17%) had transiently raised IOP. Second most common complications noted was pitting of IOL. Pitting was present in 7 (7%) patients, 3 (3%) patients had ruptured anterior face of vitreous, 2 (2%) patients had iritis, 1 (1%) had hyphema and 1 (1%) developed CME (Figure 4).

Transient IOP rise occurred at 1 and 4 hour post-laser in maximum patients. IOP raised significantly when pre-laser IOP was >20 mm of Hg. IOP rise was statistically significant when grade of PCO was higher and higher energy was used. Mean IOP at 1 week was decreased as patients were on anti-glaucoma medication. At 3 month follow up none of the patient had persistently raised IOP.

IOL pitting was the second most common complication observed in our study. None of the patients had decreased vision due to IOL damage. Iritis, hyphema, CME, ruptured anterior face of vitreous were also

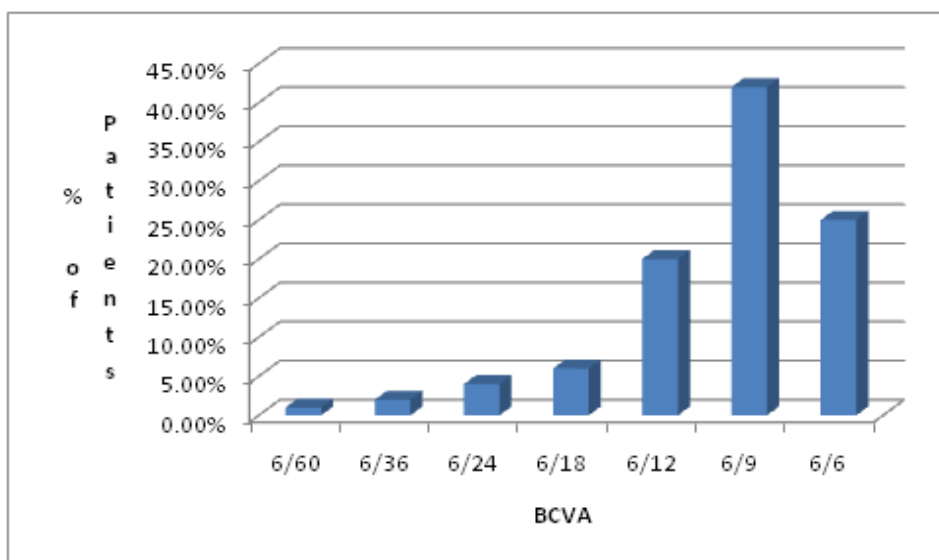
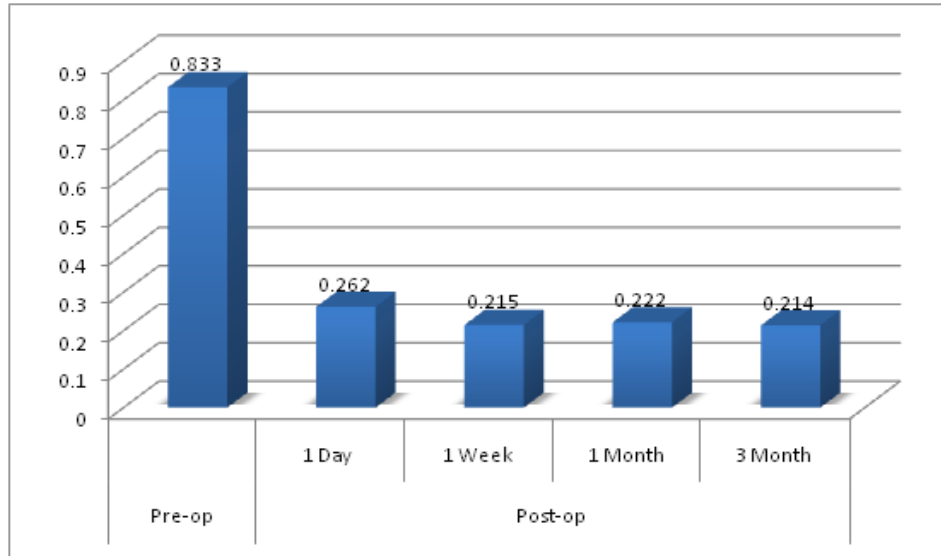
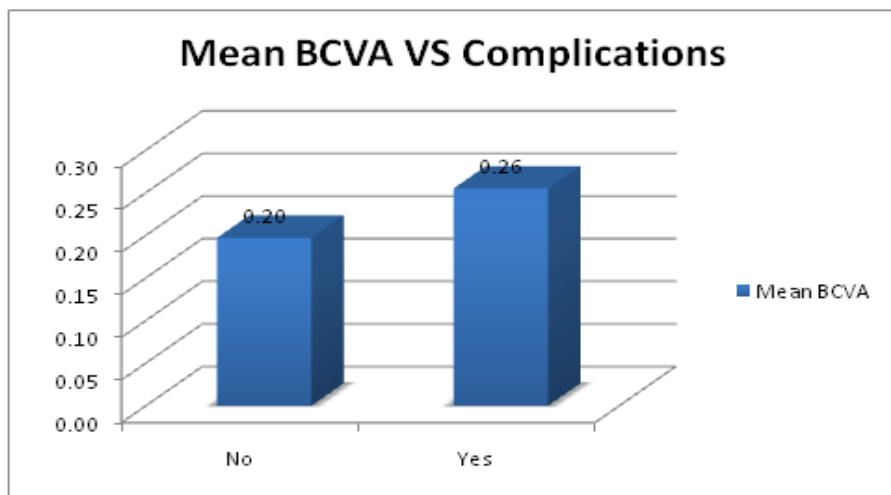


Figure 1. Post-laser BCVA.



**Figure 2.** Pre and Post laser BCVA in Logmar.



**Figure 3.** Mean BCVA VS Complication.

observed in our study. All patients were successfully treated. None of the patients had decreased vision due to these complications. Complications other than transient IOP rise were not related to grades of PCO and amount of energy used.

## 4. Discussion

### 4.1 Visual Outcome

In ophthalmic practice, importance is given to visual acuity when assessing a patient's visual outcome in relation to planned or executed procedures.

Improvement in visual acuity is the primary endpoint for successful neodymium:YAG (Nd:YAG) laser posterior capsulotomy for posterior capsule opacification.

In eyes with Posterior Capsular Opacification, the Nd:YAG laser was effective in clearing pupillary opening in all 100 eyes (100%).

In our study, pre-laser best corrected visual acuity ranged from 1/60 to 6/12. In 56 patients BCVA ranged from 1/60 to 6/36 & in 44 patients it ranged from 6/24 to 6/12.

Improvement in visual acuity was excellent in our study.

Post-laser 67% patients had visual acuity 6/9 or more at 3 month follow up. 30% patients had visual acuity 6/24

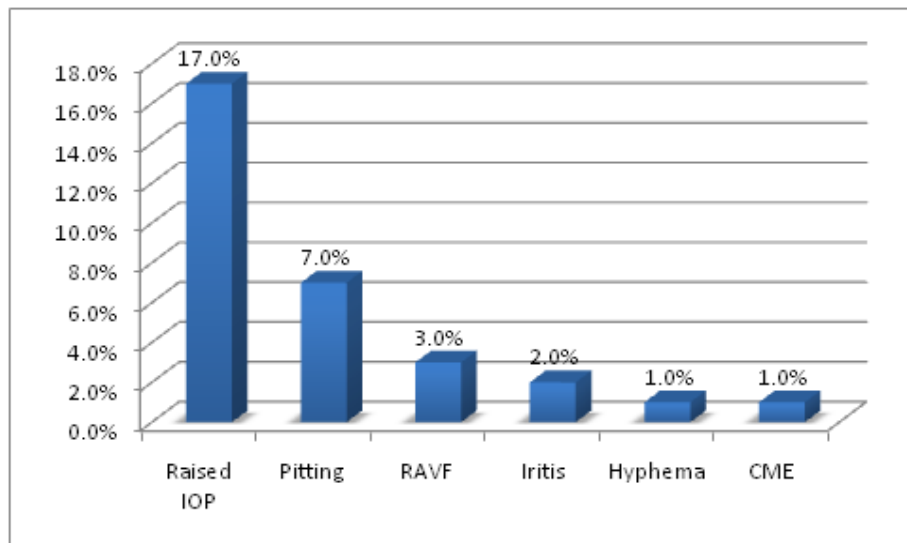


Figure 4. Complications.

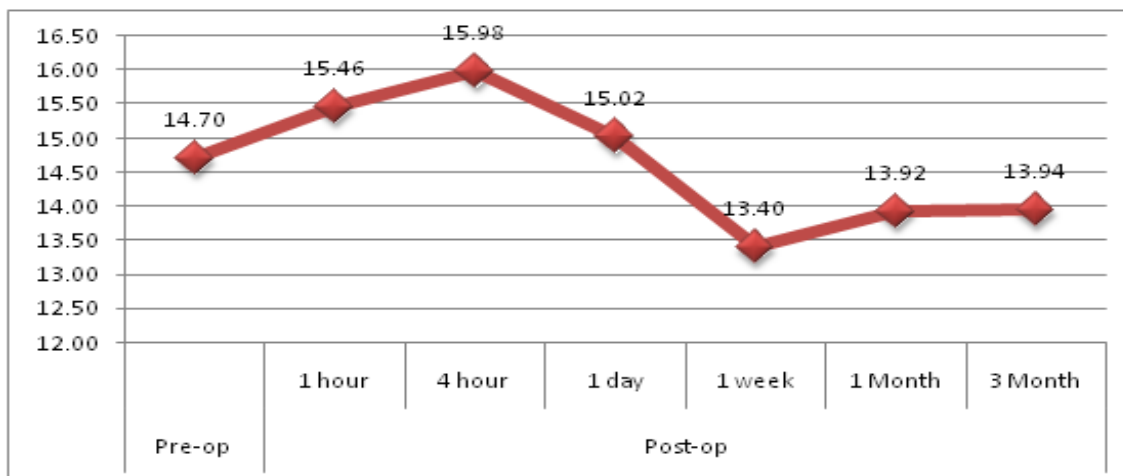


Figure 5. Mean IOP (in mm of Hg) Changes.

to 6/12. Only 3 (3%) patients had visual acuity improved to less than 6/24. Out of 3 patients, 1 patient had visual acuity improved to 6/60 & 2 had improved to 6/36. Less improvement in visual acuity was due to underlying pathology which could not be diagnosed due to thick PCO.

In our study we did not observe decrease in visual acuity than pre-laser visual acuity in any case. Vision was improved in all patients atleast by one Snellen’s line. This is probably due to exclusion of cases from study with pre-existing ocular diseases which could prevent improvement in visual acuity.

In our study visual outcome was not affected by complications.

Steinert R F et al. studied 526 subjects who were treated with the laser, 87.8% had improved vision, with 82.9% achieving a visual acuity of 20/40 or better<sup>16</sup>.

In an analysis of data by Stark W J of Food and Drug Administration (FDA) on over 17,000 cases, a successful opening in the pupillary membrane was achieved in 98% of the cases, and vision improved in 84% of the cases<sup>17</sup>.

In our study we observed 7 eyes (7%) with IOL pitting. It was the second most common complication after IOP rise.

Wang, Jun observed only one postoperative complication which was laser spot in intraocular lens in 5 eyes (6.8%)<sup>18</sup>.

In another study by Pop I, discrete laser marks on the implant were seen in 8.77% patients<sup>19</sup>.

Relatively low incidence of IOL pitting was observed in our study as capsulotomy was performed by experienced surgeon with contact lens keeping energy output low. Mean energy used in our study was  $62.46 \pm 33.64$  mJ and in patients with pitting mean energy used was  $53.16 \pm 13.30$  mJ. All the patients which had pitting were relatively non-cooperative than others. In our study, IOL pitting had no significant effect on visual acuity. In all cases of IOL pitting the damage was in peripheral parts of IOL.

## 4.2 Increased Intraocular Pressure

IOP rise was the most common complication of ND YAG Capsulotomy in our study. The IOP rise after Nd: YAG laser posterior capsulotomy may be absent or transient or permanent.

In our study we had 17 eyes (17%) which had raised IOP  $>4$  mm of Hg but none of the patients had IOP rise over 30 mm of Hg (Figure 5).

The pressure spikes are recorded at 3 to 4 hours after laser treatment and it returns to within 5 mm Hg of pre-laser values by 24 hours<sup>17</sup>.

In our study 7 patients had IOP greater than 4 mm of Hg after 1 hour, 14 patients had IOP greater than 4 mm of Hg after 4 hours and 7 patients had IOP greater than 4 mm of Hg after 24 hours.

We observed statistically significant increased IOP in patients which had pre-laser IOP  $>20$  mm of Hg which is in agreement with FDA report by Stark et al<sup>17</sup>.

In our study, we observed that there was statistically significant increase in IOP at 1 and 4 hour post-laser when higher energy was used.

We also observed that statistically significant increase in IOP at 1 and 4 hour post-laser occurred more in patients which had higher grades of PCO as in higher grade there is more liberation of capsular debris which can lead to increased blockage of trabecular meshwork.

In our study there was no case of retinal detachment. This could be because of the absence of risk factors in our cases.

In our study, 1 eye (1%) had CME, duration of cataract surgery and capsulotomy in the patient who had CME was 5 months. Patient was diagnosed with CME at 1 month follow up when patient had complained about decrease in vision.

In our study only 1 patient i.e.1% had iris bleed/hyphema. Bleeding was stopped by applying pressure on

cornea with contact lens. Hyphema was cleared on next day. Visual acuity was not affected by hyphema. Visual acuity after 24 hours was 6/9 and in all subsequent follow ups also VA was 6/9.

In our study we observed iritis in 2 patients (2%) after 24 hours of capsulotomy. Patients were prescribed Prednisolone acetate 1% and Homatropine eye drops for 1 week. After 1 week follow up none of the patient had iritis. We did not note any persistent iritis in subsequent follow ups at 1 month and 3 month.

In our study all of the patients were pseudophakic. We observed only 2 cases of rupture of anterior vitreous face.

Other complications such as pupillary block glaucoma and aqueous misdirection syndrome<sup>17</sup>, retinal hemorrhage<sup>17</sup>, spreading of endocapsular low-grade endophthalmitis<sup>17</sup> were not reported in our study.

## 5. Conclusion

Improvement in visual acuity after Nd:YAG laser posterior capsulotomy is excellent. Complications associated with Nd:YAG laser capsulotomy are minimal. Nd: YAG laser capsulotomy is a safe method of restoring vision in patients with posterior capsule opacification.

## 6. References

1. Vijaya L, George R, Arvind H, Baskaran M, Raju P, Ramesh SV et al. Prevalence and causes of blindness in a rural south Indian population. *British Journal of Ophthalmology*. 2006; 90:407–10.
2. Murthy G, Gupta SK, John N, Vashist P. Current status of cataract blindness and Vision 2020: The right to sight initiative in India. *Indian Journal of Ophthalmology*. 2008; 56:489–94.
3. Riaz Y, Mehta JS, Wormald R, Evans JR, Foster A, Ravilla T, Snellingen T. Surgical interventions for age-related cataract. *Cochrane Database Syst Rev*. 2006 Oct 18; (4):CD001323. Review. PubMed PMID: 17054134.
4. Schaumberg DA, Dana MR, Christen WG, Glynn RJ. A systematic overview of the incidence of posterior capsule opacification. *Ophthalmology*. 1998 Jul; 105(7):1213–21. PubMed PMID: 9663224.
5. Spalton DJ. Posterior capsular opacification after cataract surgery. *Eye (Lond)*. 1999 Jun; 13(Pt 3b):489–92. Review. PubMed PMID: 10627830.
6. Apple DJ, Solomon KD, Tetz MR, Assia EI, Holland EY, Legler UF, Tsai JC, Castaneda VE, Hoggatt JP, Kostick AM. Posterior capsule opacification. *Surv Ophthalmol*.

- 1992 Sep-Oct; 37(2):73–116. Review. PubMed PMID: 1455302.
7. Marcantonio JM, Vrensen GF. Cell biology of posterior capsular opacification. *Eye (Lond)*. 1999 Jun; 13(Pt 3b):484–8. Review. PubMed PMID: 10627829.
  8. Cheng CY, Yen MY, Chen SJ, Kao SC, Hsu WM, Liu JH et al. Visual acuity and contrast sensitivity in different types of posterior capsule opacification. *J Cataract Refract Surg*. 2001; 27:1055–60.
  9. Meacock WR, Spalton DJ, Boyce J, Marshall J. The effect of posterior capsule opacification on visual function. *Invest Ophthalmol Vis Sci*. 2003; 44:4665–9.
  10. Hayashi K, Hayashi H, Nakao F, Hayashi F. Correlation between posterior capsule opacification and visual function before and after neodymium: YAG laser posteriorcapsulotomy. *Am J Ophthalmol*. 2003; 136:720–6.
  11. Magno BV, Datiles MB, Lasa MS, Fajardo MR, Caruso RC, Kaiser-Kupfer ML et al. Evaluation of visual function following neodymium: YAG laser posterior capsulotomy. *Ophthalmology*. 1997; 104:1287–93.
  12. Tan JC, Spalton DJ, Arden GB. The effect of neodymium: YAG capsulotomy on contrast sensitivity and the evaluation of methods for its assessment. *Ophthalmology*. 1999; 106:703–9.
  13. Aslam TM, Aspinall P, Dhillon B. Posterior capsule morphology determinants of visual function. *Graefes Arch Clin Exp Ophthalmol*. 2003; 241:208–12.
  14. Aslam TM, Patton N. Methods of assessment of patients for Nd: YAG laser capsulotomy that correlate with final visual improvement. *BMC Ophthalmol*. 2004; 4:13.
  15. Apple DJ, Peng Q, Visessook N, et al. Eradication of posterior capsule opacification: documentation of a marked decrease in Nd: YAG laser posterior capsulotomy rates noted in an analysis of 5416 pseudophakic human eyes obtained postmortem. *Ophthalmology*. 2001; 108:505–18.
  16. Steinert RF, Keates RH, Steinert RF, Puliafito CA, Maxwell SK. Long-term follow-up of Nd: YAG laser posterior capsulotomy. *J Am Intraocul Implant Soc*. 1984 Spring; 10(2):164–8. PubMed PMID: 6547424.
  17. Stark WJ, Worthen D, Holladay JT, Murray G. Neodymium: YAG lasers. An FDA report. *Ophthalmology*. 1985 Feb; 92(2):209–12. PubMed PMID: 3982799.
  18. Wang J, Sun B, Yang X, Chen J. [Evaluation of visual function following neodymium: YAG laser posterior capsulotomy]. *Zhonghua Yan KeZaZhi*. 2002 Sep; 38(9):556–61. Chinese. PubMed PMID: 12410978.
  19. Pop I, Petroi C, Coroi M, Ban C, Roiu G, Stepan E, Nistoran S, Hanciu D. [Secondary cataract treatment with laser YAG-ND]. *Oftalmologia*. 2002; 54(3):68–71. Romanian. PubMed PMID: 12723203.