

# Bronchial Carcinoid: Case Report and Review of Literature

Gauri S. Kulkarni<sup>1\*</sup>, Sonal C. Gawande<sup>2</sup>, Deependra V. Chaudhari<sup>1</sup> and Anup P. Bhojar<sup>3</sup>

<sup>1</sup>Associate Professor, Department of Pulmonary Medicine, Dr. Vasant Rao Pawar Medical College, Nashik - 422203, Maharashtra, India; gaurisuhas@yahoo.com

<sup>2</sup>Assistant Professor, Department of Pulmonary Medicine, Dr. Vasant Rao Pawar Medical College, Nashik - 422203, Maharashtra, India

<sup>3</sup>PG Resident, Department of Pulmonary Medicine, Dr. Vasant Rao Pawar Medical College, Nashik - 422203, Maharashtra, India

## Abstract

Bronchopulmonary carcinoid tumors which are slow growing neuroendocrine tumors arising from Enterochromaffin (EC) cells, accounts for 10% of all carcinoid tumors. Mentioned here is a case report of 46 year old male with incidental finding on CXR of left hemithorax inhomogenous opacity and features suggestive of volume loss. CECT showed a well defined 2.5 x 1.5 cm circular intraluminal growth occluding the left main bronchus. Bronchoscopy revealed a red, shiny, smooth walled growth 1 cm beyond the carina in the left main bronchus, attached to the roof of the bronchial wall, causing ball valve mechanism. Histopathology and Cytology of needle aspiration from tumor confirmed the diagnosis of bronchial carcinoid. To avoid misdiagnosis or delay in diagnosis of intrabronchial carcinoid a high index of suspicion should be maintained and radiological, bronchoscopic and pathological investigations for accurate and early diagnosis must be undertaken.

**Keywords:** Bronchial Carcinoid Tumor, Diagnosis, Treatment of Bronchial Carcinoid

## 1. Introduction

Enterochromaffin (EC) cells, or “Kulchitsky cells”, are a type of enteroendocrine and neuroendocrine cells occurring in the epithelia lining the lumen of the digestive tract and the respiratory tract that release serotonin. Carcinoid tumors are neuroendocrine tumors arising from Enterochromaffin (EC) cells<sup>1</sup>.

The Gastrointestinal (GI) tract is the most common site for carcinoid tumors. Of all carcinoids, bronchopulmonary carcinoids represent only 10% cases, of which 80-90% arise within the segmental or subsegmental bronchus and about 10-20% are found in the periphery. Only about 1% to 6% of all lung tumors are carcinoid tumors. Typical carcinoids are more common and atypical carcinoids account for only 10% of all pulmonary carcinoids. Symptom free incidental detection of pulmonary carcinoids are a common occurrence as 25-39% of these

patients are asymptomatic and carcinoid syndrome occurs in about 2% of cases only<sup>2</sup>. Early diagnosis is extremely important as patients benefit from surgical resection and prognosis is very good.

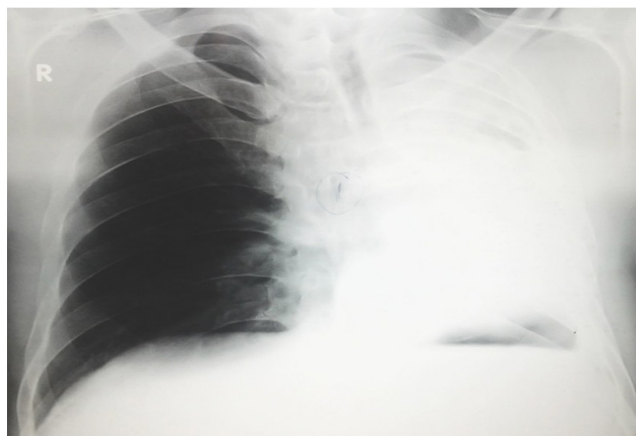We present a case of bronchial carcinoid detected following evaluation of incidental findings on Chest Radiograph (CXR). Patient was asked to get Contrast Enhanced Computed Tomography (CECT) Thorax, and Bronchoscopic Needle Aspiration of the tumor was done to confirm the diagnosis.

## 2. Case Report

46 year old male patient was referred to pulmonary medicine OPD for CXR changes (Figure 1.) detected incidentally during evaluation for fracture tibia post road traffic accident. He had no associated chest trauma. On further enquiry he stated that he perceives MMRC grade

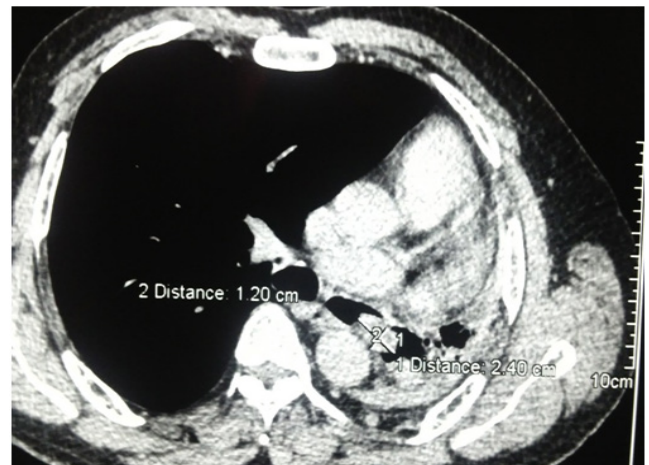
\*Author for correspondence

1 breathlessness on exertion since 4 months. He had no other chest or constitutional symptoms. There was no significant past or family history. Patient has history of smoking 20 cigarettes per day for 15 years and significant history of alcohol consumption. On admission patient was afebrile and had pulse rate of 88 per minute, respiratory rate of 12 per minute and blood pressure of 110/70 mm Hg and normal general examination, no pallor, no clubbing or lymphadenopathy. His chest examination revealed signs of volume loss, decreased movements, dull percussion note, decreased breath sounds over left hemithorax with bronchial breathing over left interscapular and infrascapular areas. Laboratory investigations (complete hemogram, renal and liver function tests) were unremarkable. CXR (Figure 1.) showed left hemithorax inhomogenous opacity with left shift of mediastinum and features of volume loss. Right hemithorax and bony-soft tissue shadows appeared normal. He was further evaluated with CECT chest (Figure 2(b)) which showed collapse of left lung with minimum aeration noted proximally. A well defined 2.5 x 1.5 cm (Figure 2(a)) circular growth was observed extending from the left main bronchial wall intraluminally occluding the airway. Right lung showed well developed compensatory hyperinflation, causing herniation of right lung to left. There was no evidence of any lymphadenopathy. Bronchoscopy revealed deviated and dilated right lung bronchial openings with normal wall structure. Left main bronchus was occluded due to the mass 1 cm beyond the carina with red, shiny, smooth walled growth attached to the roof of the bronchus (Figure 3). On deep breathing and during coughing the growth moved causing a ball valve mechanism and

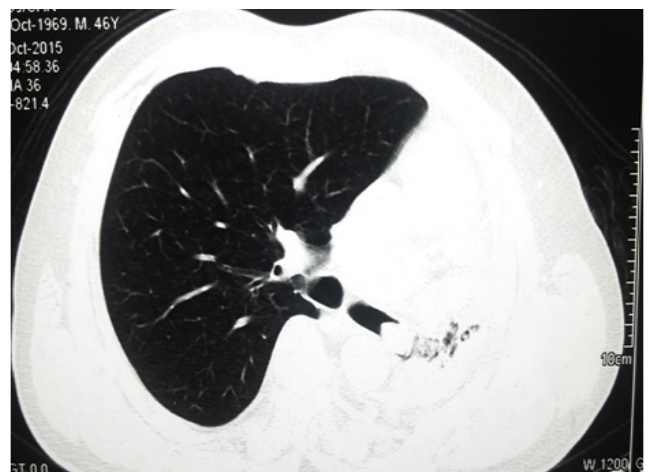


**Figure 1.** Chest radiograph showing left lung collapse (left hemithorax homogenous opacity with volume loss).

allowing only minimum airflow to the left lung. Reclining position of the patient showed movement of secretions from the left main bronchus in to the right bronchial branches. There was no bleeding on touch. Needle aspiration was performed following which there was bleeding at the site which was quickly controlled by cold saline wash. Cytology (Figure 4.) of the specimen showed few foci of aggregates of small round cells with monomorphic hyperchromatic nuclei surrounded by scanty cytoplasm. Patient has been referred for excision of the tumor.

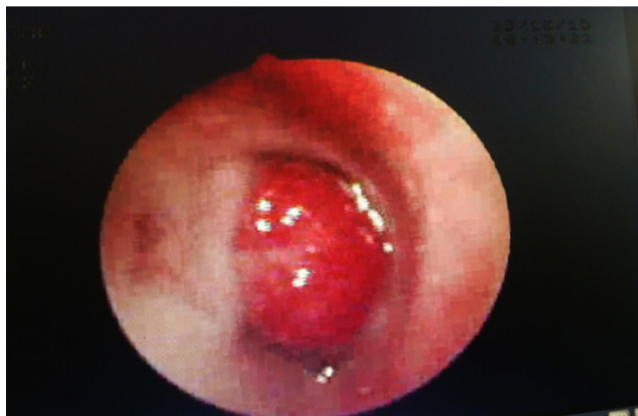

(a)

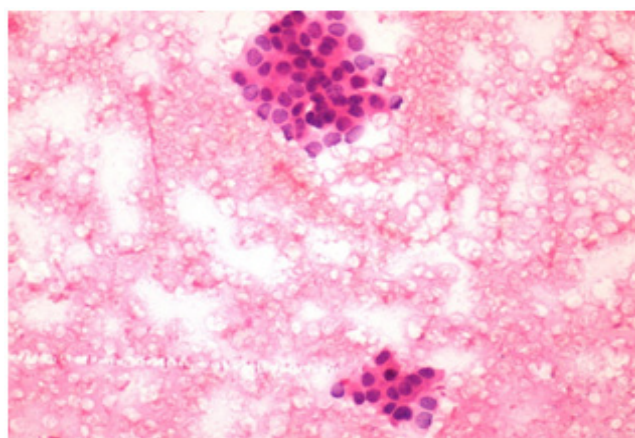


(b)

**Figure 2.** (a) Mediastinal window during phase of contrast shows a well defined 2.5 x 1.5 cm round bordered intraluminal growth in the the left main bronchus occluding the airway. (b) Lung wndow shows near complete collapse of left lung with minimum aeration post obstruction. Right lung showed well developed compensatory hyperinflation changes only, causing herniation to left.



**Figure 3.** Bronchoscopic visualization of the red fleshy smooth walled endobronchial tumor 1cm beyond the carina occluding the left main bronchus.



**Figure 4.** High power microscopy showed few foci of aggregates of small round cells with monomorphic hyperchromatic nuclei surrounded by scanty cytoplasm.

### 3. Discussion

Carcinoid was first described in the late 19<sup>th</sup> century by Lubarsh, who found multiple tumors in the small bowel of 2 patients at autopsy<sup>3</sup> and Siegfried Oberndorfer, a German pathologist at the University of Munich, coined the term *karzinoide*, or “carcinoma-like”, to describe the unique feature of behaving like a benign tumor despite having a malignant appearance microscopically<sup>4</sup>. Its endocrine-related properties were later described by Gosset and Masson in 1914<sup>5</sup> Hamperl in 1937 reported the first description of pulmonary carcinoid<sup>6</sup>.

The overall incidence of carcinoid tumors is estimated to be 1 to 2 cases per 100,000 individuals in the United States and is similar in England, Scotland, Spain,

Italy, and Japan<sup>7-12</sup>. This incidence varies with gender, age, and race Carcinoids generally have a higher incidence in African-Americans<sup>7-13</sup>. A recent analysis of 13,715 carcinoid tumors from the Surveillance, Epidemiology, and End Result (SEER) Program of the National Cancer Institute found that 67.5% of all carcinoid tumors originate in the GI tract and 25.3% originate in the lungs or bronchi<sup>13</sup>. Depending upon the degree of differentiation and lymphnode metastasis Typical Carcinoids have the best prognosis, with a 10-year survival rate of more than 80%. The 5-year survival rate in Atypical Carcinoid without lymph node metastases is 80%, and for Atypical Carcinoid with lymph node metastases is 60%. High vigilance is to be maintained in Typical Carcinoid since recurrence and distant metastasis can develop even after 10 years<sup>14</sup>. Local resection of metastatic lesion in liver also has a 5 year mean survival rate of 78 %<sup>15</sup>. The average age of occurrence of Typical Carcinoid tumors is 40-50 years, but Typical Carcinoid tumors have been reported in virtually every age group. Atypical Carcinoid tumors appear in slightly older people than Typical Carcinoid tumors. Carcinoid tumors occur in equal numbers in males and females<sup>3</sup>.

#### 3.1 Risk Factors

Smoking is a major risk factor for many malignancy and bronchial carcinoids are no different. Although the association between bronchial carcinoids and smoking is unclear, between one-third and two-thirds of all patients have been smokers<sup>16</sup> with higher prevalence of smoking being reported in patients with Atypical Carcinoids<sup>17</sup>. No other known carcinogens or exposure to environmental agents has been implicated in carcinogenesis<sup>16</sup>. Patients with the autosomal dominant syndrome of multiple endocrine neoplasia type 1 (MEN 1) have a high frequency of endocrine malignancies, and foregut carcinoids (i.e., thymus, lung, stomach, or duodenum) arise in approximately 2 percent of cases<sup>16</sup>. There are reports of familial pulmonary carcinoids not associated with the MEN syndrome<sup>18</sup>.

#### 3.2 Clinical Characteristics

The patients of carcinoid most commonly presents with haemoptysis, cough, recurrent pulmonary infections, fever, chest discomfort, unilateral wheezing and shortness of breath<sup>19</sup>. 25 to 40% of patients are asymptomatic. Pulmonary carcinoids may release corticotropin,

resulting in Cushing's syndrome<sup>20,21</sup> or GH-releasing hormone (GH-RH) resulting in acromegaly<sup>22</sup>. Carcinoid syndrome, which occurs when the vasoactive substances escape into the systemic circulation escaping the hepatic degradation, is seen in less than 5% of patients with pulmonary carcinoid<sup>23</sup>. Metastases occurs usually to mediastinal lymph nodes. The second common site of metastasis is the liver. Rarely the carcinoid tumor may spread to bone, or skin. Overall incidence of metastasis have been identified in fewer than 15% of cases<sup>23-25</sup>.

In<sup>26</sup> author, presented a case of carcinoid in a 39-year old man with persistent wheezing, episodes of haemoptysis and dry cough who was misdiagnosed as bronchial asthma and was treated with inhaled beta2-agonists and steroids for about 10 months without cure<sup>26</sup>. In<sup>27</sup> author presented a case report of bronchial carcinoid in a 28 year old man who was misdiagnosed as bronchial asthma. Our patient had right lower limb tibial fracture due to road traffic accident and his CXR was done as a screening investigation. Based on the incidental findings on his CXR (Figure 1.), he was initially considered to have a post tuberculous destroyed lung. As he had no past history of tuberculosis he was further evaluated with CECT on which the endobronchial growth was detected. The above cases suggests that absence of characteristic symptoms may lead to misdiagnosis and delay in diagnosis of intrabronchial carcinoid. Thus patients with respiratory symptoms inspite of optimum medical treatment should undergo radiological, brochosopical and pathological investigations for accurate and early diagnosis.

### 3.3 Histology

The first classification of neuroendocrine malignancies was proposed in 1972, which defined Atypical Carcinoid according to histologic criteria, including the number of mitoses per high-power field, the presence of necrosis, increased cellularity with disorganization, nuclear pleomorphism, hyperchromatism, and an abnormal nuclear-to-cytoplasmic ratio<sup>28,29</sup>. In 1991, In<sup>30</sup> author proposed 4 categories of neuroendocrine lung tumors: Typical Carcinoid, Atypical Carcinoid, Large Cell Neuroendocrine Carcinoma (LCNEC), and Small Cell Neuroendocrine Carcinoma (SCNEC) which was also supported by World Health Organization in 2004 and 2015<sup>31,32</sup>.

The World Health Organisation/The International Association for the Study of Lung Cancer (WHO/IASLC)

classifies Carcinoids according to histological differentiation<sup>32,33</sup>

- Typical Carcinoid (<2 mitoses/2 mm<sup>2</sup> and no necroses).
- Atypical Carcinoid (2–10 mitoses/2 mm<sup>2</sup> and/or confirmed necroses).

### 3.4 Serum Markers

The diagnostic test of choice for suspected carcinoid tumor is the measurement of urinary levels of the major serotonin metabolite 5-HIAA in a 24-hour urine sample (normal range 2-8 mg/24 hours). Approximately 50% of patients with carcinoids have elevated levels of urinary 5-HIAA, whether or not they have carcinoid syndrome<sup>4</sup>. An elevated urinary 5-HIAA level has a diagnostic sensitivity of 70% and a specificity of 88% to 100%.

Chromogranin A (CGA), is a 49-kD protein, another tumor marker present in the neurosecretory vesicles of neuroendocrine tumor cells. It is detectable in the plasma of patients with endocrine neoplasms. Because it does not rely on serotonin secretion, serum CGA is a more sensitive and broadly applicable marker than urinary 5-HIAA<sup>34,35</sup>. Serum CGA levels is measured in patients with metastatic small bowel and appendiceal carcinoid tumors, and also bronchial and rectal carcinoid tumors in whom urinary 5-HIAA levels are less likely to be elevated<sup>34,35</sup>.

### 3.5 Radiology

Bronchial carcinoids are visualised on chest radiographs or Computed Tomography (CT). Bronchial Typical and Atypical Carcinoids have similar radiologic features, which depend largely on tumor location. About 80% of bronchial carcinoids arise centrally in the main, lobar and segmental bronchi<sup>36</sup>. Radiological findings include hilar or perihilar masses, endobronchial nodules, findings related to bronchial obstruction, and peripheral nodules<sup>37</sup>. Hilar or perihilar masses are usually well-defined, round or ovoid lesions and may be slightly lobulated at radiography and CT. The tumors range from 2 to 5 cm in size<sup>37</sup>. In approximately 20% of cases, a bronchial carcinoid presents as a solitary pulmonary nodule in the lung periphery, distal to segmental bronchus. These lesions are usually round or ovoid with smooth or lobulated borders. Typical Carcinoids in the periphery are slow growing and should be considered in the differential diagnosis of slow-growing solitary pulmonary nodules<sup>36,38</sup>. Atypical Carcinoids mostly occur in the lung periphery and are

usually large<sup>38,39</sup>. Carcinoids are characteristically highly vascular. All carcinoids does not show enhancement and enhancement alone cannot differentiate bronchial carcinoid from bronchogenic carcinoma or does not excludes the diagnosis.

CT using contrast medium is the best method for identifying extrabronchial extends of tissue and mediastinal lymph node enlargement in central tumors. Because of their hypervascularization, carcinoid tumors absorb contrast medium and are often seen as well defined, obstructing tumors<sup>40</sup> Up to 20% of Typical Carcinoids are accompanied by hilar or mediastinal lymphadenopathy, which is mostly caused by a reactive inflammatory reaction<sup>41</sup>. Endobronchial ultrasound guided Transbronchial Needle Aspiration (EPBUS-TBNA) or mediastinoscopy undertaken for the purpose of staging according to the TNM classification for lung cancer<sup>42</sup>. The histological differentiation grade follows the classification of WHO/IASLC<sup>33</sup>. Typical Carcinoids are mostly diagnosed at stage I, Atypical Carcinoids mostly at stage II (N1, [hilar] lymph node involvement) or stage III (N2, [mediastinal] lymph node involvement). Hepatic metastases (stage IV) can be detected by using three-phase CT or, alternatively, by using ultrasonography.

### 3.6 Bronchoscopy

Fiberoptic Bronchoscopy is the best method of choice for tissue diagnosis. About three-fourths of bronchial carcinoids are centrally located and approachable to biopsy during bronchoscopy. The bronchoscopic appearance is a typically pink to red vascular mass with intact overlying bronchial epithelium. Carcinoids are generally attached to the bronchus by a broad base but can be polypoid and create a ball-valve effect<sup>14</sup>.

Bronchial carcinoids are vascular, and there has been concern for bleeding in the past, particularly after flexible bronchoscopy with biopsy. In spite of vascular nature, the incidence of serious bleeding complications during bronchoscopic biopsy is very low (<1%)<sup>43</sup>. The administration of a diluted epinephrine solution before and after biopsy of a suspected endobronchial carcinoid may have reduced the risk of severe bleeding<sup>44</sup>.

## 3.7 Treatment

### 3.7.1 Surgery

All pulmonary carcinoid tumors should be treated as malignancies. Surgery is the only curative approach, and,

in view of lack of prospective studies, it is the therapeutic mode of choice in all recommendations<sup>45,46</sup>. As it is with any other tumor, the most important objective is a microscopically tumor-free resection margin. Following resection of the tumor, 5-year survival rate of 94% was observed in 1109 patients with Typical Carcinoids by The European Society of Thoracic Surgeons Euroendocrine Tumors Working Group<sup>42,45</sup> and 3 year survival rate of 67% was observed in the United States by a database analysis of 441 patients with AC<sup>47</sup>. Another retrospective analysis of 84 patients conducted by<sup>43</sup> showed a 5 year survival rate of 91% in patients with Typical Carcinoids and 90% in patients with Atypical Carcinoids<sup>43</sup>. It is recommended that patients having AC should undergo radical lymphnode resection due to expected high chances of metastases to adjacent lymphnodes. However, patients with Typical Carcinoids are also advised draining lymphnode resection or biopsy since chances of metastasis is present<sup>47</sup>.

Lung saving surgeries are preferred. Patients having peripheral tumors can be considered for wedge resection or lobectomy<sup>48</sup>. Certain central tumors need sleeve excision with angioplasty and bronchoplasty, thus further reducing both morbidity and mortality<sup>48</sup>. Endoscopic resection of endobronchial tumors and endoscopic laser resection can be performed in selected cases. In<sup>49</sup>, used bronchoscopic laser therapy for endobronchial TC in 11 patients, out of which 6 patients were proven disease free following surgical resection. Rigid bronchoscope is preferred, as it allows multiple uses of instruments at a time and gives good ventilatory support. Most pulmonologists prefer flexible bronchoscope for laser photoresection<sup>50</sup>.

### 3.7.2 Treatment of Unresectable Tumors

Various chemotherapy agents have been tried. Somatostatin receptor Analogues (SSA) such as octreotide and lanreotide, which are primarily used for controlling symptoms in carcinoid syndrome, are used along with mTOR inhibitor everolimus (RADIAN T-2 Study) to increase survival rate to 16.4 months from 11.3 months as compared to placebo<sup>51-53</sup>. The phase II study of Peptide Receptor Radionuclide Therapy (PRRT) using radioactively marked 90Yttrium (Y) or 177Lutetium (Lu)-SSA (e1) has shown response to treatment in patients with somatostatin refractory tumors<sup>54</sup>. A pilot study is been conducted for somatostatin receptor ligand 177Lu-DOTATATE<sup>55</sup>.

Carcinoids are radio resistant, however local lymphnode radiation in atypical carcinoids and unresectable

tumors is being considered as a palliative therapy. Inoperable tumors can be resected bronchoscopically as a palliative approach to relieve obstruction and associated collapse-consolidation. Local resection of metastatic lesion in liver has a 5 year mean survival rate of 78 %<sup>15</sup>.

## 4. Summary

Carcinoid tumors are malignant neuroendocrine neoplasms arising from Enterochromaffin (EC) cells. Clinical serological as well as radiological studies are unable to differentiate pulmonary neoplasm from bronchial carcinoid. Bronchoscopic needle aspiration or biopsy of carcinoid followed by histological study is the best modality for tissue diagnosis. The survival of patients with carcinoid tumor depends basically on the histologic type and the presence of distant metastasis. Typical bronchial carcinoids rarely metastasize and have an excellent prognosis even when regional lymph nodes are involved; Atypical Carcinoids have a higher likelihood of metastases and a worse prognosis, particularly if mediastinal nodes are involved. Surgical resection is the treatment of choice with good long term survival rate. To avoid misdiagnosis or delay in the diagnosis of intrabronchial carcinoid, the patients with refractory respiratory symptoms inspite of optimum medical treatment should undergo clinical, radiological, brochoscopical and histopathological investigations for accurate and early diagnosis.

## 5. References

1. Lips CJ, Lentjes EG, Hoppener JW. The spectrum of carcinoid tumours and carcinoid syndromes. *Ann Clin Biochem.* 2003; 40(Pt 6):612–27.
2. Chong S, Lee KS, Chung MJ. Neuroendocrine tumors of the lung: Clinical, pathologic, and imaging findings. *Radiographics.* 2006 Jan-Feb. 26(1):41–57; 57–8.
3. Lubarsh O. Uber den pimaeren krebs des ileum nebst Bemerkungen ueber das gleichzeitige Vorkommen von krebs und Tuberculos. *Virchows Arch.* 1888; 11:280–317.
4. Raut CP, Kulke MH, Glickman JN, Swanson RS, Ashley SW. Carcinoid tumors. *Curr Probl Surg.* 2006; 43:391–450.
5. Gosset A, Masson P. Tumeurs endocrines de l'appendice. *Presse Med.* 1914; 25:237–9.
6. Hamperl H. Uber gutartige bronchialtumoren (cylindrome und carcinoide). *Virchows Arch.* 1937; 300:46–88.
7. Cortez LL, Clemente C, Puig V, Mirada A. Carcinoid tumor. An analysis of 131 cases. *Rev Clin Esp.* 1994; 194(4):291–3.
8. Modlin IM, Sandor A. An analysis of 8305 cases of carcinoid tumors. *Cancer.* 1997; 79(4):813–29.
9. Newton JN, Swerdlow AJ, dos Santos Silva IM, et al. The epidemiology of carcinoid tumours in England and Scotland. *Br J Cancer.* 1994; 70(5):939–42.
10. Soga J. Carcinoids of the rectum: An evaluation of 1271 reported cases. *Surg Today.* 1997; 27(2):112–9.
11. Soga J. Carcinoids of the small intestine: A statistical evaluation of 1102 cases collected from the literature. *J Exp Clin Cancer Res.* 1997; 16(4):353–63.
12. Woods HF, Bax ND, Ainsworth I. Abdominal carcinoid tumours in Sheffield. *Digestion.* 1990; 45(S1):17–22.
13. Modlin IM, Lye KD, Kidd M. A 5-decade analysis of 13,715 carcinoid tumors. *Cancer.* 2003; 97(4):934–59.
14. Warren WH, Gould VE. Long-term follow-up of classical bronchial carcinoid tumors. *Clinicopathologic observations.* *Scand J Thorac Cardiovasc Surg.* 1990; 24(2):125–30.
15. Watzka FM, Fottner C, Miederer M, et al. Surgical therapy of neuroendocrine neoplasm with hepatic metastasis: Patient selection and prognosis. *Langenbecks Arch Surg.* 2015; 400(3):349–58.
16. Harpole DH, Feldman JM, Buchanan S. Bronchial carcinoid tumors: A retrospective analysis of 126 patients. *The Annals of thoracic surgery.* 1992; 54(1):50–4.
17. Fink G, Krelbaum T, Yellin A, et al. Pulmonary carcinoid: Presentation, diagnosis, and outcome in 142 cases in Israel and review of 640 cases from the literature. *Chest.* 2001; 119(6):1647–51.
18. Oliveira AM, Tazelaar HD, Wentzlaff KA, et al. Familial pulmonary carcinoid tumors. *Cancer.* 2001; 91(11):2104–9.
19. Zuetenhorst JM, Taal BG. Metastatic carcinoid tumours: A clinical review. *Oncologist.* 2005; 10:123–31.
20. Limper AH, Carpenter PC, Scheithauer B, Staats BA. The Cushing syndrome induced by bronchial carcinoid tumors. *Ann Intern Med.* 1992; 117(3):209–14.
21. Wajchenberg BL, Mendonca BB, Liberman B, et al. Ectopic adrenocorticotrophic hormone syndrome. *Endocr Rev.* 1994; 15:752–87.
22. Carroll DG, Delahunt JW, Teague CA, et al. Resolution of acromegaly after removal of a bronchial carcinoid shown to secrete growth hormone releasing factor. *Aust N Z J Med.* 1987; 17(1):63–7.
23. Okike N, Bernatz PE, Payne WS, et al. Bronchoplastic procedures in the treatment of carcinoid tumors of the tracheobronchial tree. *J Thorac Cardiovasc Surg.* 1978; 76(3):281–91.

24. Kulke MH, Mayer RJ. Carcinoid tumors. *N Engl J Med*. 1999; 340:858–68.
25. Torre M, Barberis M, Barbieri B, et al. Typical and atypical bronchial carcinoids. *Respir Med*. 1989; 83:305–8.
26. Emeryk J, Czekajaska-Chehab E, Korobowicz E, Korbel M, Wegrzyn-Szkutnik I, Milanowski J. Bronchial carcinoid in a 39-year-old man treated for bronchial asthma: A case report. *Cases Journal*. 2008; 2:7414. DOI:10.1186/1757-1626-2-7414.
27. Kumari A, Sharma P, Tikku G, Malhotra K. Primary endo-bronchial carcinoid tumour: Case report and review of literature. *Clinical Medicine Journal*. 2015; 1(2):43–7.
28. Travis WD, Rush W, Flieder DB, et al. Survival analysis of 200 pulmonary neuroendocrine tumors with clarification of criteria for atypical carcinoid and its separation from typical carcinoid. *Am J Surg Pathol*. 1998; 22(8):934–44.
29. Arrigoni MG, Woolner LB, Bernatz PE. A typical carcinoid tumors of the lung. *J Thorac Cardiovasc Surg*. 1972; 64:413–21.
30. Travis WD, Linnoila RI, Tsokos MG, et al. Neuroendocrine tumors of the lung with proposed criteria for large cell neuroendocrine carcinoma. An ultrastructural, immunohistochemical, and flow cytometric study of 35 cases. *Am J Surg Pathol*. 1991; 15:529–53.
31. Beasley MB, Brambilla E, Travis WD. The 2004 World Health Organization classification of lung tumors. *Semin Roentgenol*. 2005; 40(2):90–7.
32. Travis WD, Brambilla E, Burke AP, Marx A, Nicholson AG, editors. WHO classification of tumours of the lung, pleura, thymus and heart. World Health Organization Classification of Tumors. 4th ed. Geneva, Switzerland: WHO Press; 2015. p. 9–97.
33. Lim E, Goldstraw P, Nicholson AG, et al. Proceedings of the IASLC international workshop on advances in pulmonary neuroendocrine tumors 2007. *J Thorac Oncol*. 2008; 3:1194–201.
34. Eriksson B, Oberg K, Stridsberg M. Tumor markers in neuroendocrine tumors. *Digestion*. 2000; 62(S1):33–8.
35. Janson ET, Holmberg L, Stridsberg M, et al. Carcinoid tumors: Analysis of prognostic factors and survival in 301 patients from a referral center. *Ann Oncol*. 1997; 8(7):685–90.
36. Nessi R, Ricci PB, Ricci SB, Bosco M, Blanc M, Uslenghi C, et al. Bronchial carcinoid tumors: Radiologic observations in 49 cases. *J Thorac Imaging*. 1991; 6(2):47–53.
37. Jeung MY, Gasser B, Gangi A, Charneau D, Ducrog X, Kessler R, et al. Bronchial carcinoid tumors of the thorax: Spectrum of radiologic findings. *Radiographics*. 2002; 22(2):351–65.
38. Magid D, Siegelman SS, Eggleston JC, Fishman EK, Zerhouni EA. Pulmonary carcinoid tumors: CT assessment. *J Comput Assist Tomogr*. 1989; 13(2):244–7.
39. Choplin RH, Kawamoto EH, Dyer RB, Geisinger KR, Mills SE, Pope TL. Atypical carcinoid of the lung: Radiographic features. *AJR Am J Roentgenol*. 1986; 146:665–8.
40. Granberg D, Sundin A, Janson ET, Oberg K, Skogseid B, Westlin JE. Octreoscan in patients with bronchial carcinoid tumours. *Clin Endocrinol (Oxf)*. 2003; 59(6):793–9.
41. JCC cancer staging manual. 7th ed. New York City: Springer; 2011. p. 251–3.
42. Filosso PL, Guerrera F, Evangelista A, et al. Prognostic model of survival for typical bronchial carcinoid tumours: Analysis of 1109 patients on behalf of the European Society of Thoracic Surgeons (ESTS) neuroendocrine tumours working group. *Eur J Cardiothorac Surg*. 2015; epub ahead of print.
43. Kaifi JT, Kayser G, Ruf J, Passlick B. The diagnosis and treatment of bronchopulmonary carcinoid. *Dtsch Arztebl Int*. 2015; 112(27-28):479–8.
44. Fuks L, Fruchter O, Amital A, Fox BD, Abdel Rahman N, Kramer MR. Long-term follow-up of flexible bronchoscopic treatment for bronchial carcinoids with curative intent. *Diagnostic and Therapeutic Endoscopy*. 2009; 2009. Available from: <http://dx.doi.org/10.1155/2009/782961>
45. Caplin ME, Baudin E, Ferolla P, et al. Pulmonary neuroendocrine (carcinoid) tumors: European neuroendocrine tumor society expert consensus and recommendations for best practice for typical and atypical pulmonary carcinoid. *Ann Oncol*. 2015; epub ahead of print.
46. Horsch D, Schmid KW, Anlauf M, et al. Neuroendocrine tumors of the bronchopulmonary system (typical and atypical carcinoid tumors): Current strategies in diagnosis and treatment. Conclusions of an expert meeting February 2011 in Weimar, Germany. *Oncol Res Treat*. 2014; 37(5):266–76.
47. Steuer CE, Behera M, Kim S, et al. Atypical carcinoid tumor of the lung: A surveillance, epidemiology, and end results database analysis. *J Thorac Oncol*. 2015; 10(3):479–85.
48. Bolukbas S, Schirren J. Parenchyma-sparing bronchial sleeve resections in trauma, benign and malignant diseases. *Thorac Cardiovasc Surg*. 2010; 58(1):32–7.
49. Stuteja TG, Vanderschueren RJ, Werf TS. Bronchoscopic therapy in patients with intraluminal typical bronchial carcinoid. *Chest*. 1995; 107(2):556–8.
50. AVECILLAS JF, MEHTA AC. Flexible bronchoscopy and the use of lasers. In: Wang KP, Mehta AC, Turner JF, editors. *Flexible Bronchoscopy*. 2nd ed. Massachusetts: Blackwell Publishing; 2005. p. 157–73.

51. Narayanan S, Kunz PL. Role of somatostatin analogues in the treatment of neuroendocrine tumors. *J Natl Compr Canc Netw*. 2015;13(1):109–17.
52. Caplin ME, Pavel M, Cwikla JB, et al. Lanreotide in metastatic enteropancreatic neuroendocrine tumors. *N Engl J Med*. 2014; 371:224–33.
53. Pavel ME, Hainsworth JD, Baudin E, et al. Everolimus plus octreotide long-acting repeatable for the treatment of advanced neuroendocrine tumours associated with carcinoid syndrome (RADIANT-2): A randomised, placebo-controlled, phase 3 study. *Lancet*. 2011; 378(9808):2005–12.
54. Bushnell DL, Jr O'Dorisio TM, O'Dorisio MS, et al. 90Y-edotreotide for metastatic carcinoid refractory to octreotide. *J Clin Oncol*. 2010; 28(10):1652–9.
55. Van Essen M, Krenning EP, De Jong M, Valkema R, Kwekkeboom DJ. Peptide receptor radionuclide therapy with radiolabelled somatostatin analogues in patients with somatostatin receptor positive tumours. *Acta Oncol*. 2007; 46(6):723–4.