

Cytological Profile of Thyroid Lesions and its Correlation with Clinical and Ultrasonography Findings

Ujwala S. Chavan^{1*}, Archana Patil² and Suresh V. Mahajan³

¹Resident, Dr. Vasanttrao Pawar Medical College, Hospital and Research Centre, Vasantdada Nagar, Adgaon, Nashik – 422003, India; ujwalachavan.doc@gmail.com

²Associate Professor, Dr. Vasanttrao Pawar Medical College, Hospital and Research Centre, Vasantdada Nagar, Adgaon, Nashik - 422003, India

³Professor, Department of Pathology, Dr. Vasanttrao Pawar Medical College, Hospital and Research Centre, Adgaon, Nashik - 422003, Maharashtra, India

Abstract

Background: Thyroid gland is the first endocrine gland to develop, largest of all endocrine glands. Superficial location of thyroid gland allows evaluation of thyroid lesions by FNAC (fine needle aspiration cytology). **Aims and Objective:** To study cytological profile of thyroid lesions and correlate the results with Ultrasonography findings and clinical features. **Material and Methods:** This prospective study was carried out on 138 patients who came to the department from period of May 2012 to December 2014. Out of these 138 patients USG was carried out in 115 patients. FNAC of patients was performed and results of FNAC were correlated with those of USG reports and clinical features of the patient. **Results:** Out of 138 cases 83 (60.1%) cases were benign, 18(13.0%) cases were inflammatory, 2 (1.4%) cases were malignant, 28 (20.3%) were categorised as indeterminate, and 7 (5.1%) cases were inadequate. All the 2 malignant cases were given as neoplastic on USG. **Conclusion:** FNAC is the main diagnostic modality of choice for thyroid lesions, along with Ultrasonography and clinical examination it helps to come to the proper diagnosis.

Keywords: FNAC, USG

1. Introduction

The thyroid gland is unique among endocrine glands, being the first endocrine gland to appear in the fetus. It is the largest of all endocrine glands (weighing about 25 gm.) and is the only one which is amenable to direct physical examination because of its superficial location.¹

FNAC of thyroid can be used as a diagnostic test or triage tool. As diagnostic test, it can differentiate between benign and malignant tumour, as a triage tool it can be used to distinguish nodule that might have a higher risk of malignancy (i.e. neoplasm) and thus require surgical

excision, which is differentiated from nodular goitre or thyroiditis, which can be managed medically.²

FNAC is minimally invasive, cost effective procedure with low complications³⁻⁵. FNAC is considered as first line investigation in the diagnosis of thyroid lesions⁶. Sensitivity and specificity of FNAC is upto 94% and 98% for diagnosis of malignant lesions and nearly 90% accuracy rate in the identification of malignancy, excluding follicular lesion⁷. The Ultrasonography is easily accessible, inexpensive, highly sensitive diagnostic modality.⁸

The present study is undertaken to evaluate the thyroid lesion by using Fine Needle Aspiration Cytology

*Author for correspondence

(FNAC) in conjunction with Ultrasonography and clinical features.

2. Material and Methods

This prospective study was carried out on 138 patients who attended the OPD or IPD of Dr. Vasant Rao Pawar Medical College, Nashik, Maharashtra, from May 2012 to December 2014. FNAC was carried out on 138 patients with thyroid swelling attending OPD, smears were prepared, stained with haematoxylin & eosin stain and these findings were recorded. Cytology findings were correlated with clinical features and out of 138 cases 115 cases underwent Ultrasonography examination so correlation was done in these 115 cases.

2.1 Patient selection

It was based on following criteria:

- Patients undergoing FNAC for palpable thyroid lesions
- Age of patient should be more than 18 years.

Exclusion criteria:

- Uncooperative patients, not willing for FNAC.

3. Results

Out of 138 cases 83 (60.1%) cases were benign, 18(13.0%) cases were inflammatory, 2 (1.4%) cases were malignant, 28 (20.3%) were categorised as indeterminate, and 7 (5.1%) cases were inadequate on FNAC. All the malignant cases were given as neoplastic on USG.

4. Discussion

4.1 Age Distribution

In the present study maximum number of cases was between 28 to 37 years of age, followed by 38 to 47 years of age. Youngest patient in the study was 18 years old and eldest was 72 years old. The median age was 40 years. In the similar study by Afroz N et al.⁹, the age range was 16 to 78 years with median age was 40.2 years. In a study by Manoj Gupta et al.¹⁰ and Sinna E et al.¹¹ median age was 38.72 years and 44 years respectively.

Table 1. Showing age distribution of case

Age (years)	No.	Percentage
18 to 27	27	19.6%
28 to 37	39	28.3%
38 to 47	36	26.1%
48 to 57	18	13.0%
58 to 67	11	8.0%
68 to 77	7	5.1%
Total	138	100.0%

Table 2. Showing clinical symptomatology

Sr. No.	Clinical Symptoms	Patients	Percentage
1.	Swelling in front of neck	138	100%
2.	Dyspnea	3	2.2%
3.	Pain	4	2.9%
4.	Dysphagia	16	11.6%
5.	Hoarseness of voice	6	4.3%

Table 3. Showing appearance of swelling on examination

Appearance	No.	Percentage
Diffuse enlargement	58	42.0%
Solitary nodule	45	32.6%
One lobe enlargement	35	25.4%
Total	138	100.0%

Table 4. Showing distribution of cases depending on FNAC diagnosis

	FNAC diagnosis	No.	Percentage
Benign	Colloid goiter	62	44.9%
	Colloid cyst	11	8.0%
	Thyroglossal cyst	5	3.6%
	Multinodular goiter	3	2.2%
	Graves Disease	1	0.7%
	Hyperplastic thyroid	1	0.7%
Indeterminate	Follicular Neoplasm	16	11.6%
	Follicular Lesion	12	8.7%
Inflammatory	Lymphocytic thyroiditis	15	10.9%
	Granulomatous Thyroiditis	3	2.2%
	Papillary carcinoma	2	1.4%
Inadequate	Inadequate	7	5.1%
	Total	138	100.0%

4.2 Gender Distribution

In the present study, 82% patients were females and 28% were male. The male to female ratio was 1:6.26. So, females were commonly affected than males. In a study by Uma Handa et al. Male to female ratio was 1: 6.35¹². In a study by Sarunya kantasueb et al.¹³ and Paarthipan N et al.¹⁴ male to female ration was 1:5.12 and 1:4 respectively.

4.3 Clinical Presentation

All the 138 patients presented with swelling in front of neck, pressure effect from thyroid swelling was seen in 3 (2.2%)

Table 5. Showing distribution of cases depending on USG diagnosis

	USG diagnosis	No.	Percentage
Benign	Multinodular goiter	32	27.8%
	Colloid goiter	27	23.5%
	Colloid Cyst	18	15.7%
	Follicular Adenoma	7	6.1%
	Thyroglossal cyst	5	4.3%
	Nodular Thyroid	1	0.9%
	Graves Disease	1	0.9%
Inflammatory	Thyroiditis	12	10.4%
Neoplasm	Neoplastic etiology	9	7.8%
Other	Isoechoic lesion	1	0.9%
	Bulky Thyroid	2	1.7%
	Total	115	100.0%

cases presented with dyspnea, 4 (2.9%) cases with pain in swelling, dysphagia seen in 16 (11.6%) cases and hoarseness of voice in 6 (4.3%) cases. Clinically 58 (42%) cases presented with diffuse swelling of thyroid, solitary nodule was present in 45 (32%) cases and 35 (25.4%) cases presented with enlargement of one lobe. In a study by Ankush Dhanadia et al.⁸, swelling in front of neck was seen in 100 (100%) cases, pressure symptom was seen in 13 (13%) cases and pain in the swelling was seen in 15 (15%) cases.

The swelling was moving with deglutition in 133 (96.4%) cases and in 5 (3.6%) cases swelling was not moving with deglutition but moving with protrusion of tongue. These 5 (3.6%) cases were diagnosed as thyroglossal cyst on FNAC and Ultrasonography as well.

In majority of cases, that is 119 (86.2%) swelling was firm in consistency on palpation and 6 (4.3%) cases were cystic.

Lymph nodes were palpable in 6 (4.3%) cases.

4.4 Ultrasonography was done in 115 ases and Findings were noted

Ultrasonography examination was done in 115 cases out of total 138 cases. Out of these 115 cases, 91(79.1%) cases were diagnosed as benign. Multinodular goiter 32 (27.8%) being the most common, followed by colloid goiter 27 (23.5%). There were 18 (15.7%) cases of colloid cyst, 7 (6.1%) cases of follicular adenoma, 5 (4.3%) cases of thyroglossal cyst and 1 case of graves disease and nod-

Table 6. Showing association of FNAC categories and USG categories of lesion

FNAC categories of lesion		USG Categories of Lesion				Total
		Benign	Inflammatory	Neoplasm	Other	
Benign	No.	71	2	1	2	76
	%	78.0%	16.7%	11.1%	66.7%	66.1%
Inflammatory	No.	4	8	0	0	12
	%	4.4%	66.7%	0.0%	0.0%	10.4%
Malignant	No.	0	0	2	0	2
	%	0.0%	0.0%	22.2%	0.0%	1.7%
Indeterminate	No.	14	1	5	1	21
	%	15.4%	8.3%	55.6%	33.3%	18.3%
Inadequate	No.	2	1	1	0	4
	%	2.2%	8.3%	11.1%	0.0%	3.5%
Total	No.	91	12	9	3	115
	%	100.0%	100.0%	100.0%	100.0%	100.0%

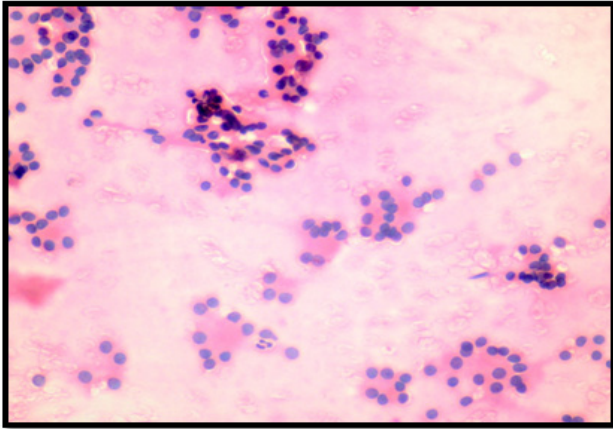


Figure 1. Showing microfollicular arrangement with nuclear crowding and overlapping in case of follicular neoplasm. (H & E x 400)

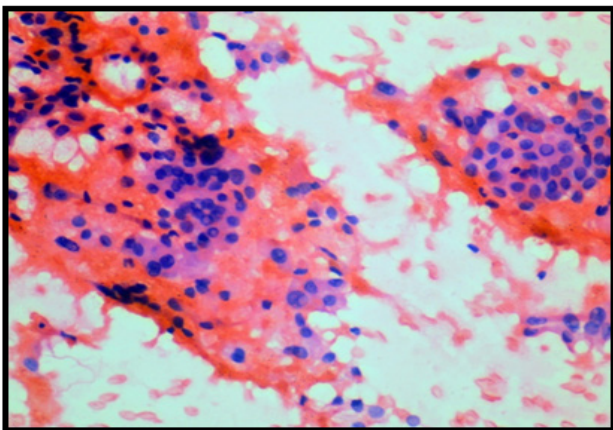


Figure 2. Showing aggregate of cells against haemorrhagic background. Cells showing enlarged oval nuclei with nuclear grooves and intranuclear cytoplasmic inclusion in case of papillary carcinoma. (H & E x 400)

ular thyroid each. The nodular thyroid was described as features having benign thyroid nodule.

In inflammatory cases 12 (10.4%) cases were thyroiditis on Ultrasonography. Neoplastic etiology was found in 9 (7.8%) cases, and 3 (2.6%) were categorized as others, out of which 2 (1.7%) cases were showing features of bulky thyroid and, 1 (0.9%) case showed isoechoic lesion.

In a study by kaur k et al.¹⁵ USG findings were benign cases were 38 (76%), malignant cases were 5 (10%) and indeterminate cases were 7 (14%).

4.5 FNAC was done in 138 Cases and Cytology Findings were noted

- Majority, that is 83 (60.1%) cases were diagnosed as benign which included the following lesions: 62 (44.9%) cases of colloid goiter, which was the most common of these benign cases, colloid cyst 11 (8.0%) cases, 5 (3.6%) cases of thyroglossal cyst, 3 (2.2%) cases of multinodular goiter, 1 (0.7%) case of graves disease and hyperplastic thyroid each.
- Eighteen (13.0%) cases were diagnosed as inflammatory lesion which included lymphocytic thyroiditis (10.9%) cases followed by granulomatous thyroiditis 3 (2.2%) cases.
- Two (1.4%) cases of papillary carcinoma were seen in malignant category.
- Twenty eight (20.3%) were categorised as indeterminate. In this category, follicular neoplasm was seen in 16 (11.6%) cases and follicular lesion in 12 (8.7%) cases. Seven (5.1%) cases were inadequate.
- The statistically significant association was found between-
 - * FNAC categories of lesion and appearance of swelling.
 - * FNAC categories of lesions and consistency of swelling on examination.
 - * FNAC categories and USG categories of the lesions of thyroid.

In a study done by Likhar et al.⁶, benign cases were 221 (94.4%), malignant cases were 6 (2.6%), indeterminate cases were 3 (1.3%) and inadequate cases were 4 (1.7%). In a study by Safa Mezher Al-Obaidi et al.¹⁶ benign cases were 83 (64%), malignant cases were 13 (10%), 26 (20%) indeterminate cases were seen and 8 (6%) cases were inadequate.

Statistically significant correlation was found between cytological examination of thyroid lesions and USG examination in a study by Sehovic S et al.¹⁷

5. Conclusion

From our study we can conclude that the thyroid swelling was more common in females.

The commonest presenting complaint was swelling in front of neck.

On FNAC, benign category constituted the major cause of thyroid swelling. The commonest benign lesion was colloid goitre and the commonest malignant lesion was papillary carcinoma.

On USG also benign thyroid lesions were common and goiter constituted the majority of cases which were correlated with those of FNAC findings.

From our study we can conclude that for proper diagnosis of thyroid lesion, FNAC is the main diagnostic modality. Along with Ultrasonography and Clinical examination it helps to come to the proper diagnosis.

6. References

1. Fehrenbach MJ, Herring SW. Illustrated Anatomy of the Head and Neck. 4th ed. China: Elsevier; 2012. Chapter 7 Glandular tissue; p.152–65.
2. 10. G-Kocjan. Fine Needle Aspiration Cytology- Diagnostic principals and dilemmas. 1st edition, Springer; 2006. Chapter 10, Principles of Safe practice: the role of FNAC in clinical management; 213–23.
3. Sengupta A, Pal R, Kar S, Zaman FA, Sengupta S, PaL S. Fine needle aspiration cytology as the primary diagnostic tool in thyroid enlargement. *Journal of Natural Science, Biology and Medicine*. 2011 Jan; 2(1):113–18.
4. Bagga PK, Mahajan NC. Fine needle aspiration cytology of thyroid swellings: How useful and accurate is it? *Indian Journal of Cancer*; 2010 Oct–Dec; 47(4):437–42.
5. Parikh UR, Goswami HM, Shah AM, Mehta NP, Gonsai RN. Fine Needle Aspiration Cytology (FNAC) Study of Thyroid Lesion. *GMJ*. 2012 Aug; 67(2):25–30.
6. Likhar KS, Hazari RA, Gupta SG, Shukla U. Diagnostic accuracy of fine needle aspiration cytology in thyroid lesions: A hospital-based study. *Thyroid Research and Practice*; 2013 May-Aug; 10(2):68–71.
7. Orell RS, Jayram Gita . Thyroid. In: Orell RS, Sterrett FG, editors. *Fine Needle Aspiration Cytology*. 5th ed. Elsevier Missouri: Churchill Livingstone; 2012. p. 119–55.
8. Dhanadia A, Shah H, Dave A. Ultrasonographic and FNAC correlation of thyroid lesions. *GMJ*. 2014 Mar; 69(1):75–81.
9. Afroze N, Kayani N, Hasan SH. Role of fine needle aspiration cytology in the diagnosis of palpable thyroid lesions. *Indian J Pathol Microbiol*. 2002 Jul; 45(3):241–46.
10. Gupta M, Gupta S, Gupta VB. Correlation of Fine Needle Aspiration Cytology with Histopathology in the Diagnosis of Solitary Thyroid Nodule. *Journal of Thyroid Research*. 2010; 1–5.
11. Sinna EA, Ezzat N. Diagnostic accuracy of fine needle aspiration cytology in thyroid lesions. *Journal of the Egyptian National Cancer Institute*. 2012; 24:63–70.
12. Handa U, Garg S, Mohan H, Nagarkar N. Role of fine needle aspiration cytology in diagnosis and management of thyroid lesions: A study on 434 patients. *Journal of Cytology*. 2008 Jan; 25(1):13–7.
13. Kantasueb S, Sukpan K, Mahanupab P. The study of thyroid lesions and the correlation between histopathological and cytological findings at Maharaj Nakorn Chiang Mai Hospital Between 2003 and 2007. *Chiang Mai Med J*. 2010; 49(3):105–10.
14. Paarthipan N, Teli CG, Kate N, Jaiganesh S, Venkateswaran. A, Srinivas M. Role of high frequency ultrasound in evaluation of solitary thyroid nodule and comparison with fine needle aspiration cytology. *Int Bio Med Res*. 2012; 3(3):2158–62.
15. Kaur K, Sonkhya N, Bapna AS, Mital P. A Comparative study of fine needle aspiration cytology, ultrasonography and radionuclide scan in the management of solitary thyroid nodule: A Prospective analysis of fifty cases. *Indian Journal of Otolaryngology and Head and Neck Surgery*. 2002 Apr-Jun; 54(2):96–01.
16. AL-Obaidi SM, Abbas Zwain KM, Zaini HH. Comparative Study of Fine Needle Aspiration Cytology and Ultrasonography in the Management of Solitary Thyroid Nodule. *The Iraqi Post Graduate Medical Journal*. 2014; 5:68–73.
17. Sehovic S, Begic A, Juric N, Celam M. Comparison between Ultrasound, Scintigraphy and Cytological Puncture in Diagnostics of Thyroid Gland Nodules. *Med Arh*. 2013 Jun; 67(3):198–01.